

Case Study: 3M™ Clarity™ Aligners

Asymmetric Class III with mild upper and lower crowding

Age: 29

Chief concern: Front top teeth and bottom teeth rubbing together

Case diagnostics: Class I skeletal, asymmetrical Class III malocclusion with traumatic incisor occlusion and mild upper and lower crowding

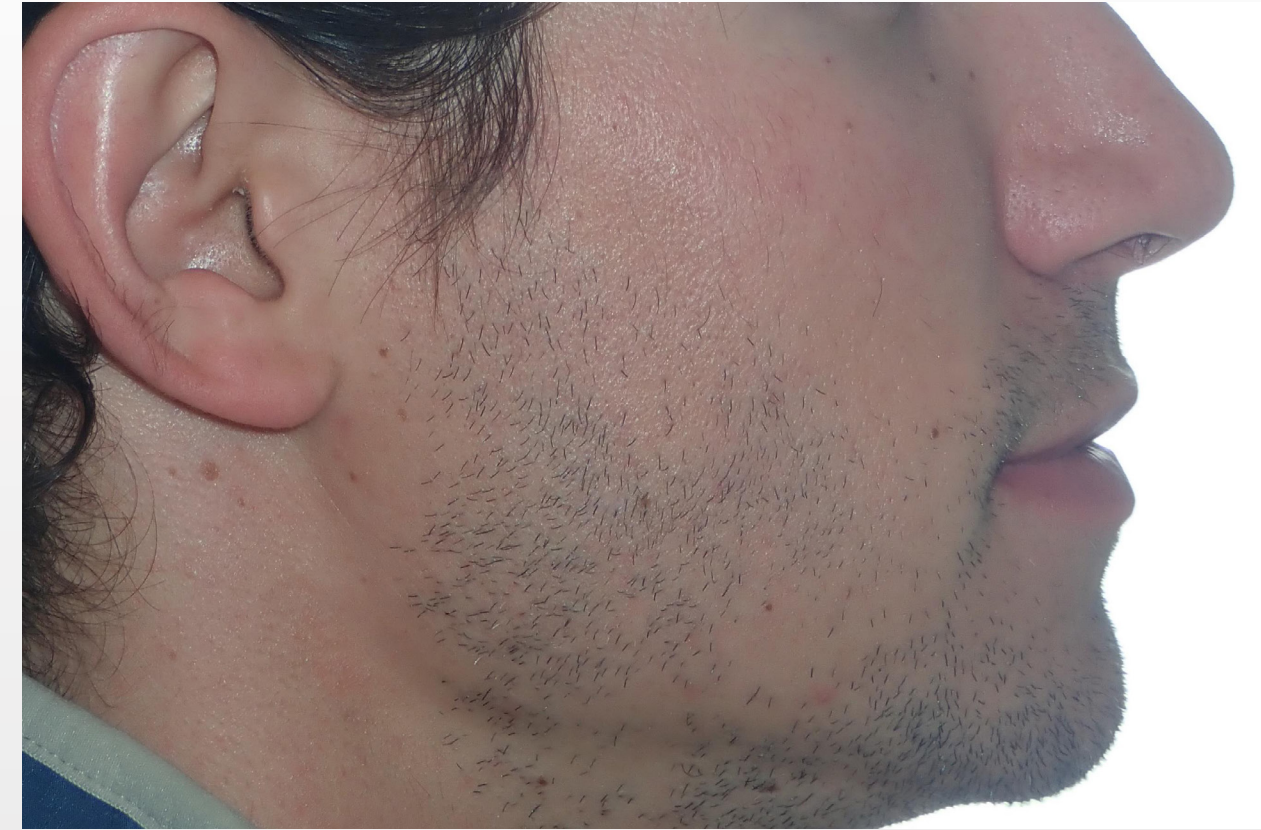Total number of aligners: 47 total aligners (11 aligners in Initial Tx Design), (16 aligners in Refinement 1), (12 aligners in Refinement 2), (8 aligners in Refinement 3)

Wear interval: 2 week changes for stages 1-2. Weekly changes with attachment placement at the beginning of stage 3

Treatment time: 25 months (includes 19 weeks “logistics” wait time and a two month delay due to COVID-19 pandemic office closure)

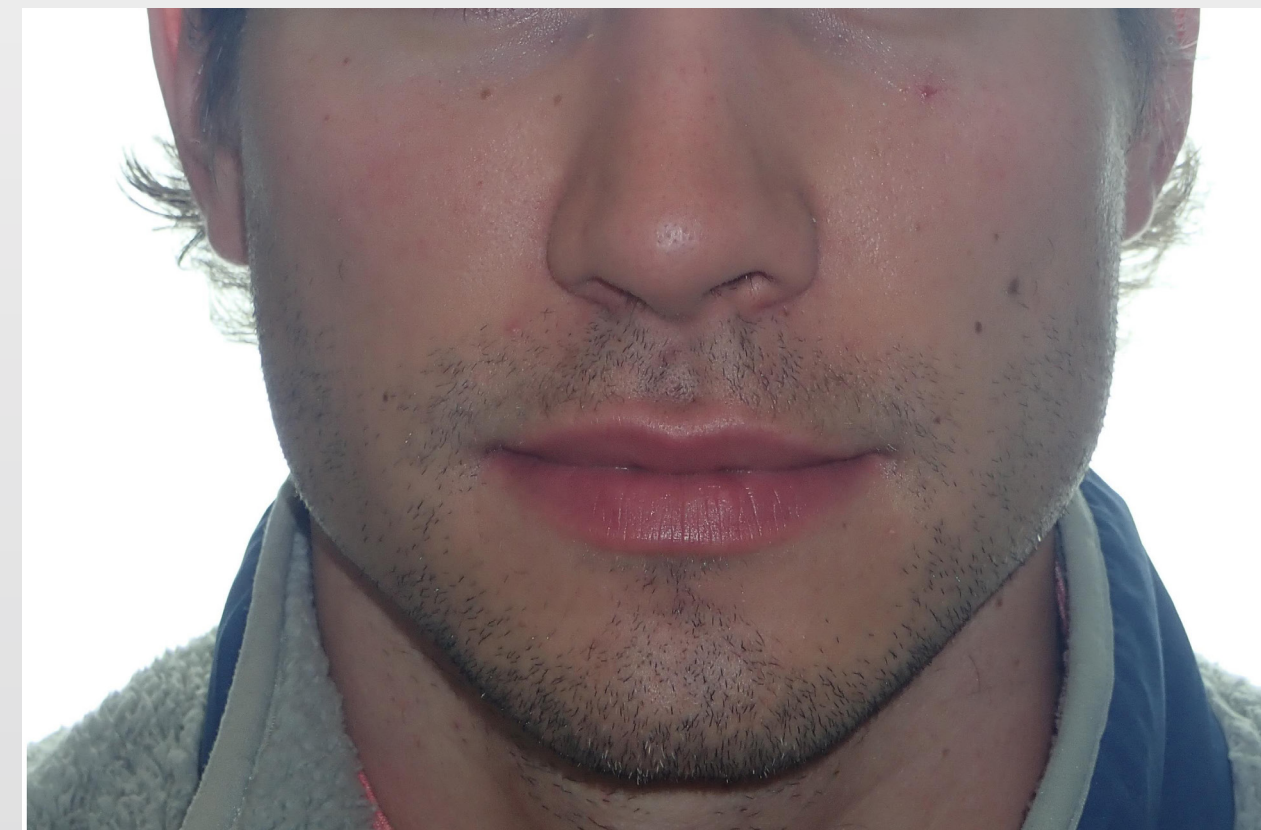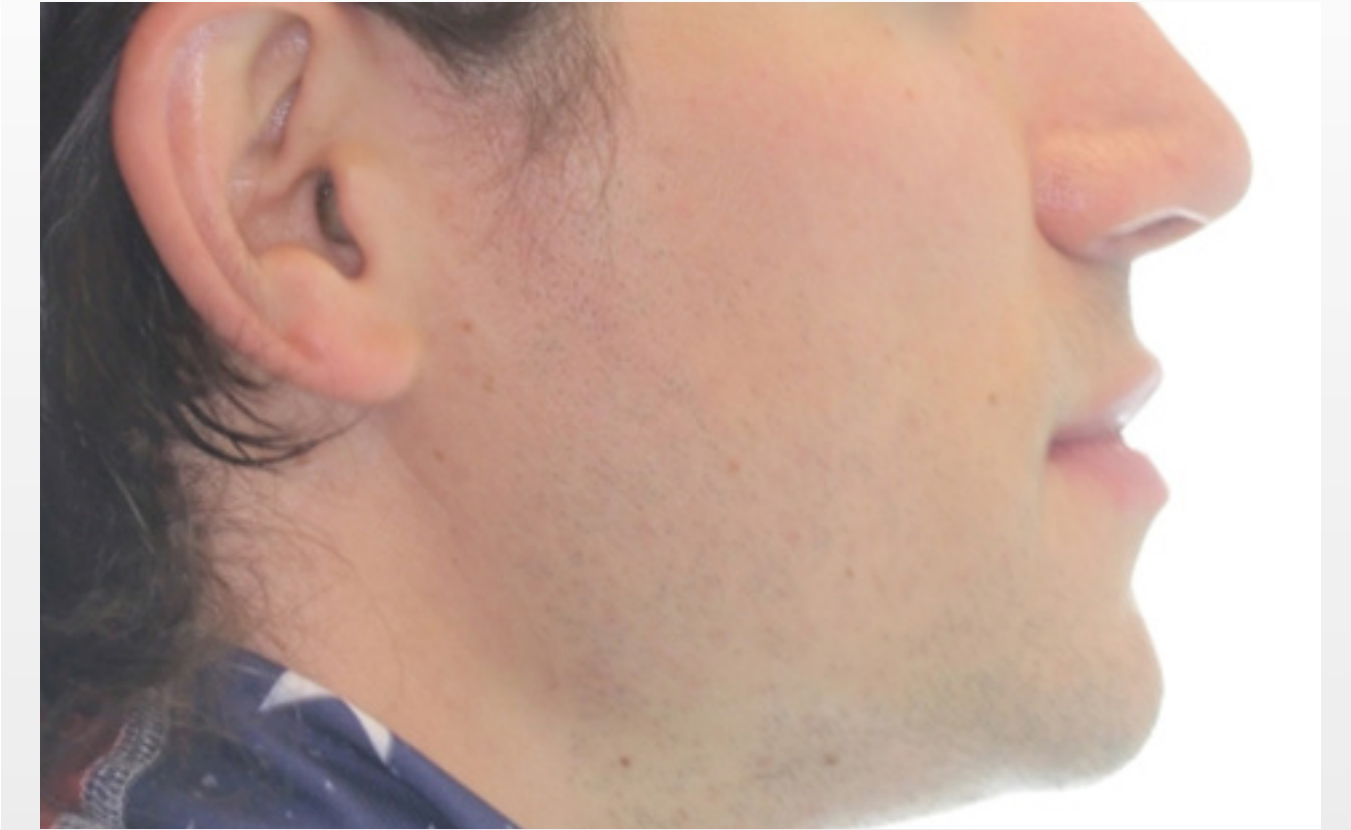Case courtesy of:
Dr. David Hime
Austin, TX – USA

Initial

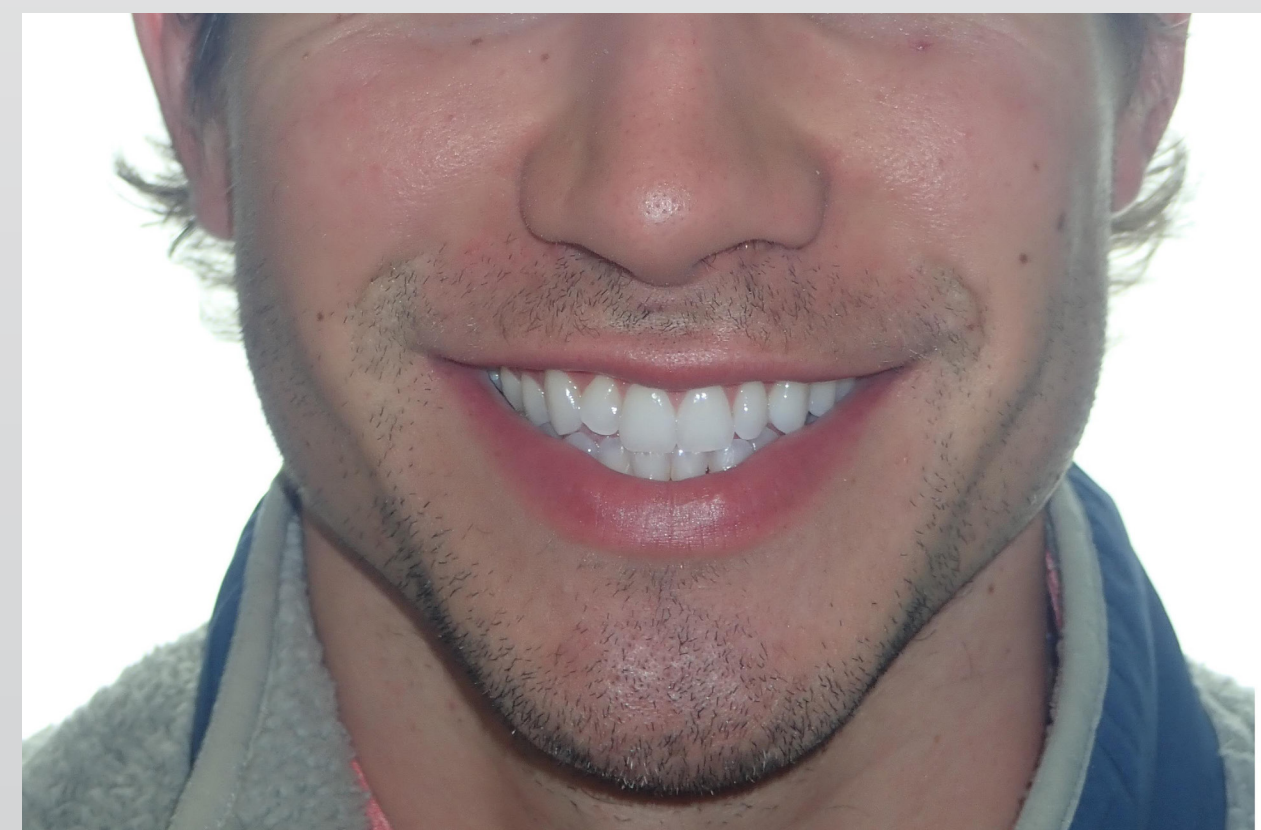
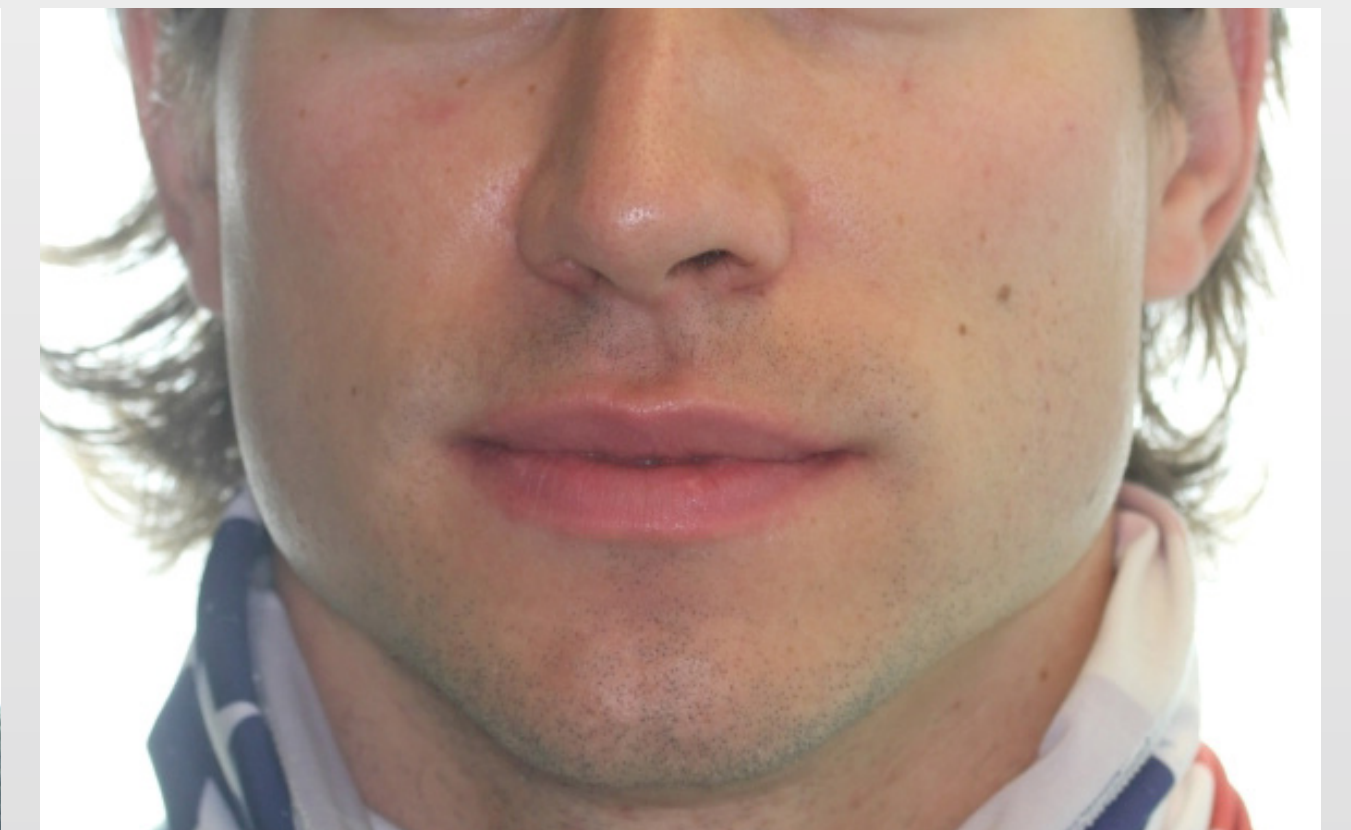
Profile at rest

Progress - 2 years, 2 months



Face at rest



Face smiling

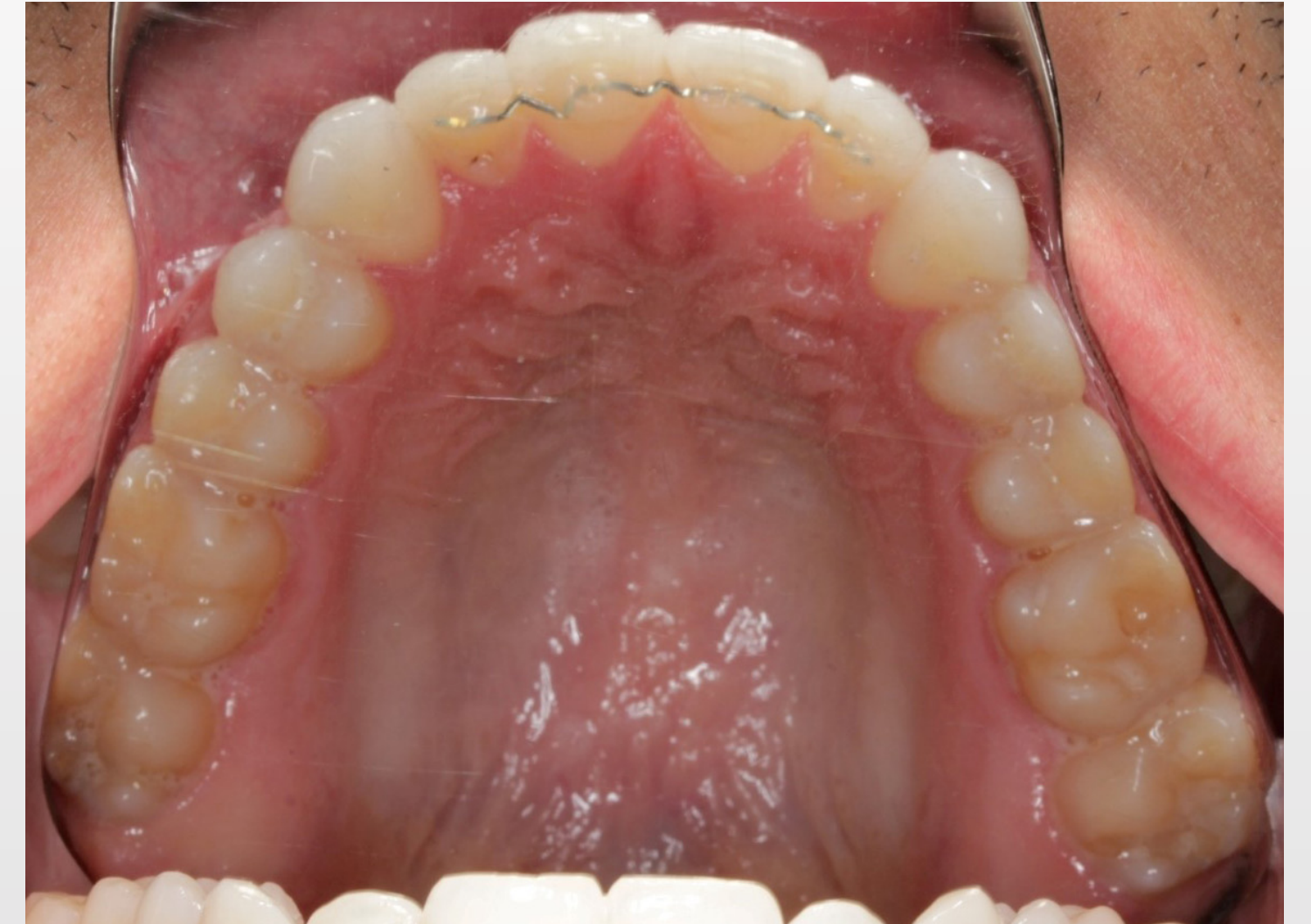
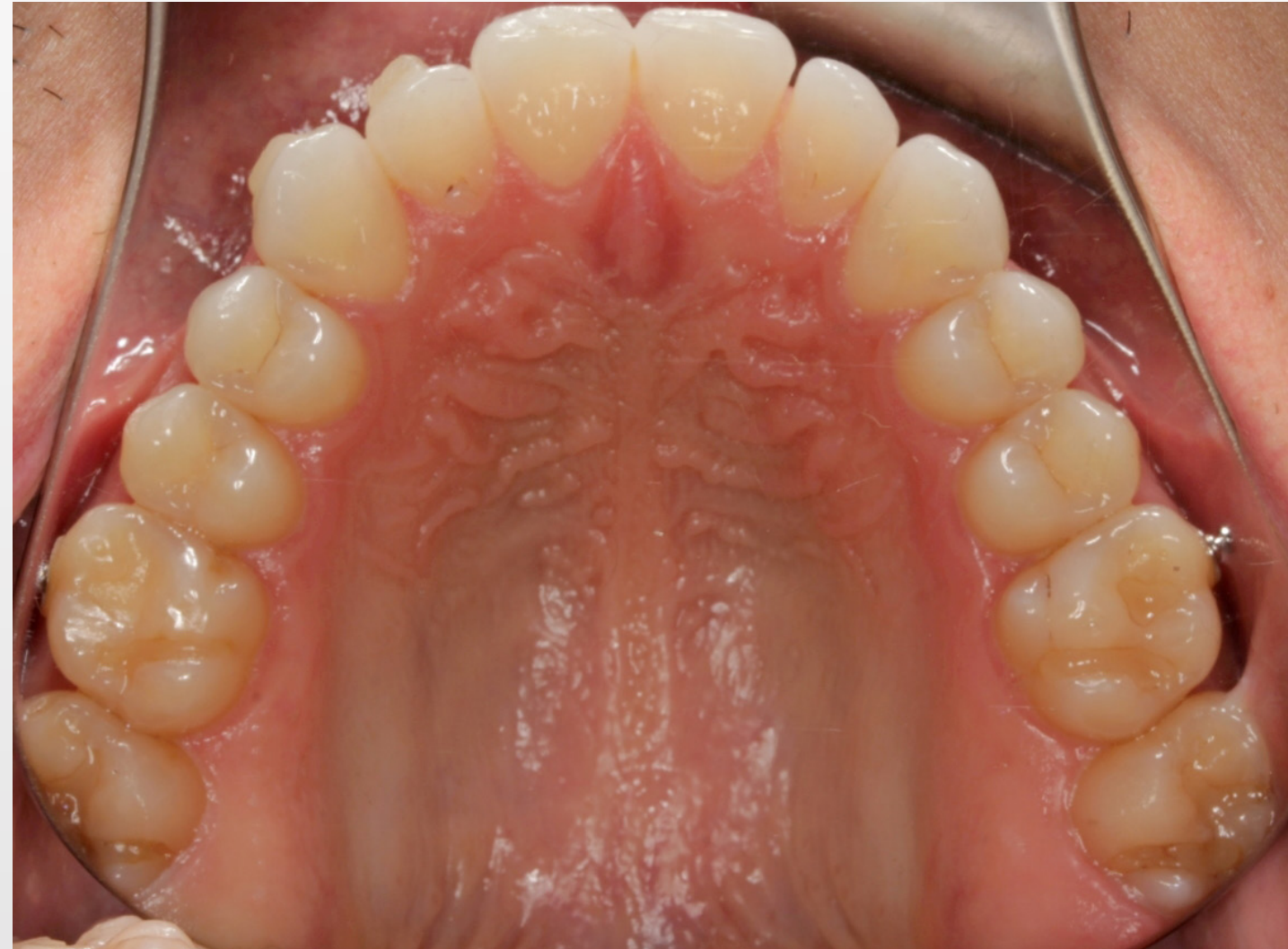
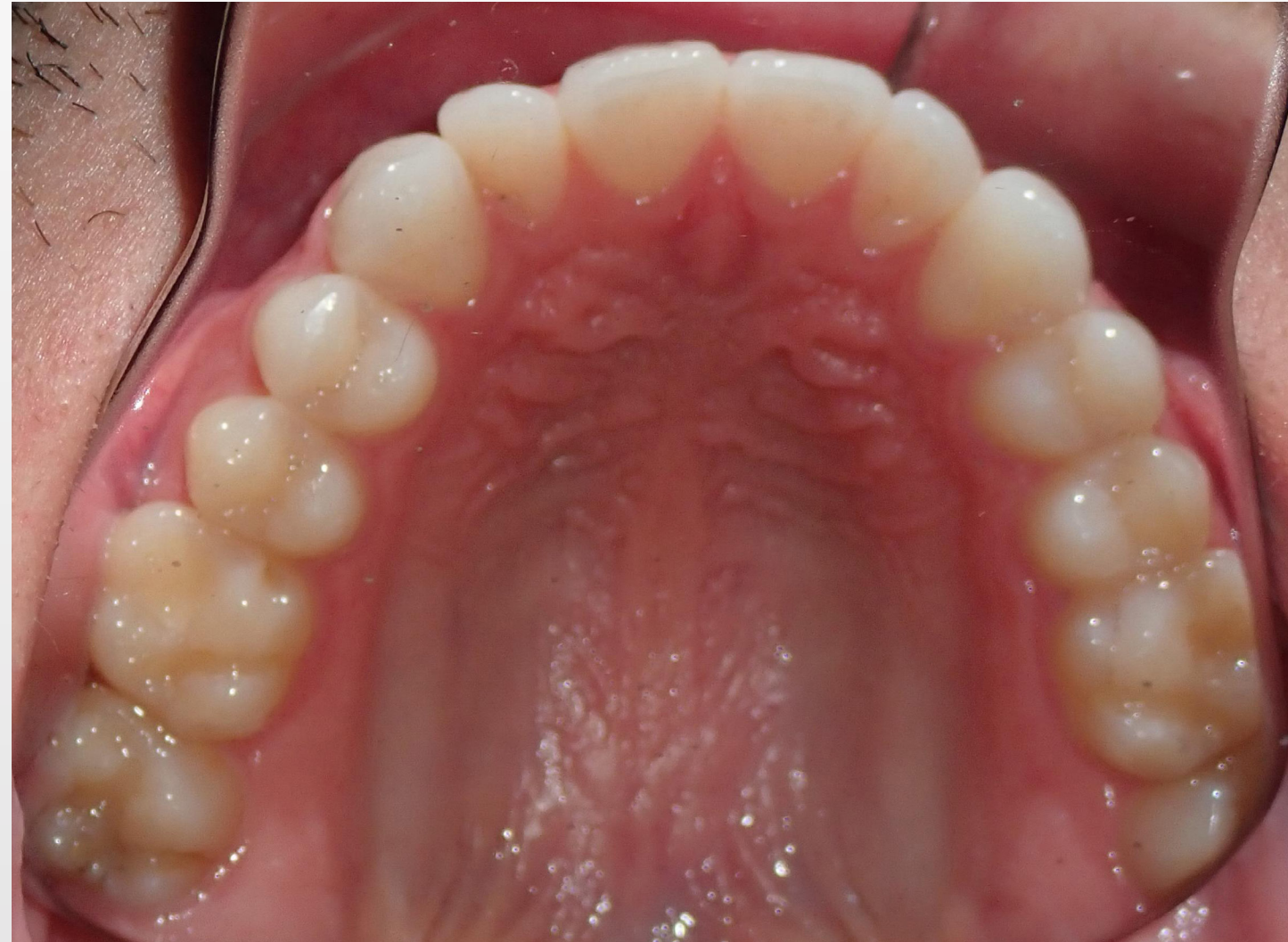Initial

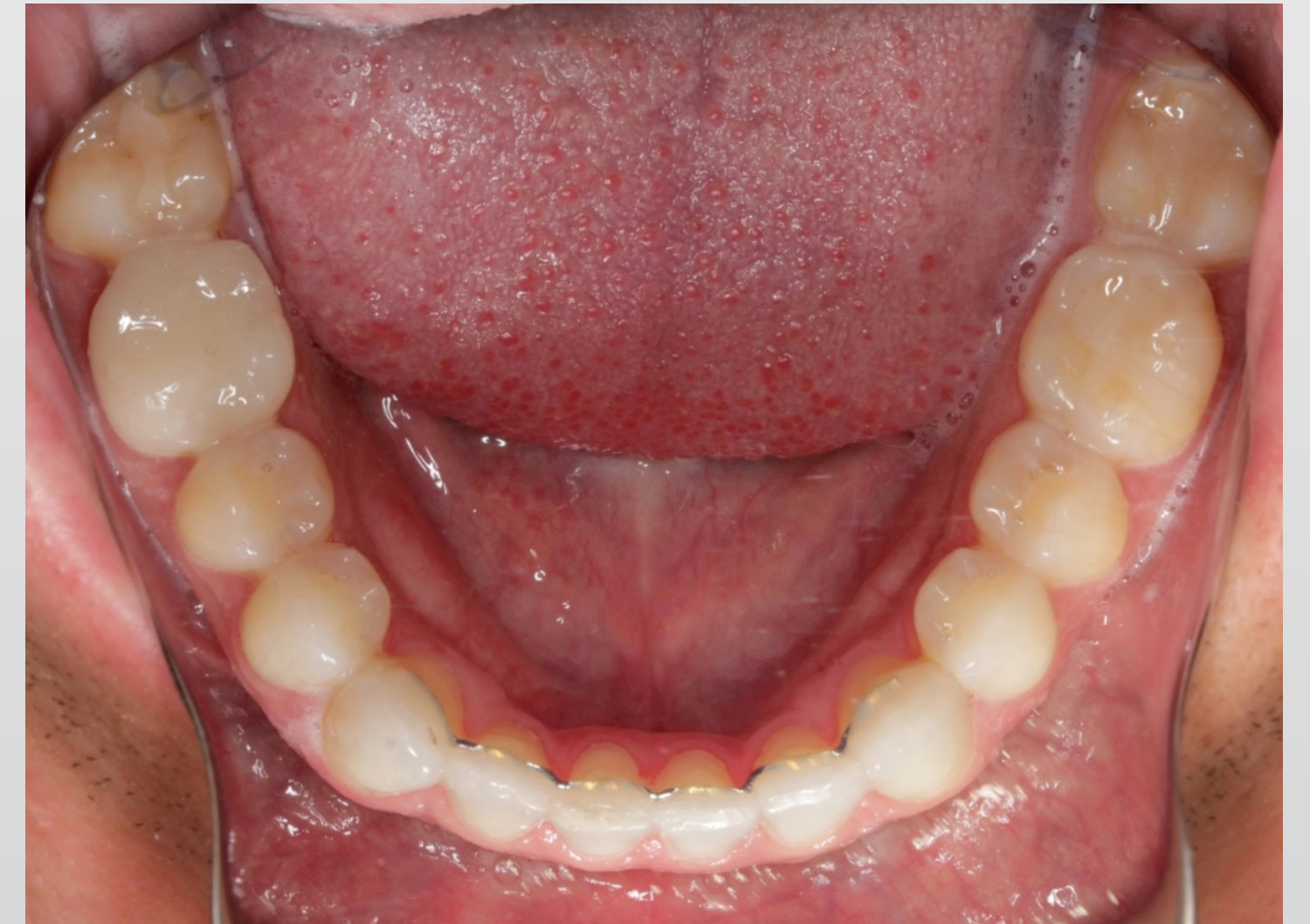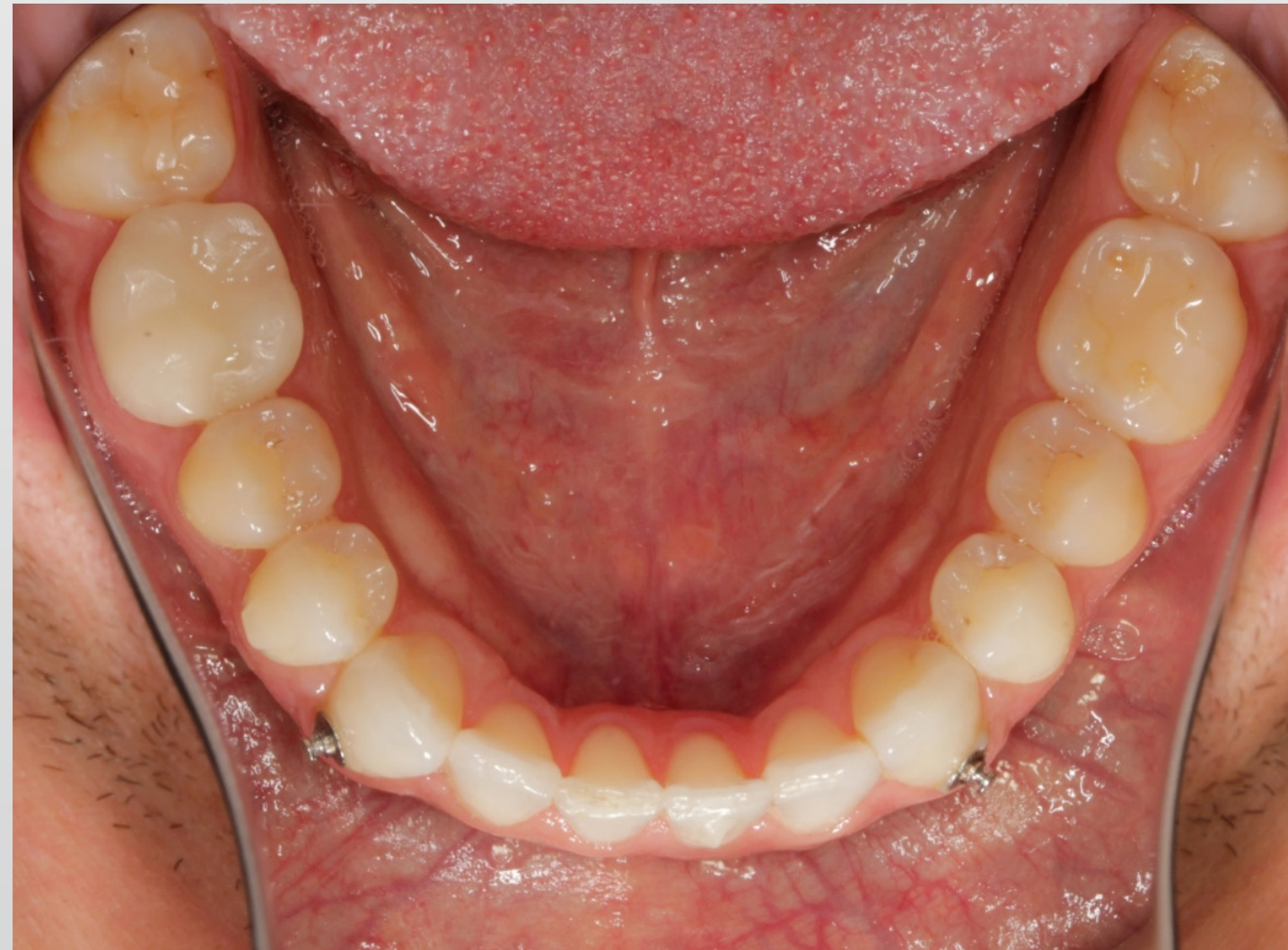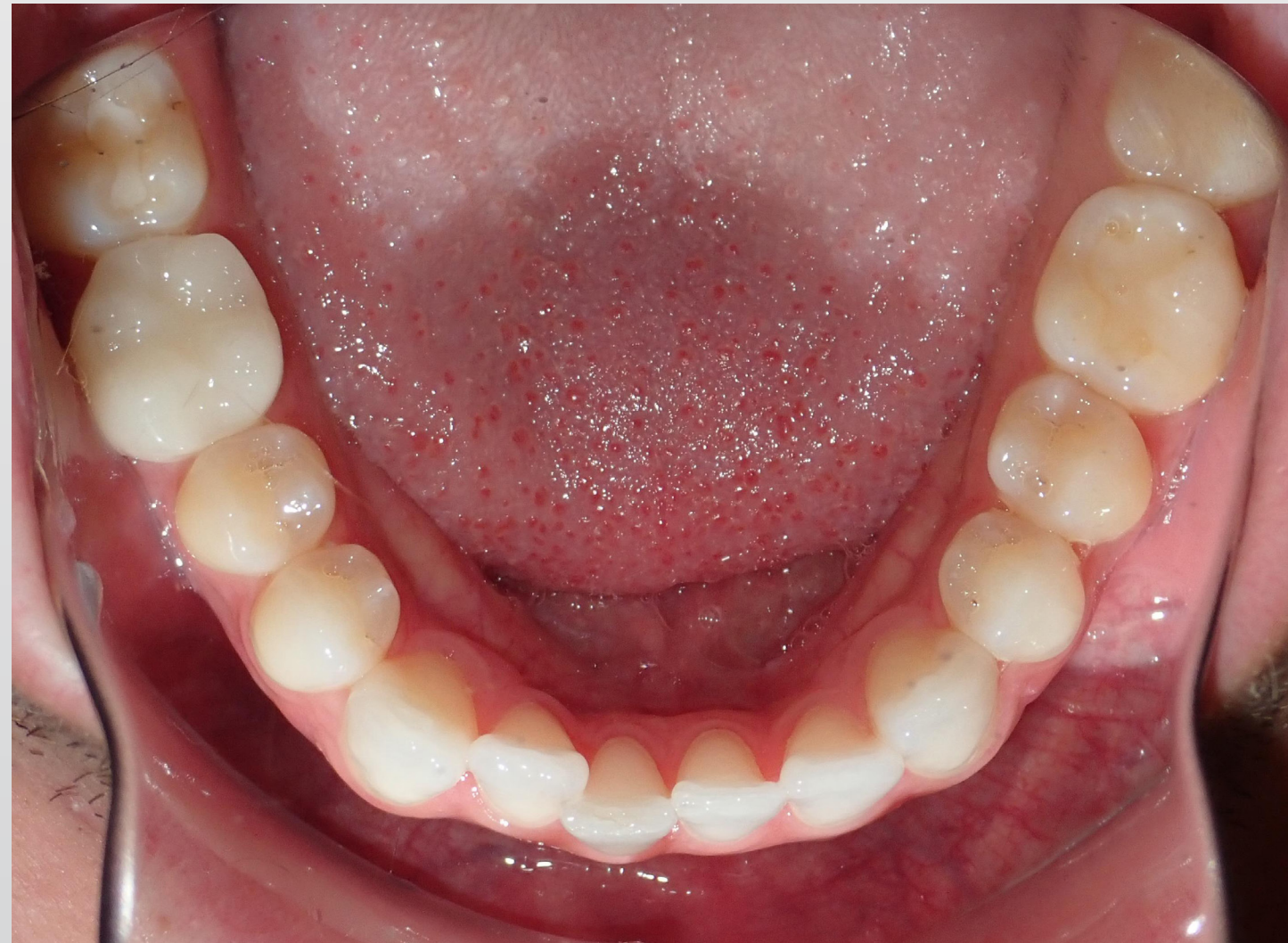Progress - 1 year, 7 months

Final

**Occlusal –
maxillary**



**Occlusal –
mandibular**

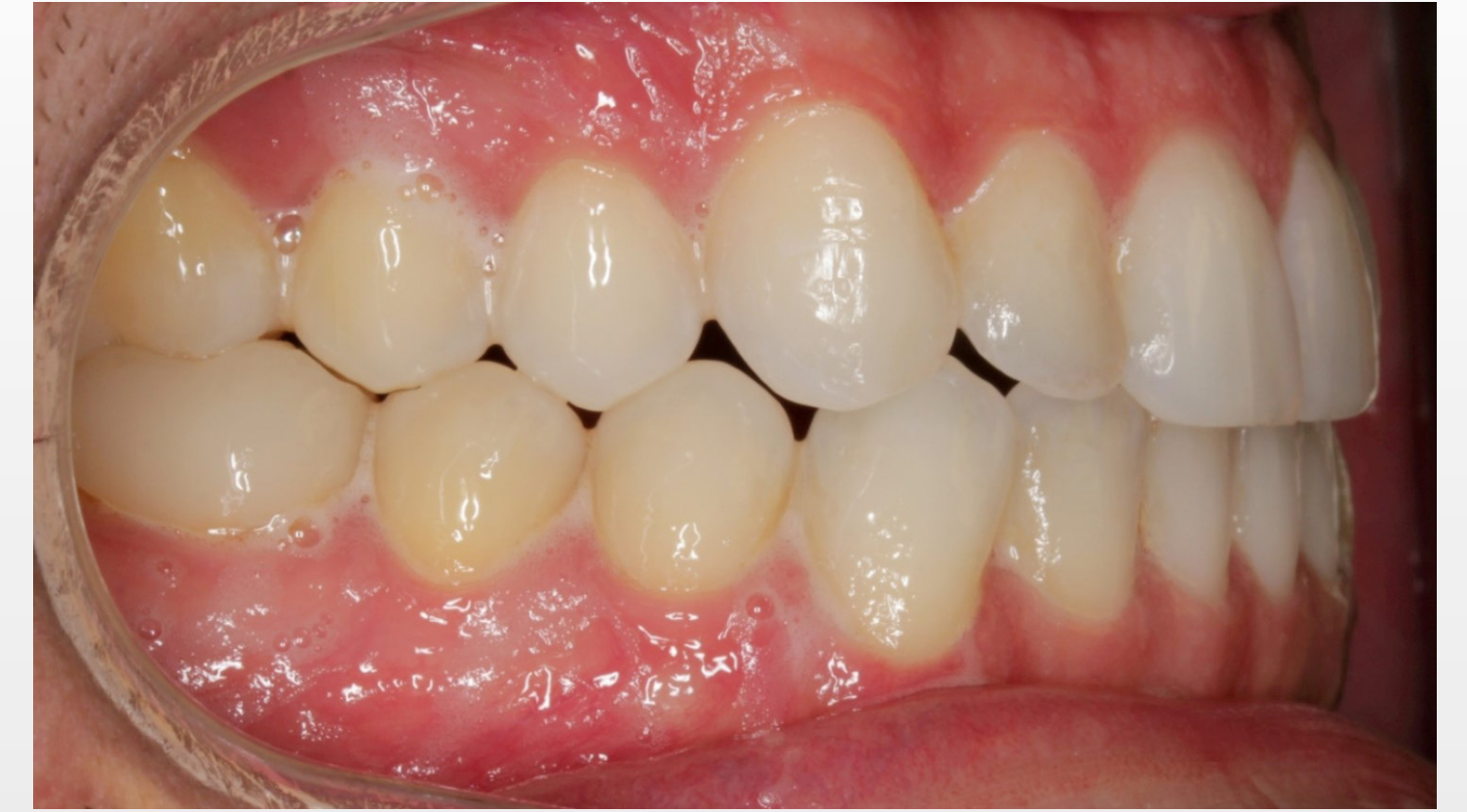
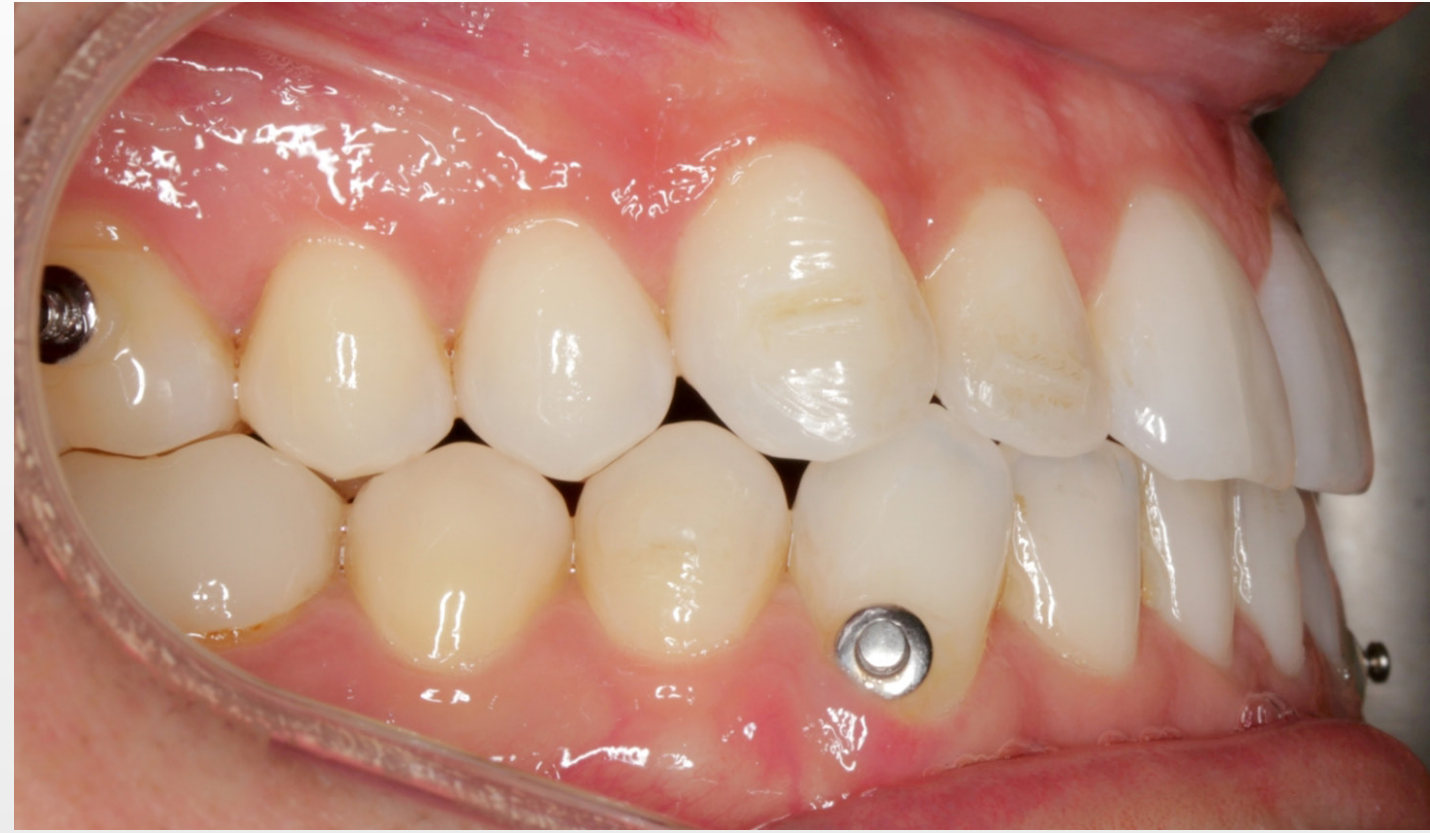
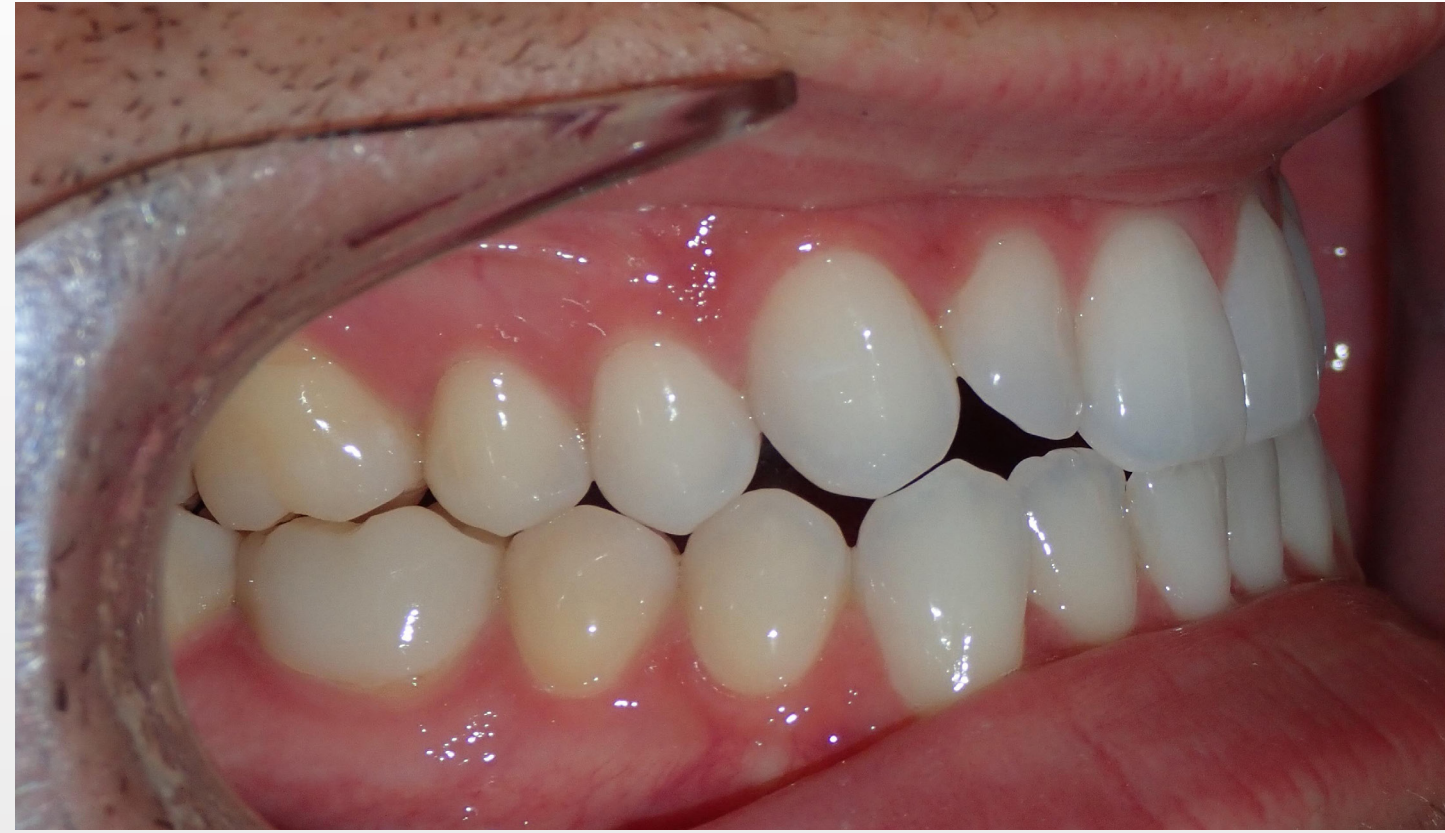Initial

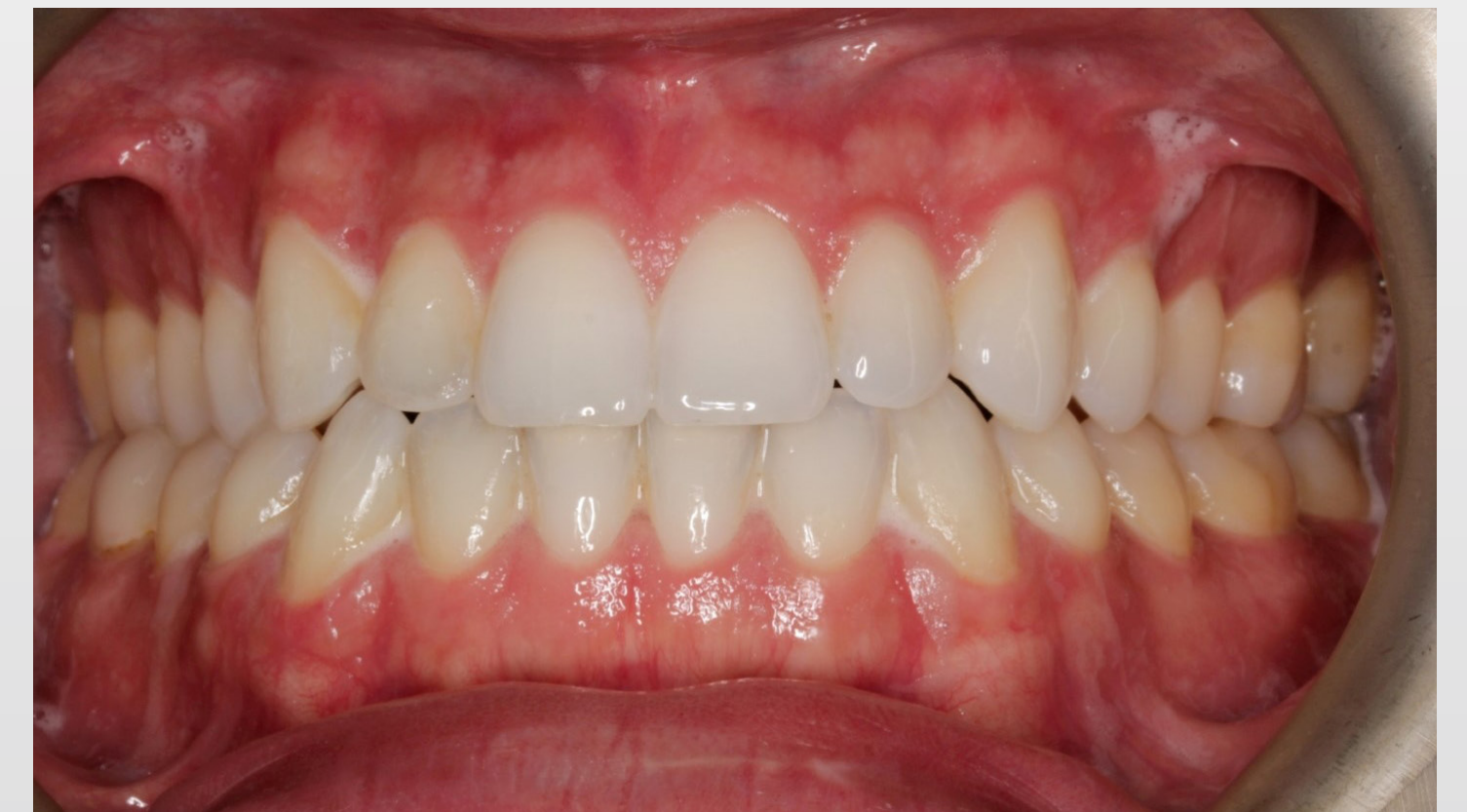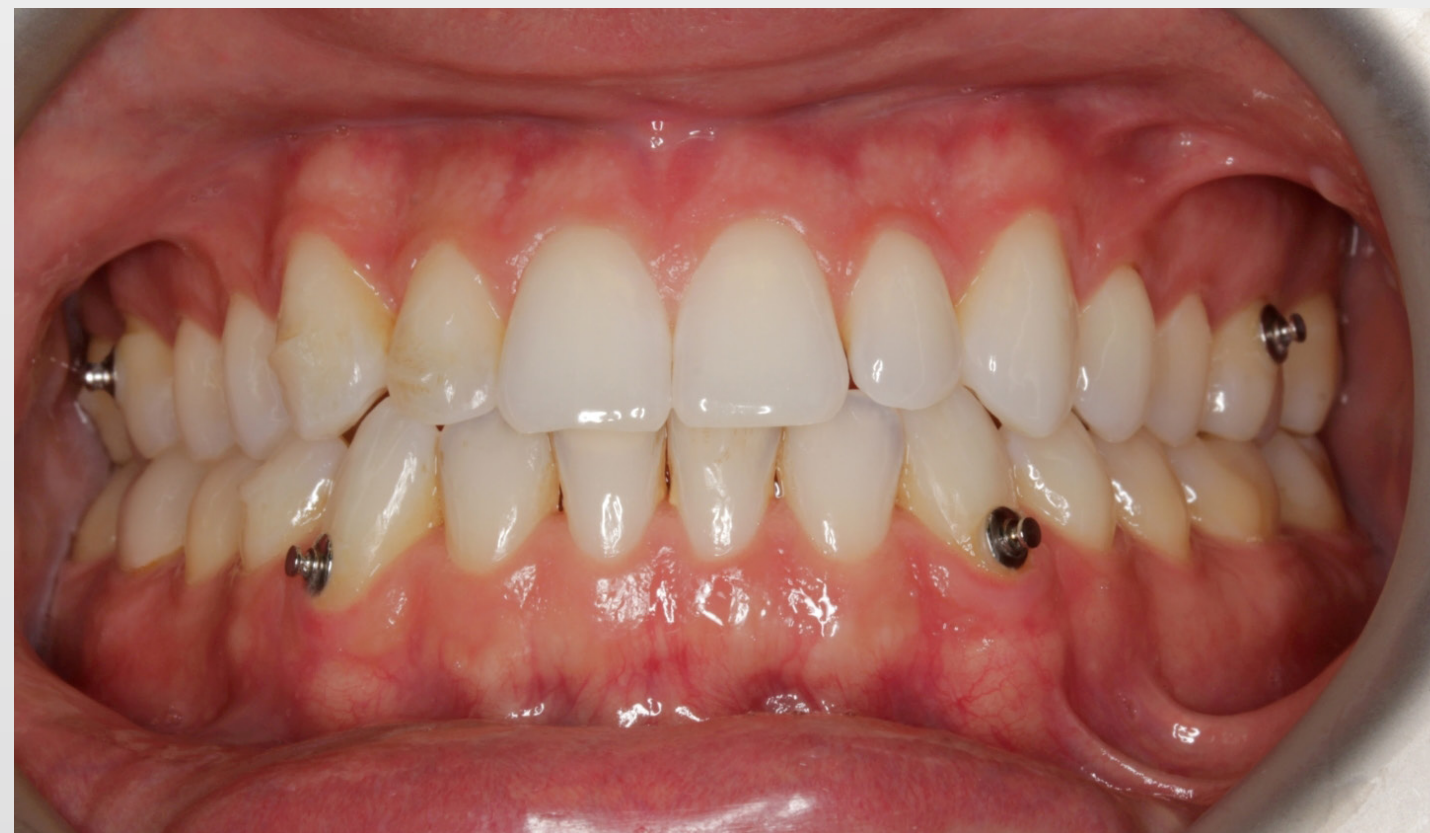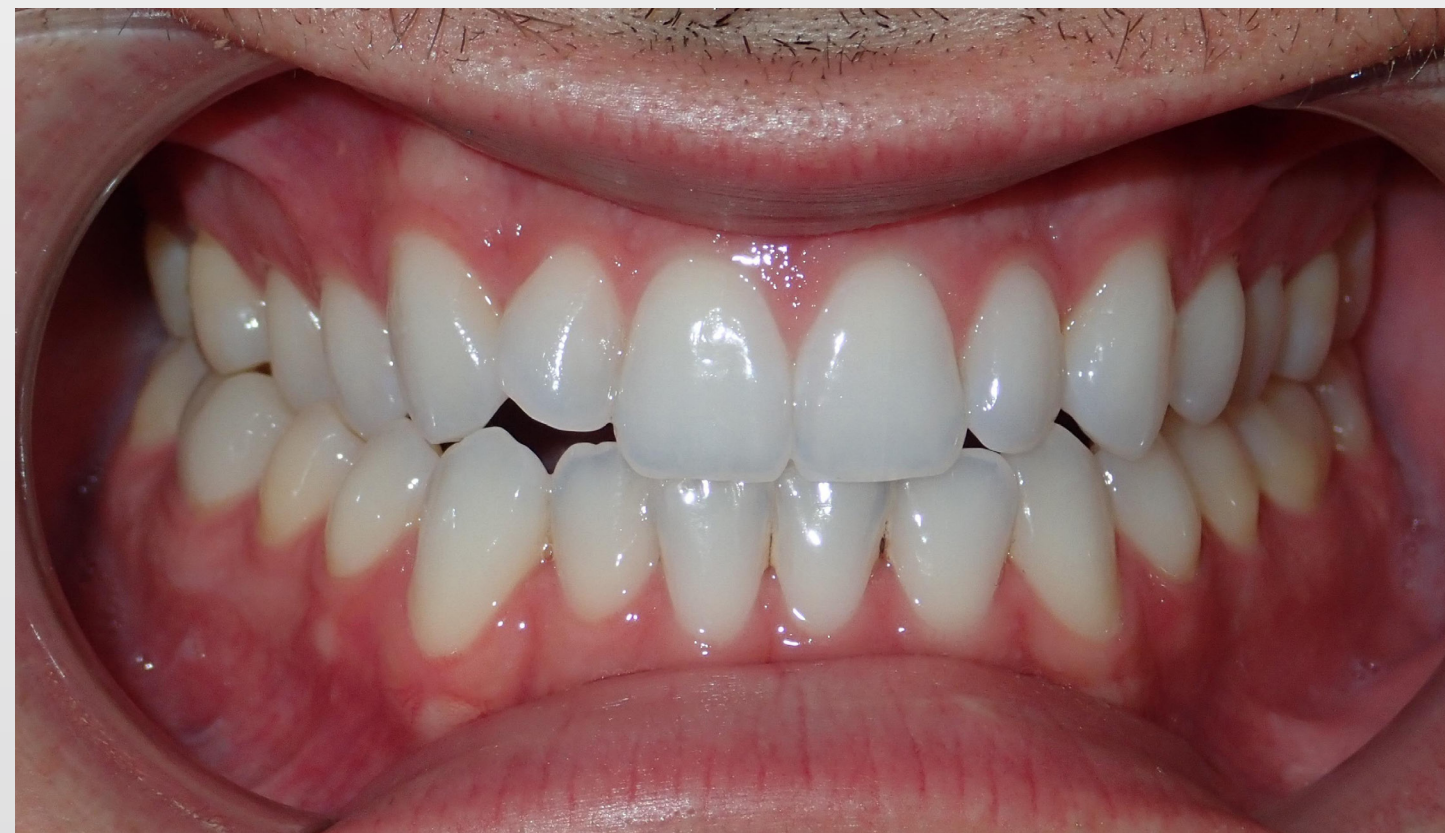Progress - 1 year, 7 months

Final

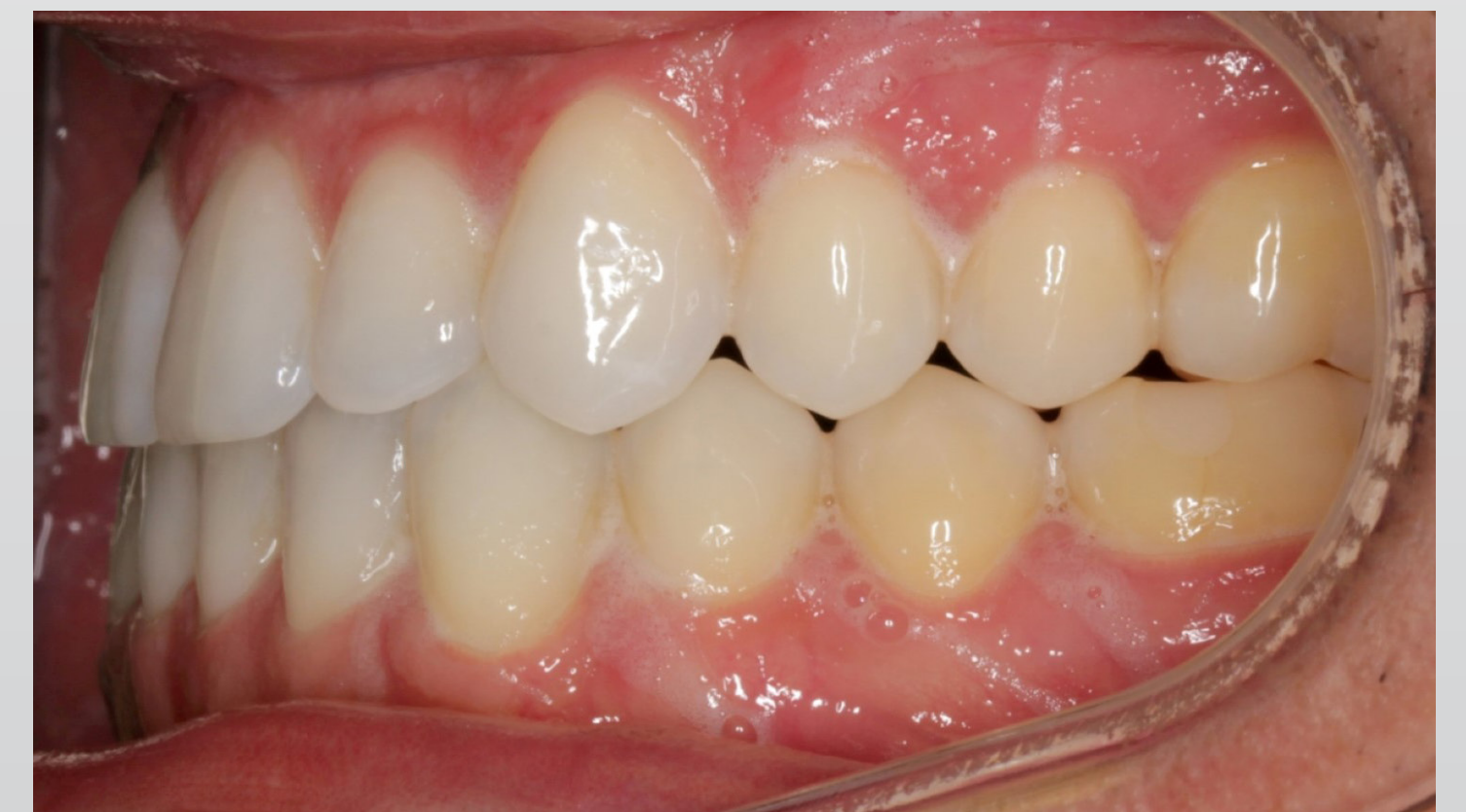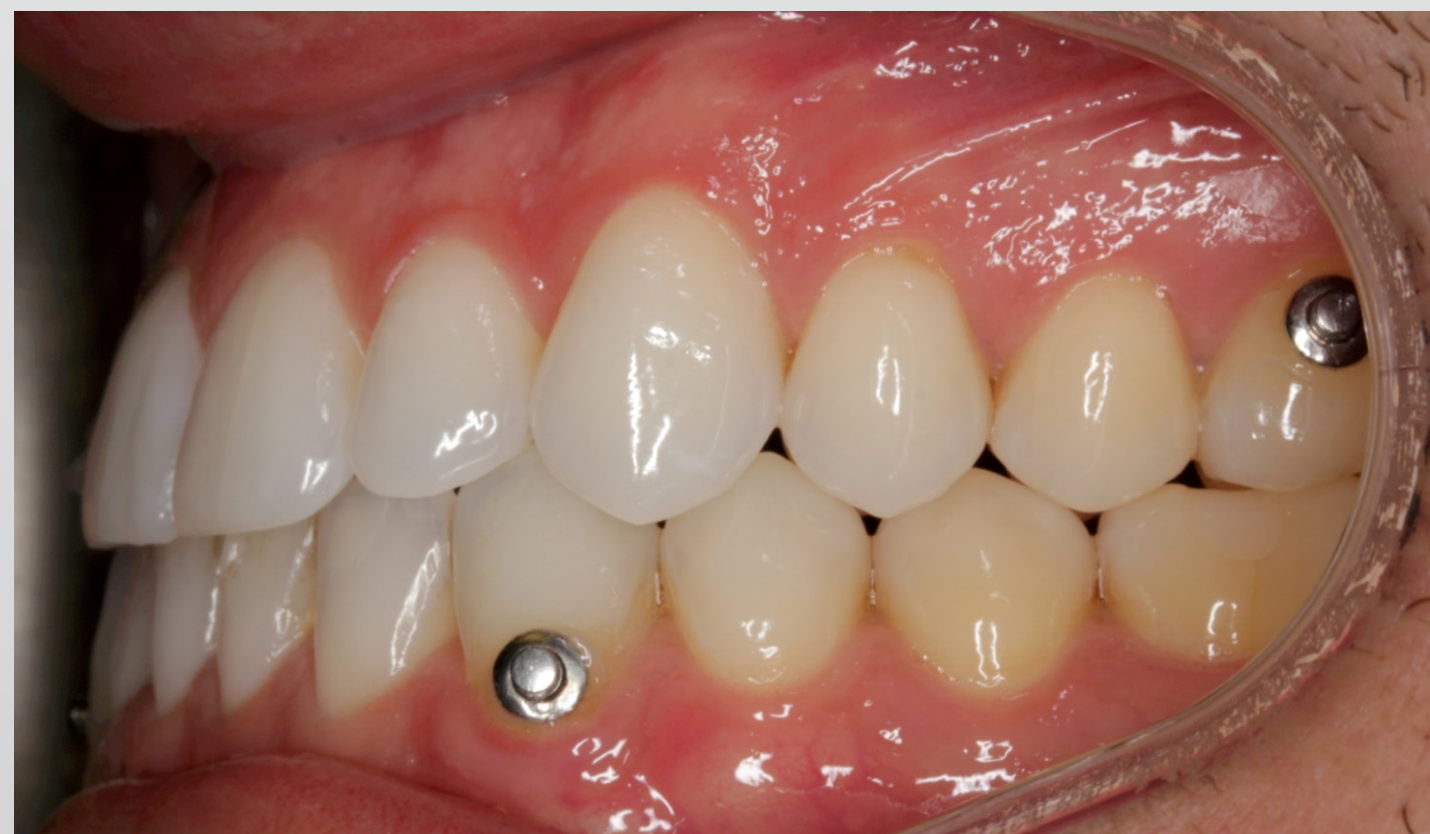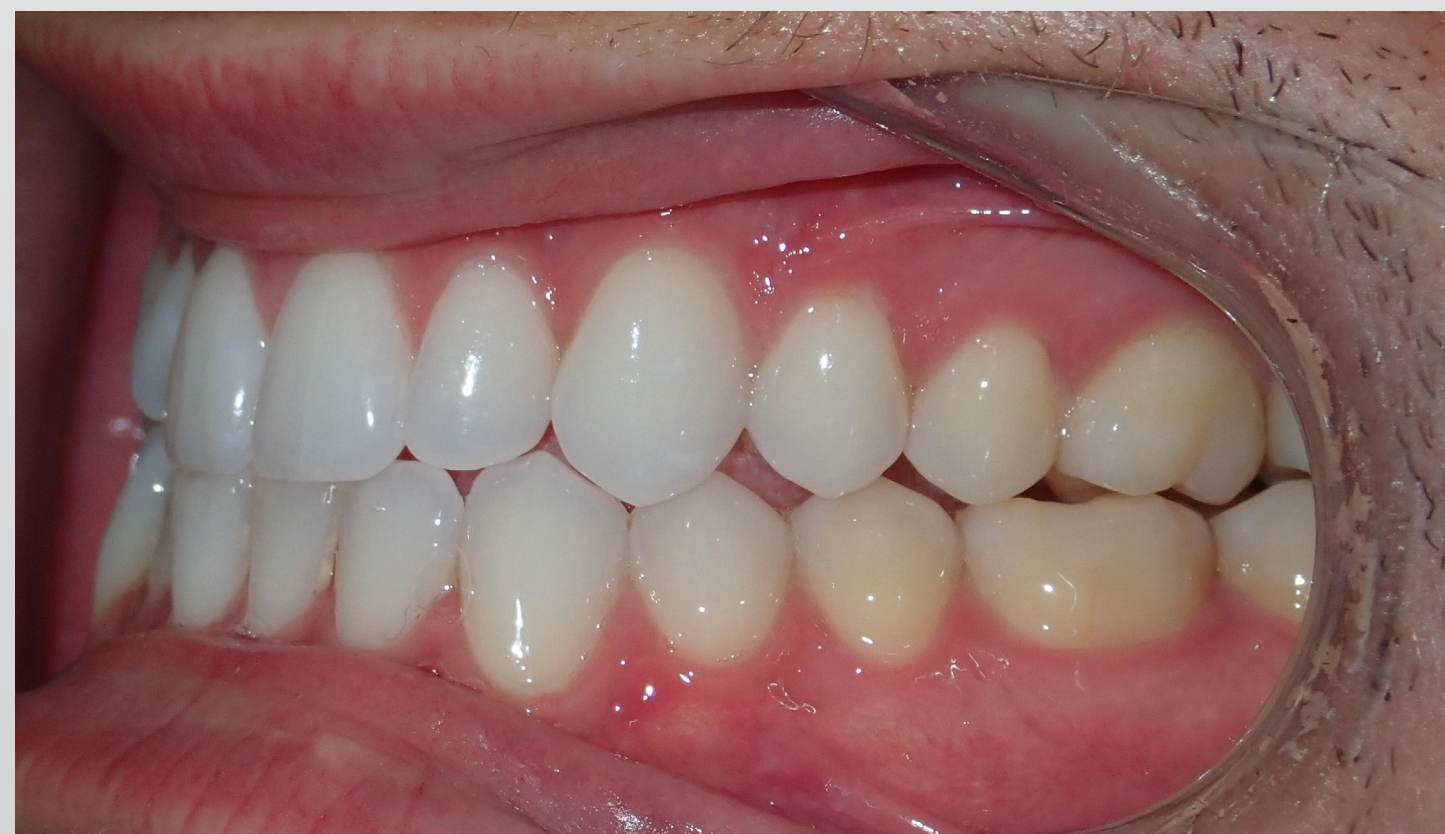**Retracted
buccal – right**



**Retracted
anterior
biting**



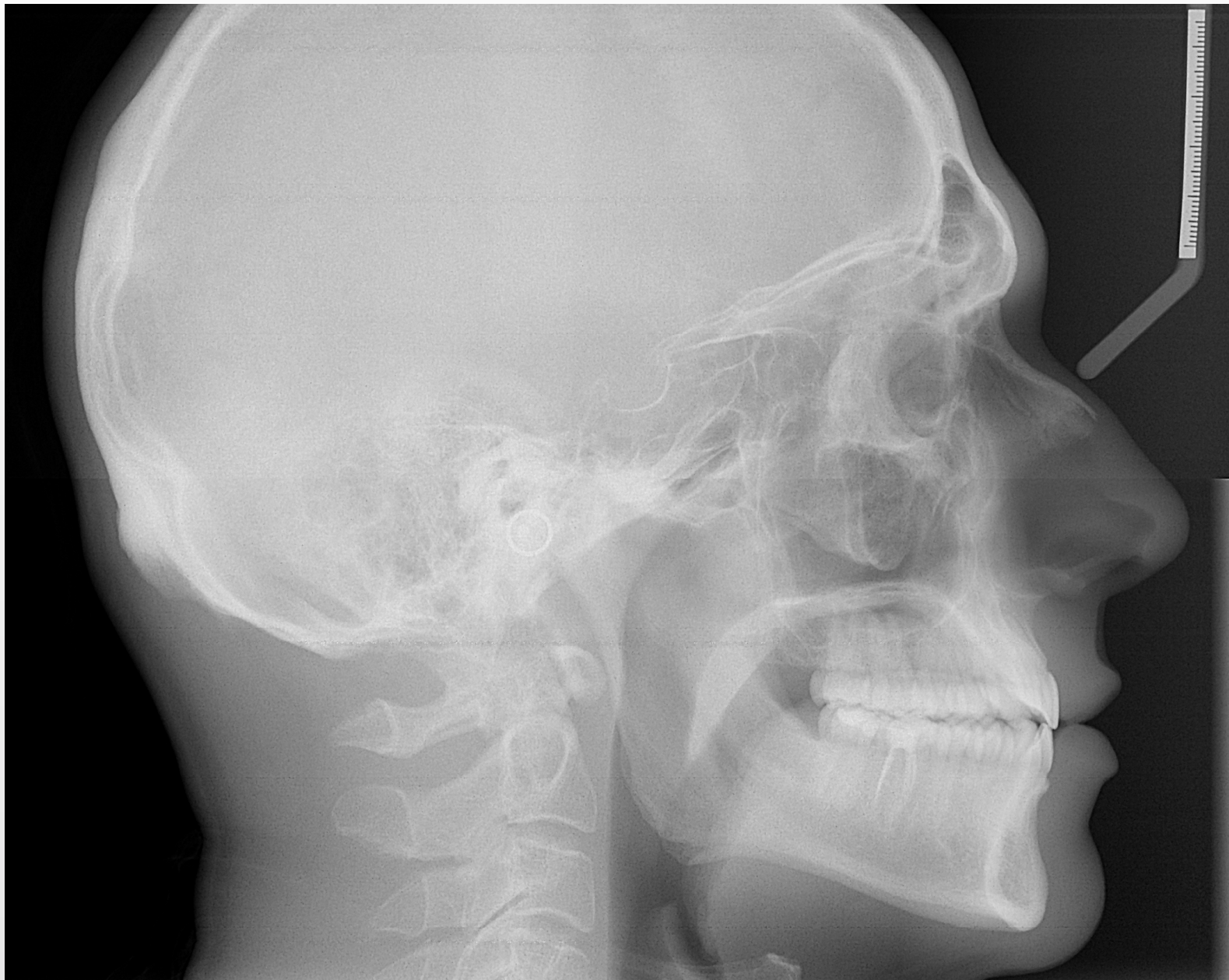
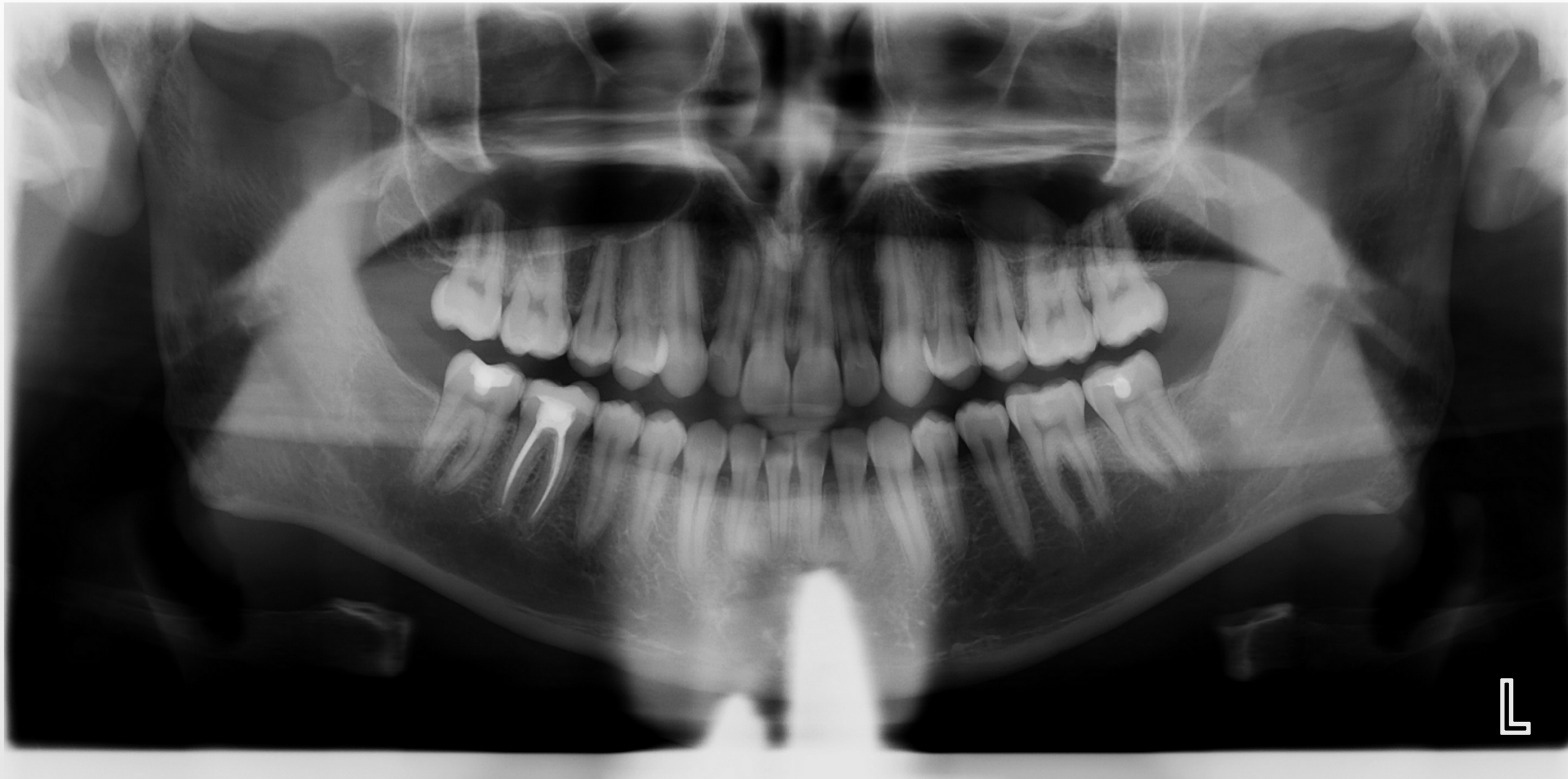**Retracted
buccal – left**



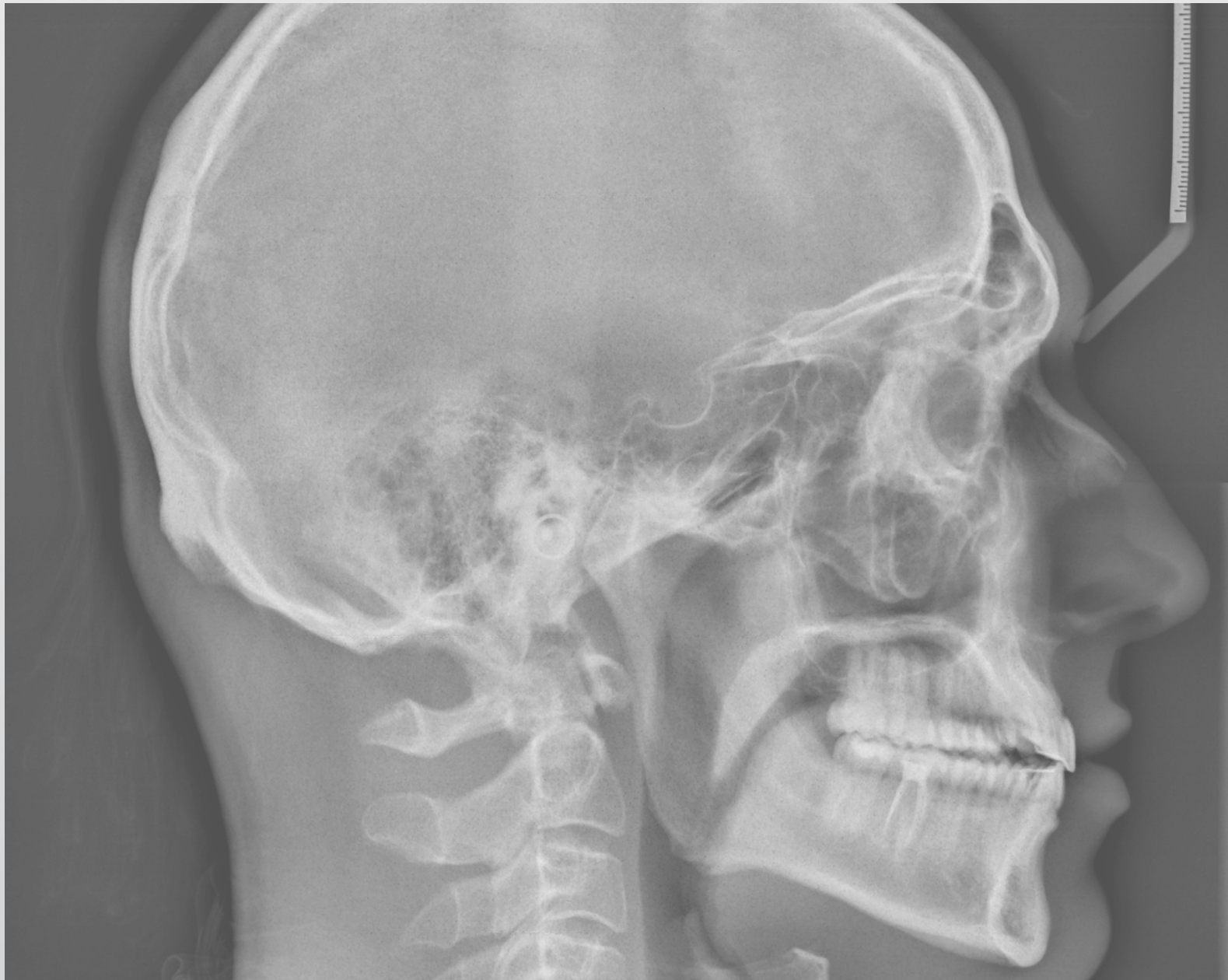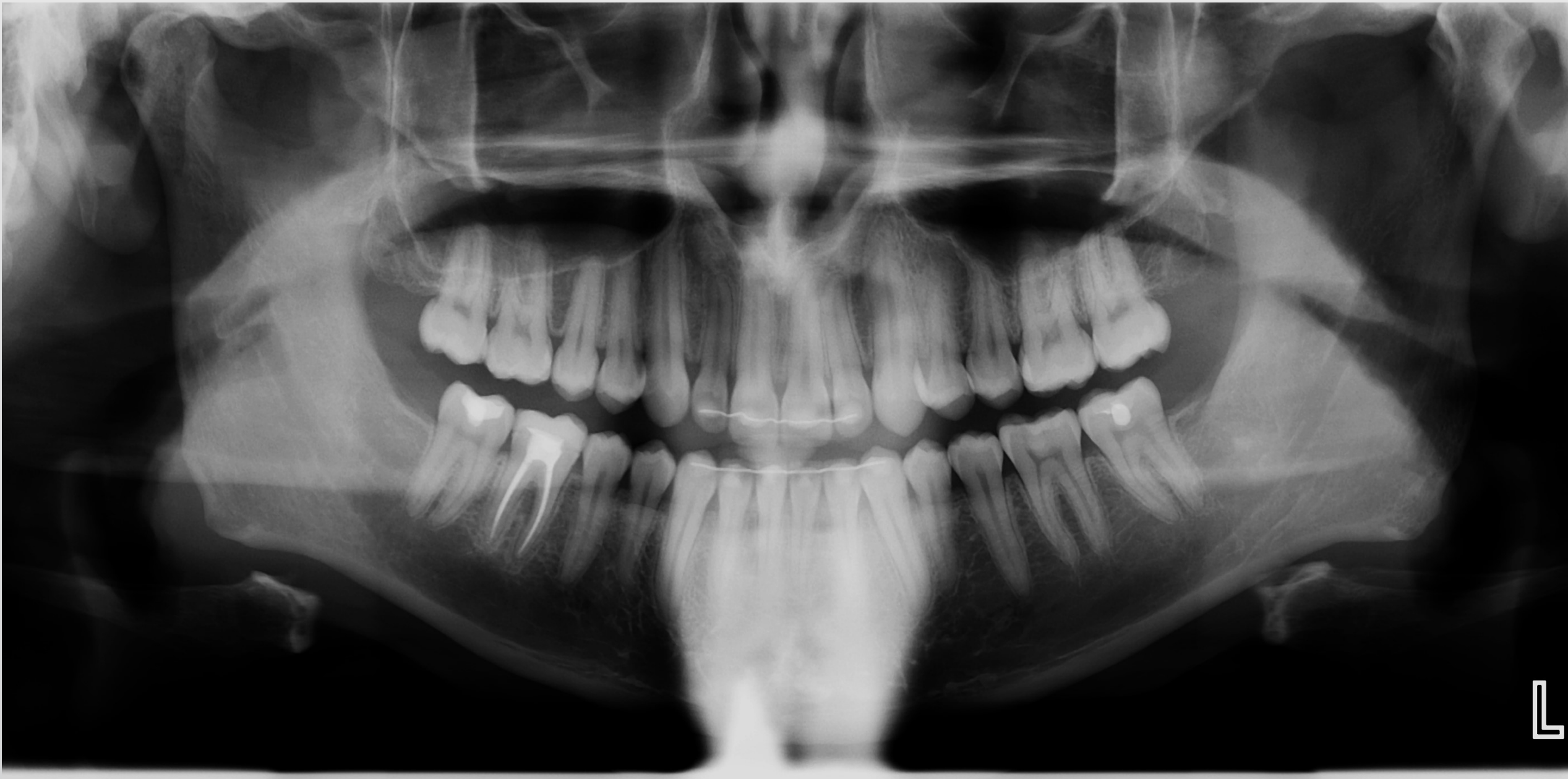Panoramic radiograph

Ceph.

Initial



Final



Tx Design Video

Treatment Plan
Attachment Strategy
Key Movements
Summary of Final Results

