

**Case Study:** 3M™ Clarity™ Aligners

## Deep bite correction with mild to moderate crowding

**Age:** 27

**Chief concern:** Space between front teeth

**Case diagnostics:** Class I occlusion with palatally impinging deep bite. Mild/moderate lower crowding, upper spacing, and upper laterals with tooth size discrepancy

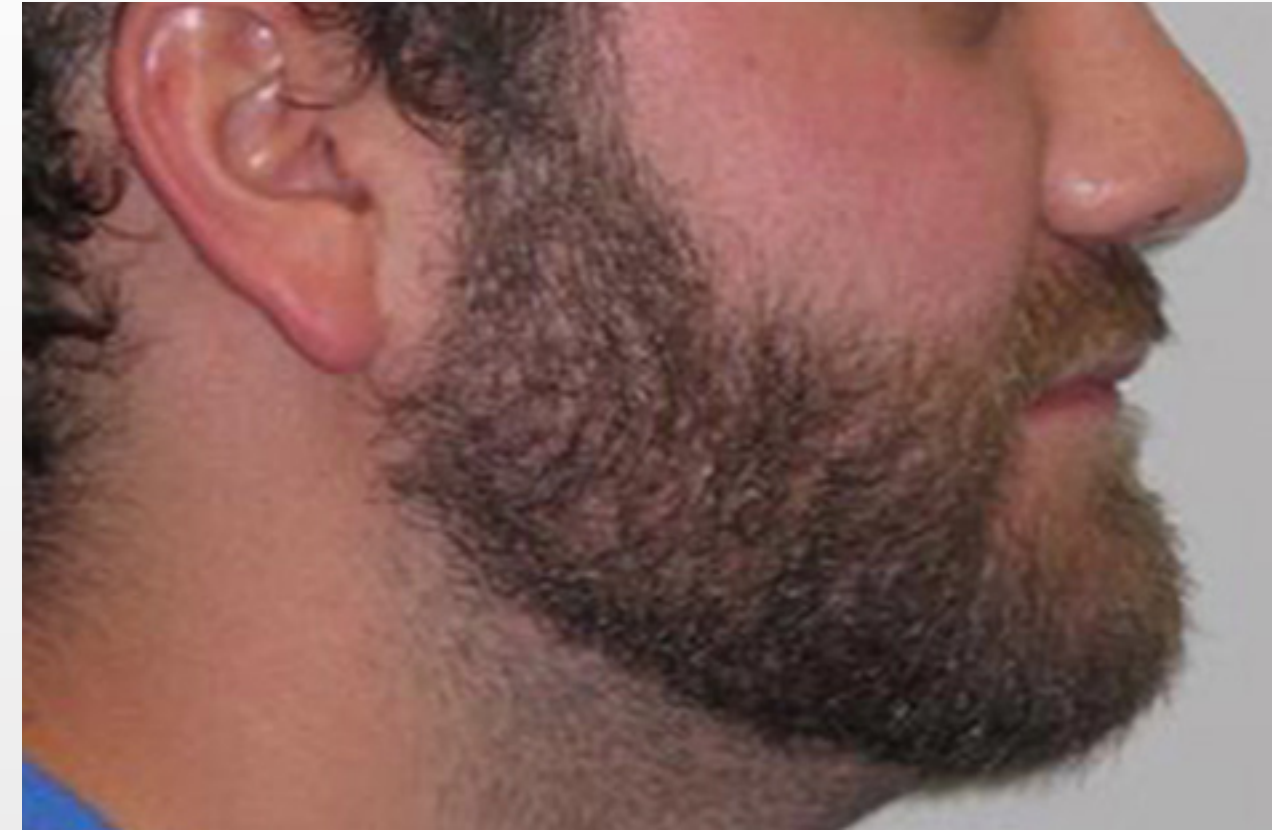**Total number of aligners:** 56  
(25 initial Tx Design, 16 refinement #1, 15 refinement #2)

**Wear interval:** Started at two weeks and transitioned to weekly

**Treatment time:** 16 months of active treatment

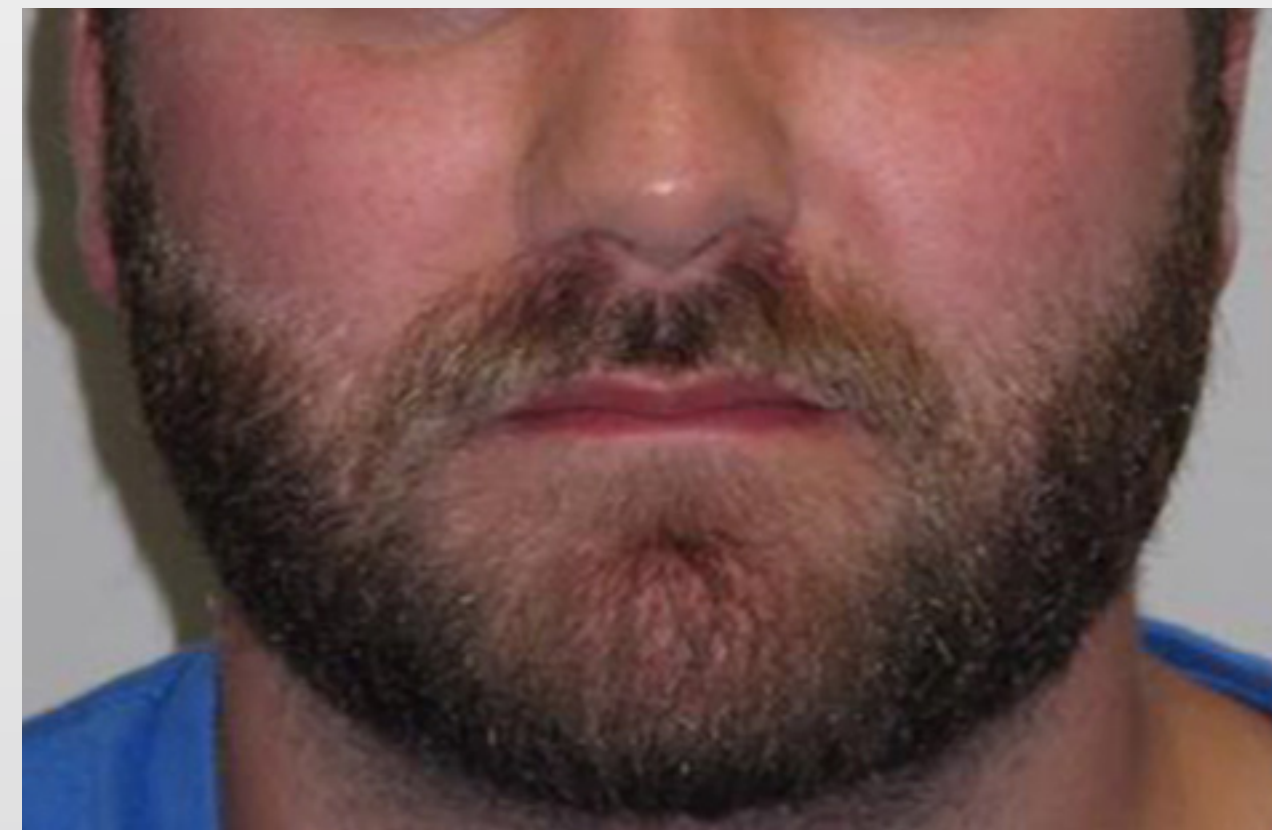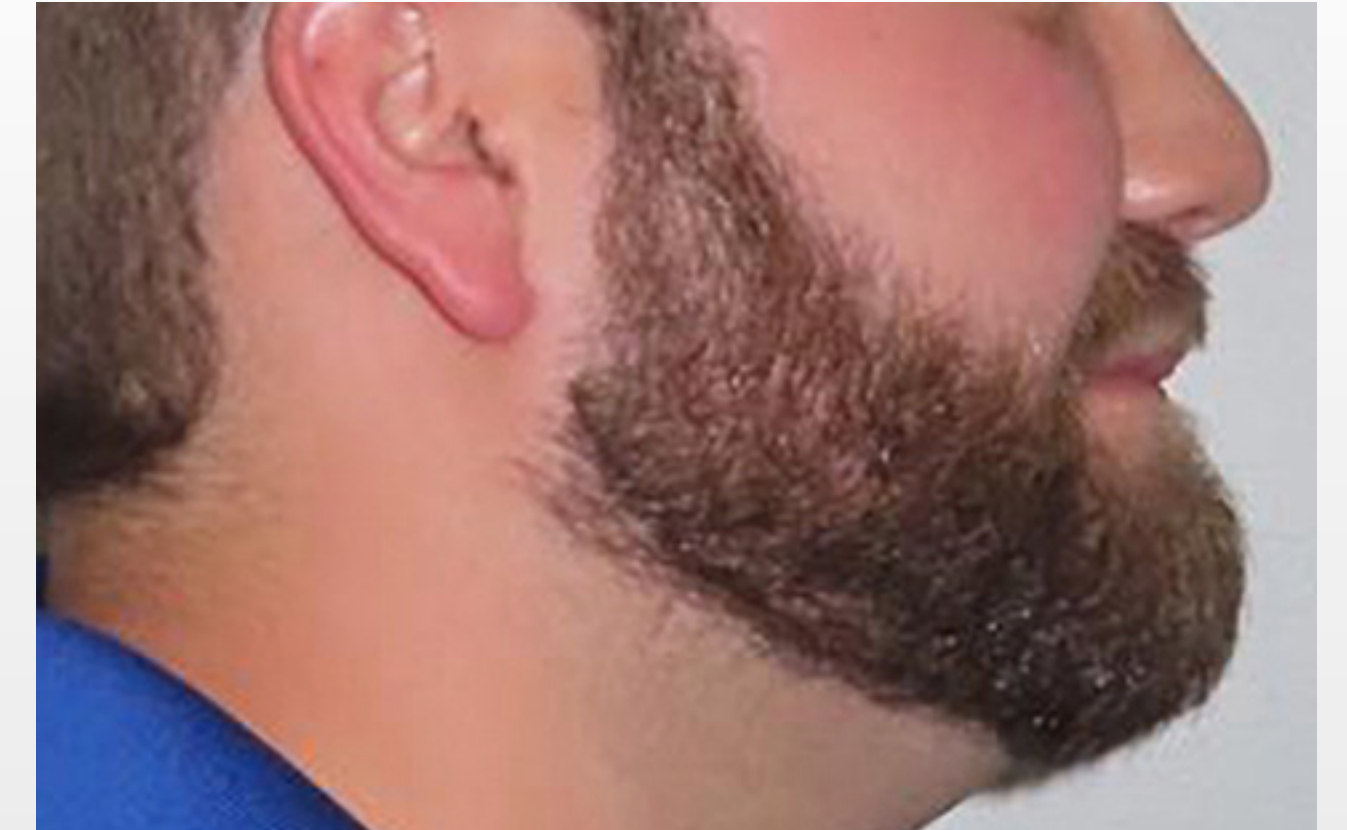**Case courtesy of:**  
Dr. Rick O'Neil & Dr. Shane Langley  
South Alabama Orthodontics, Fairhope, AL – USA

**Initial**

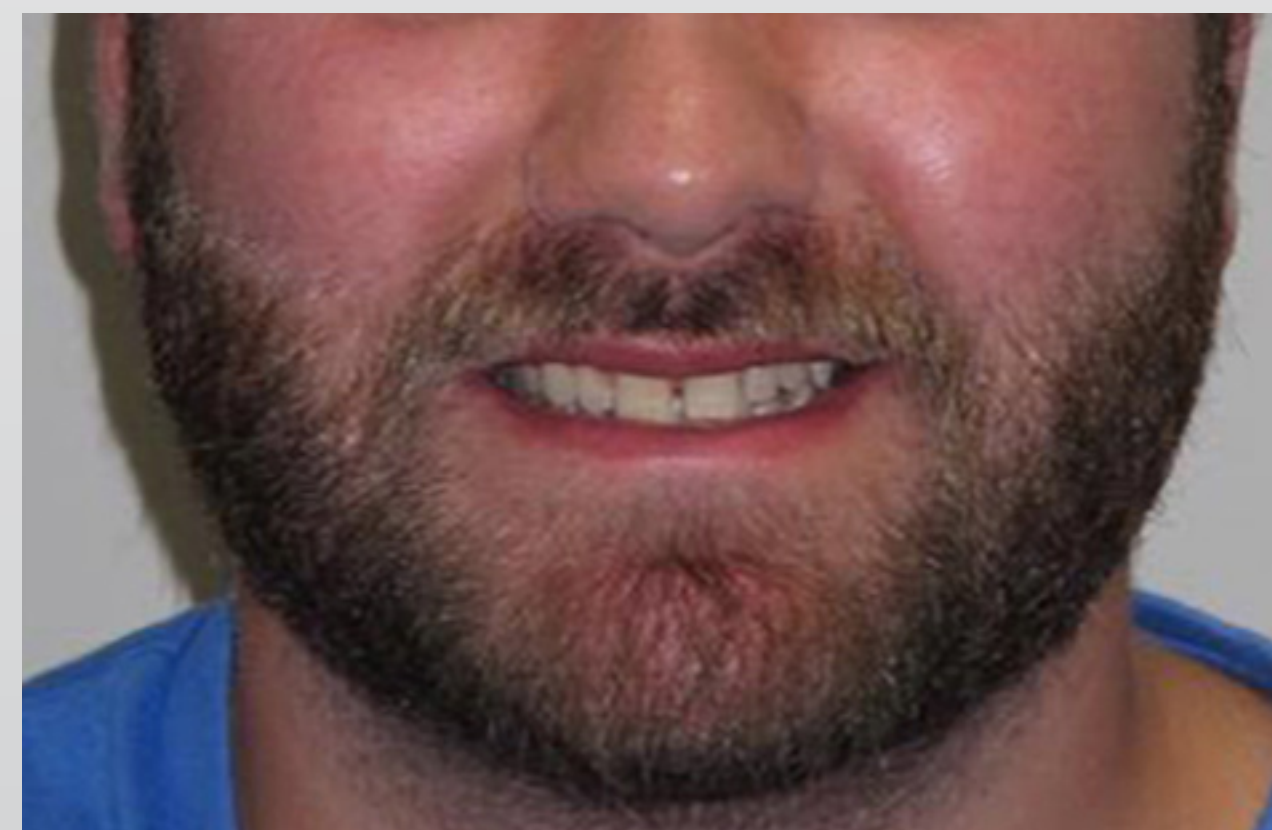
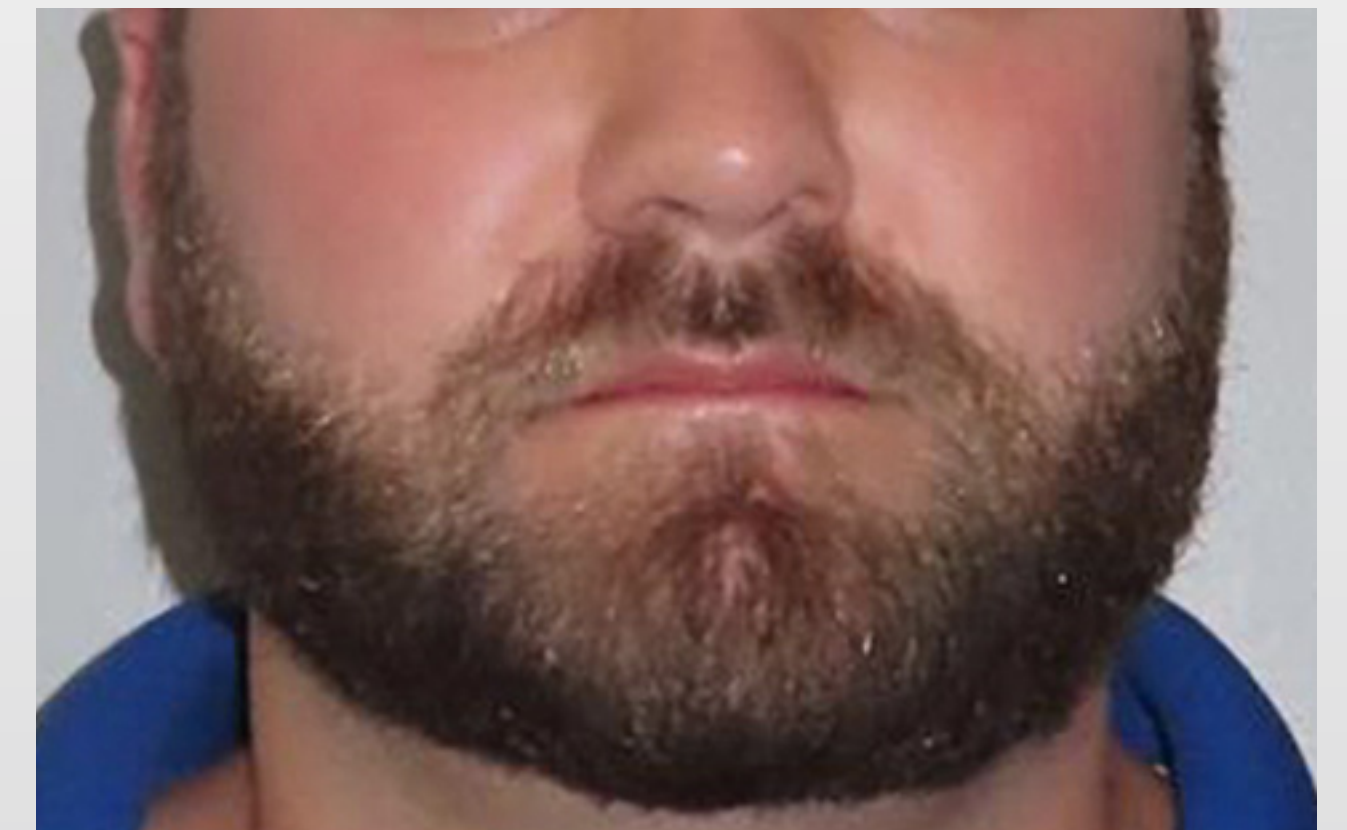
**Profile at rest**

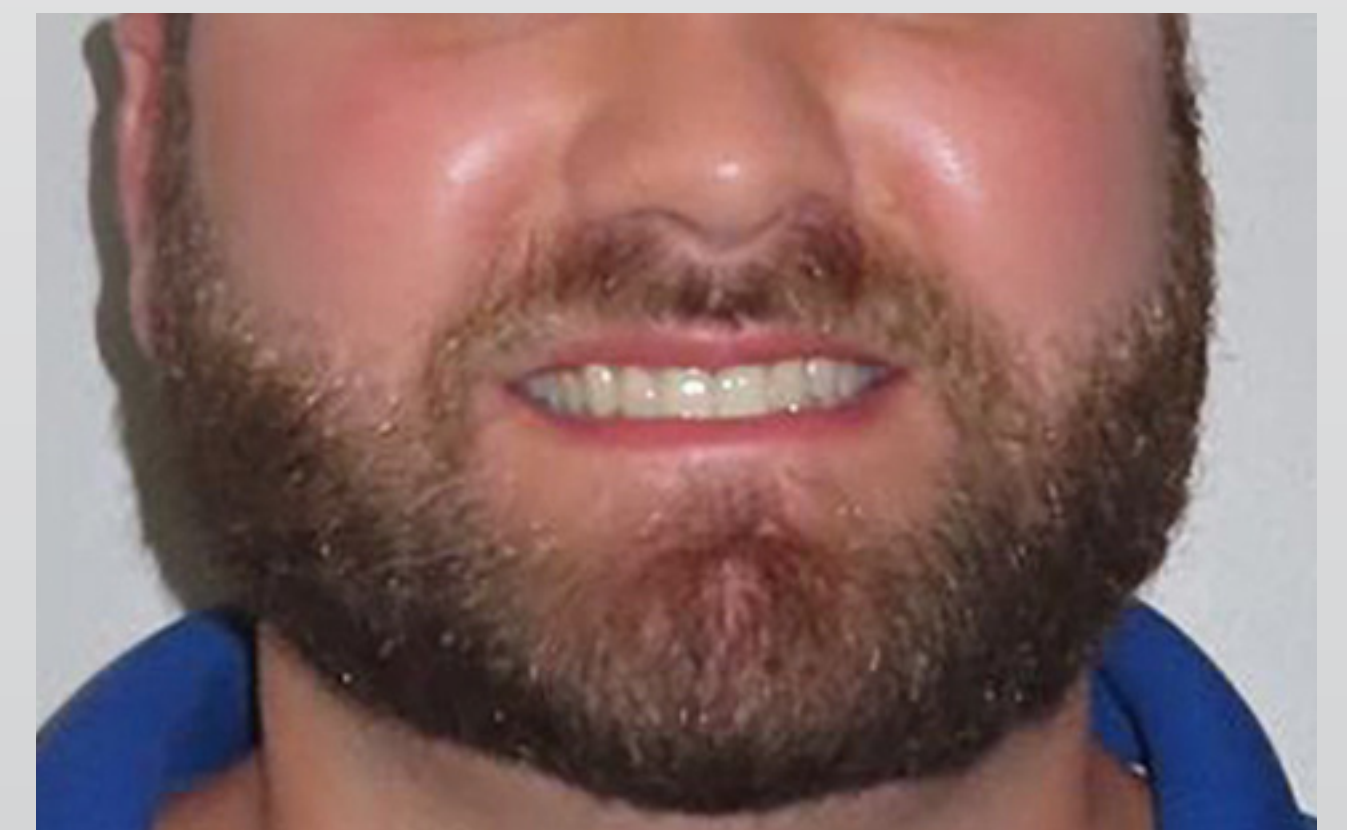**Final**



**Face at rest**



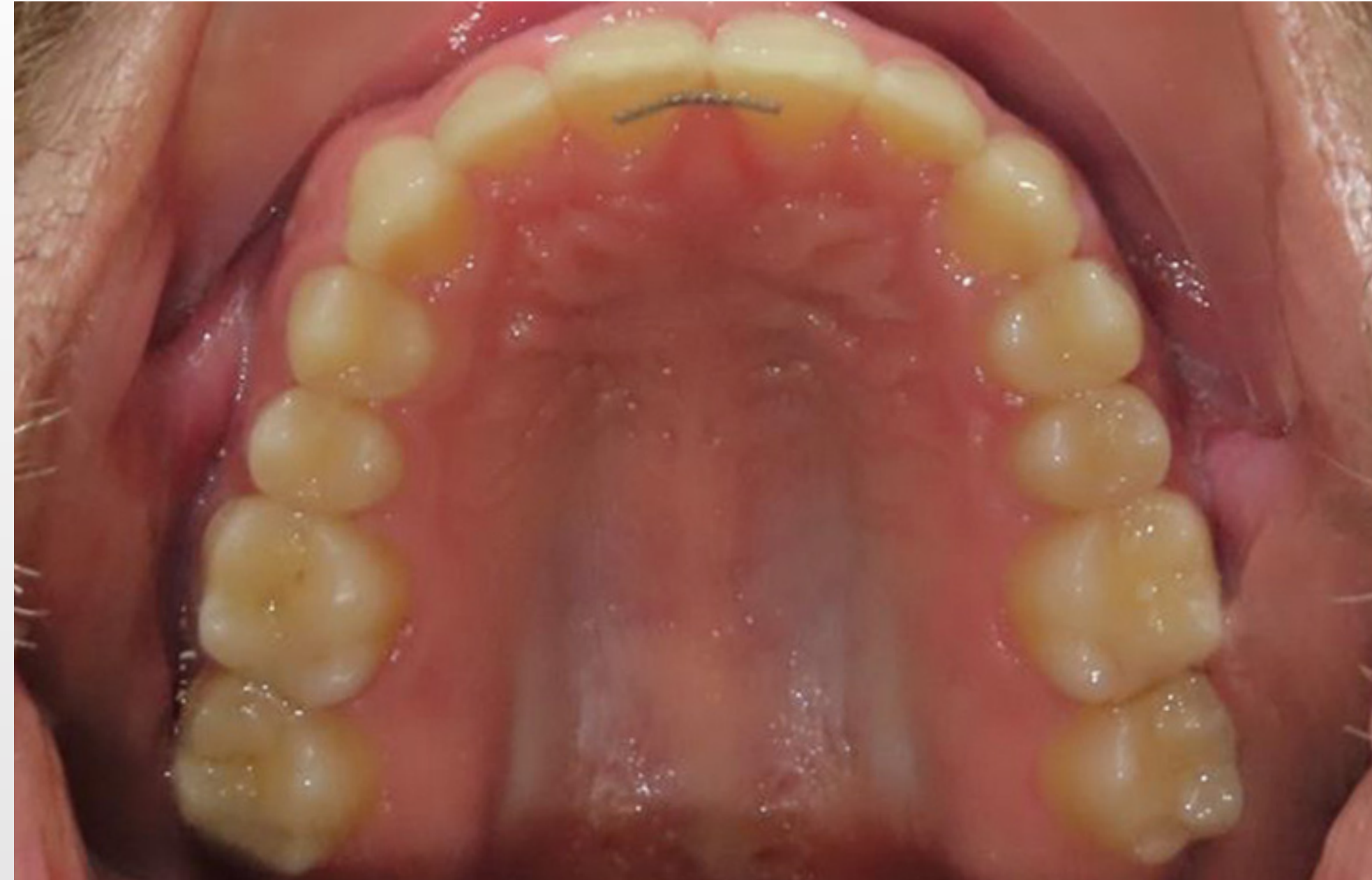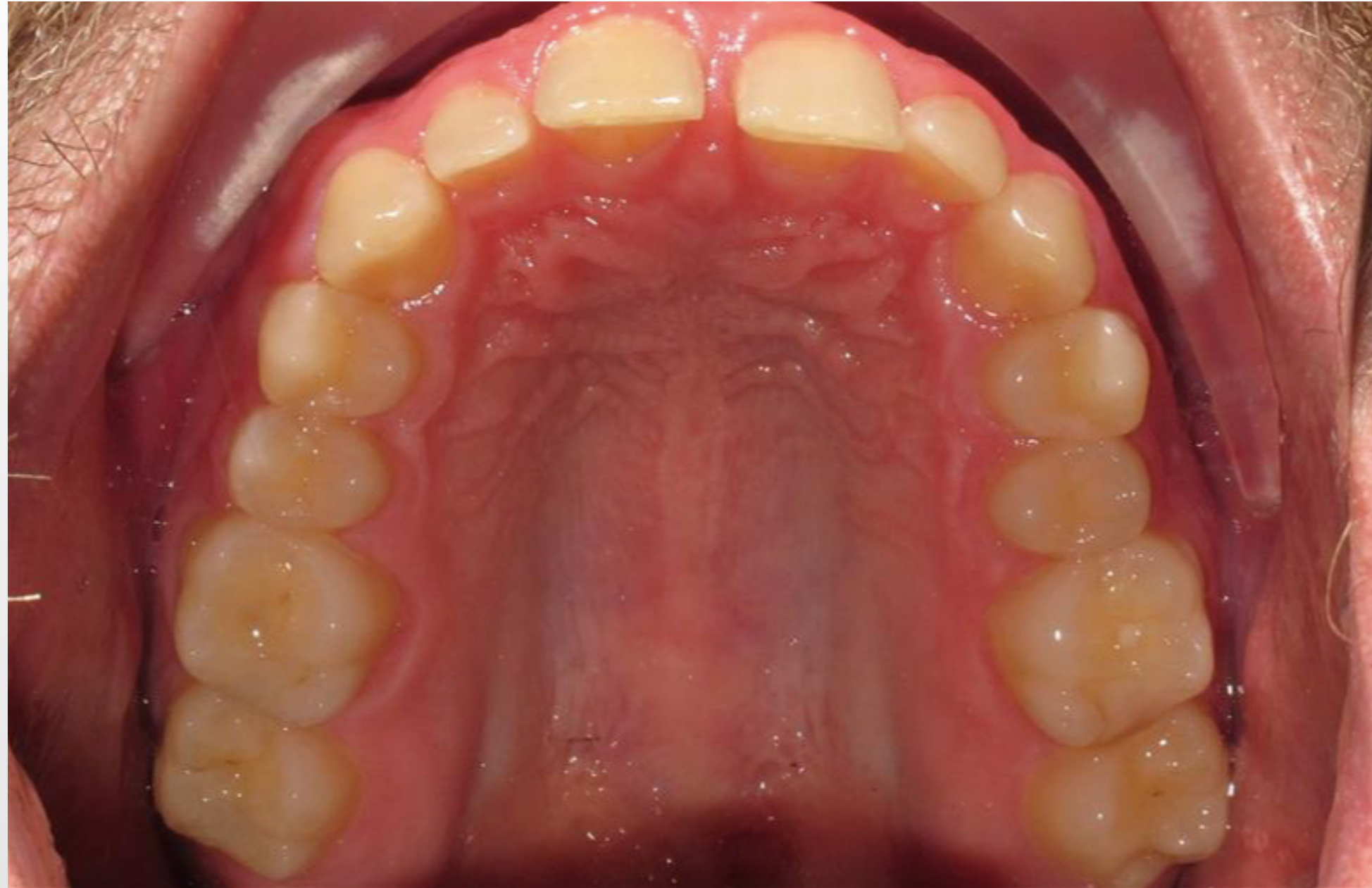**Face smiling**



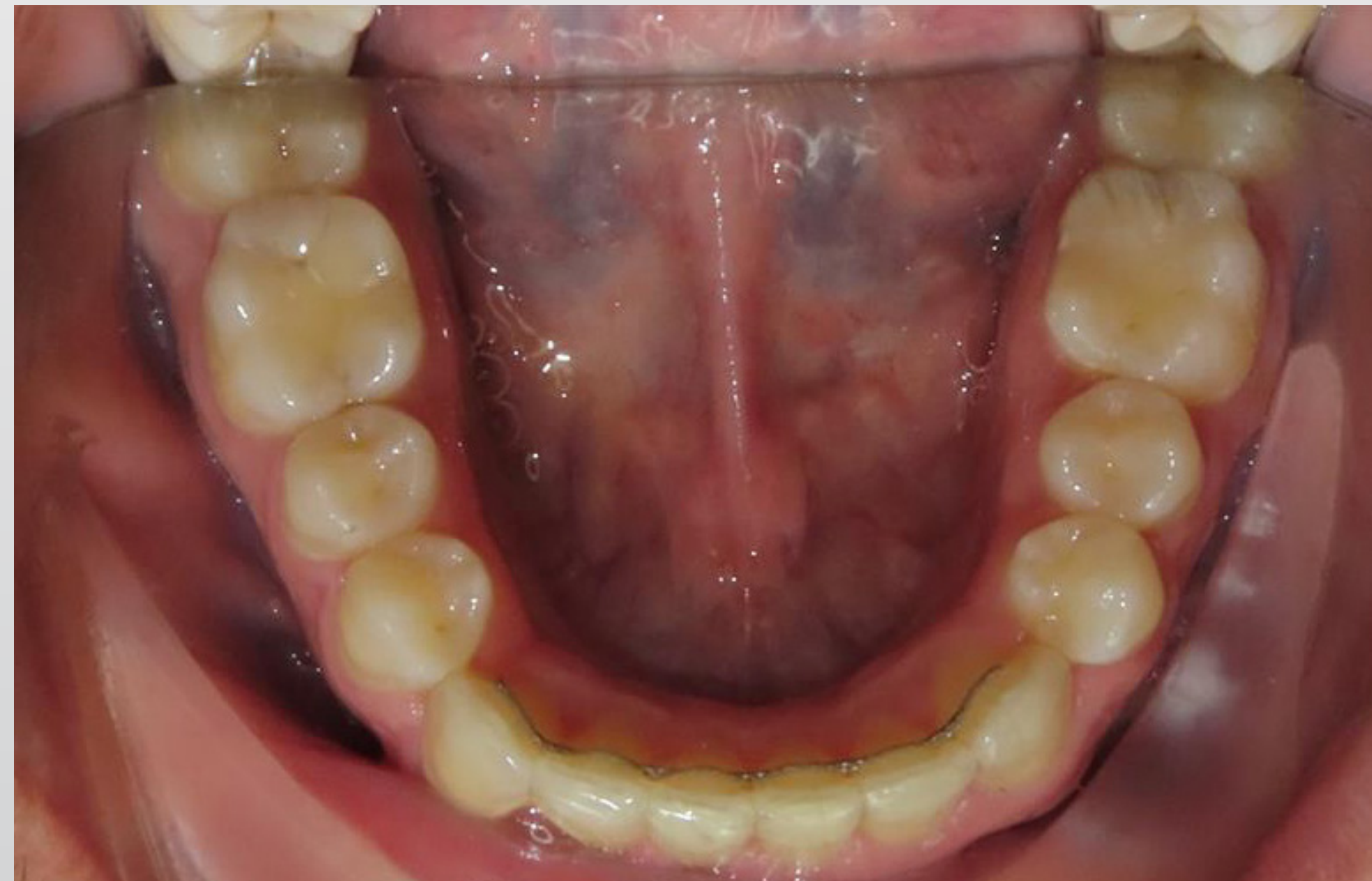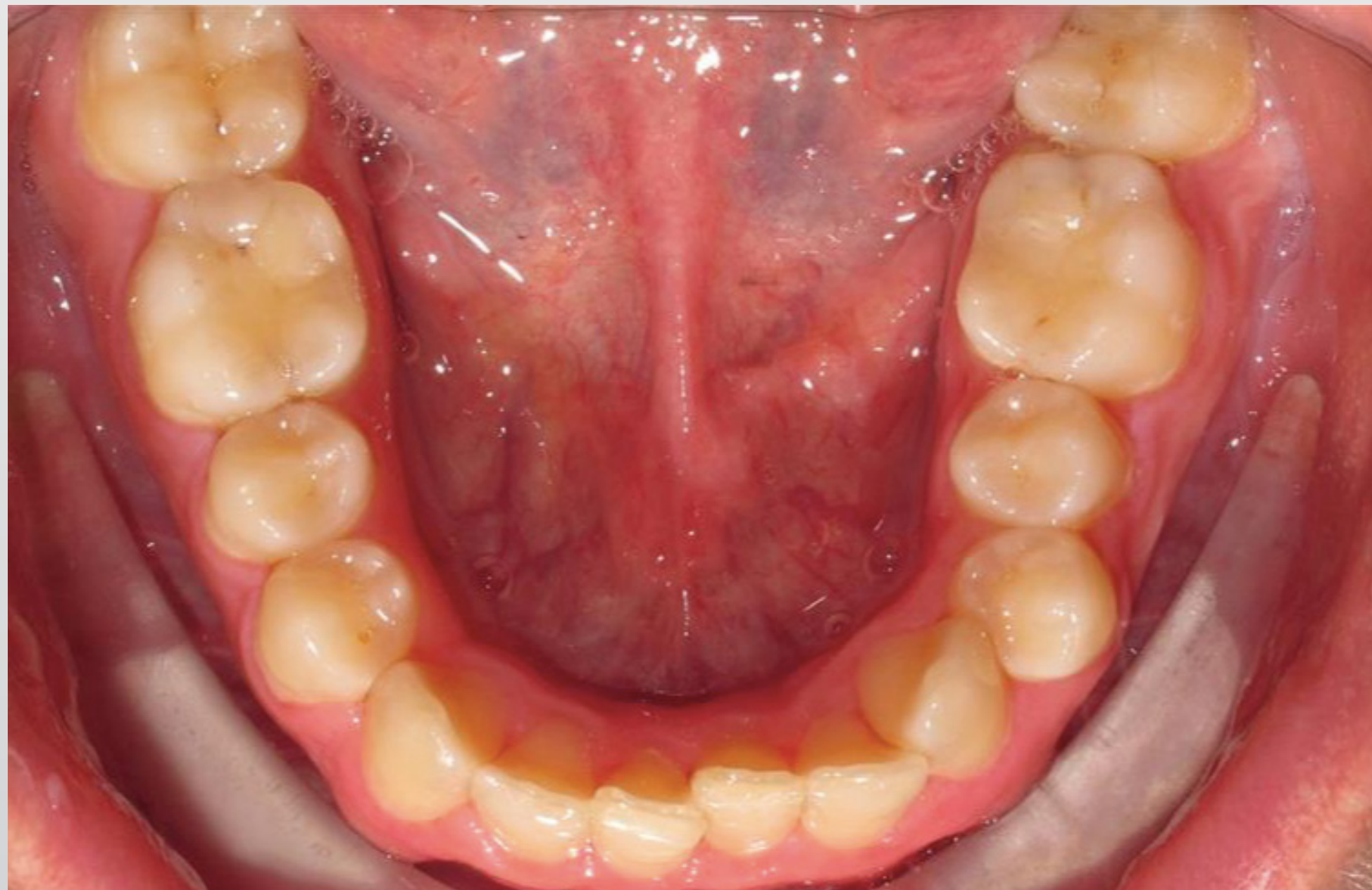
**Initial**

**Final**

**Occlusal –  
maxillary**



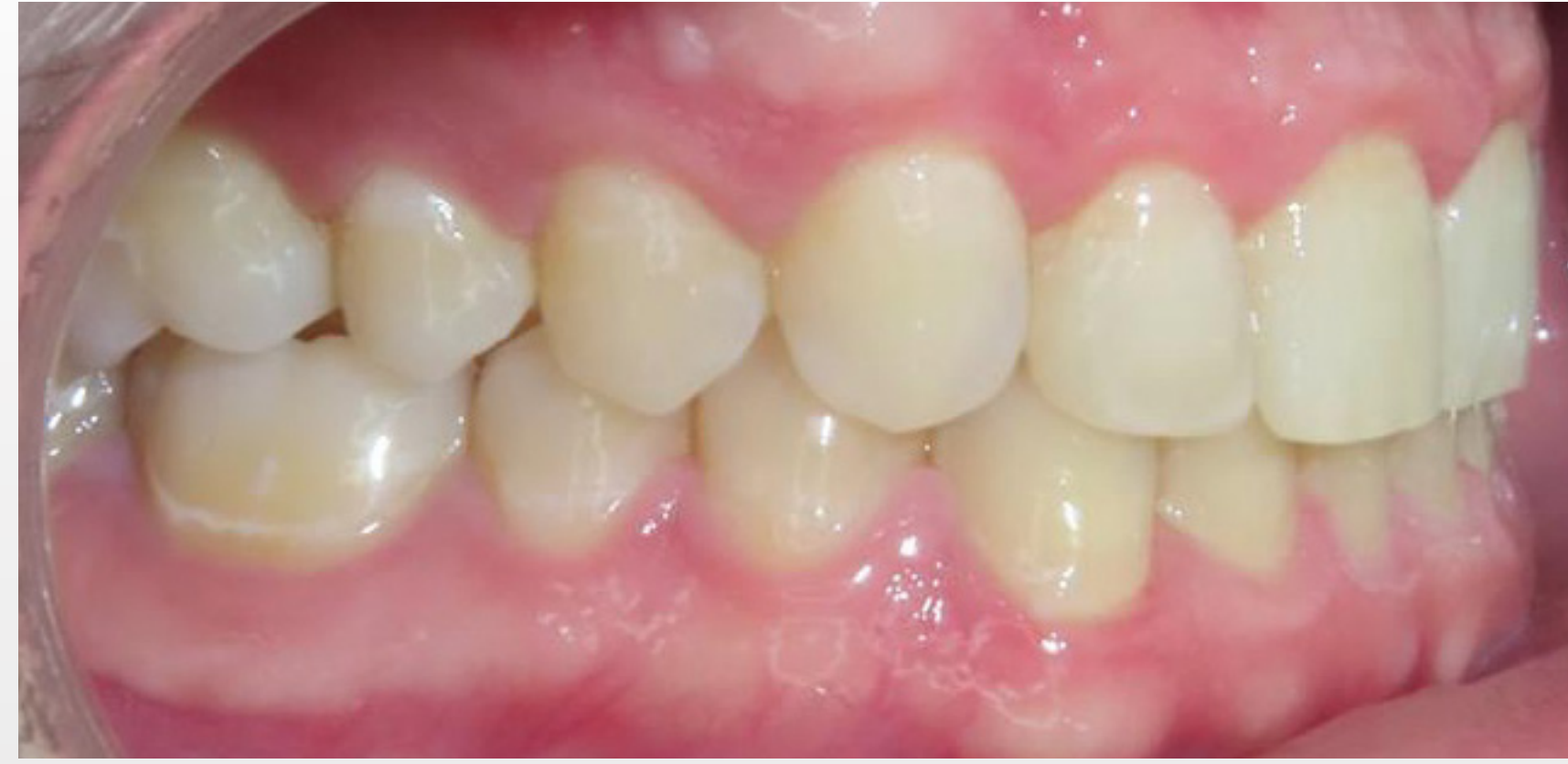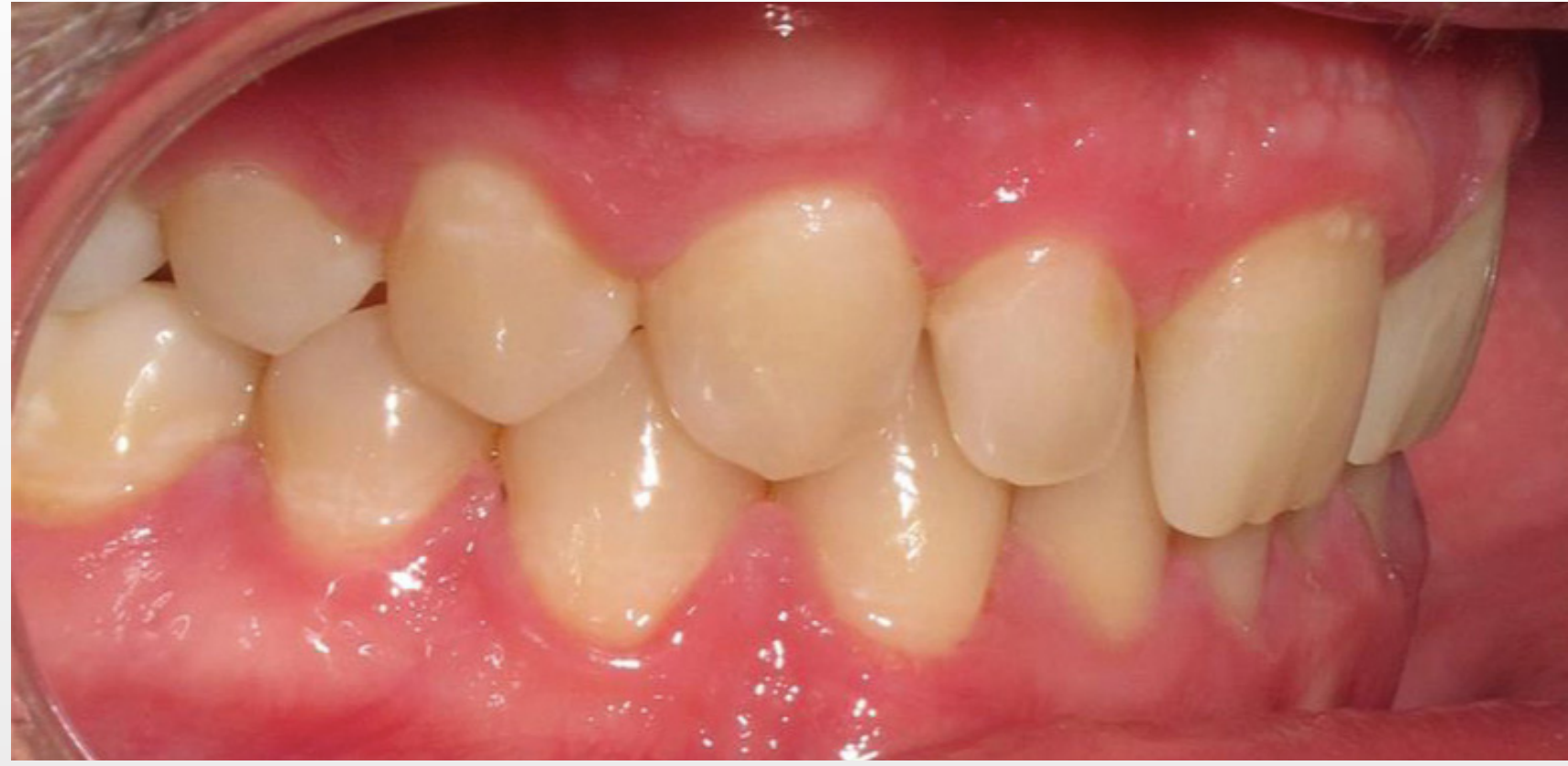**Occlusal –  
mandibular**



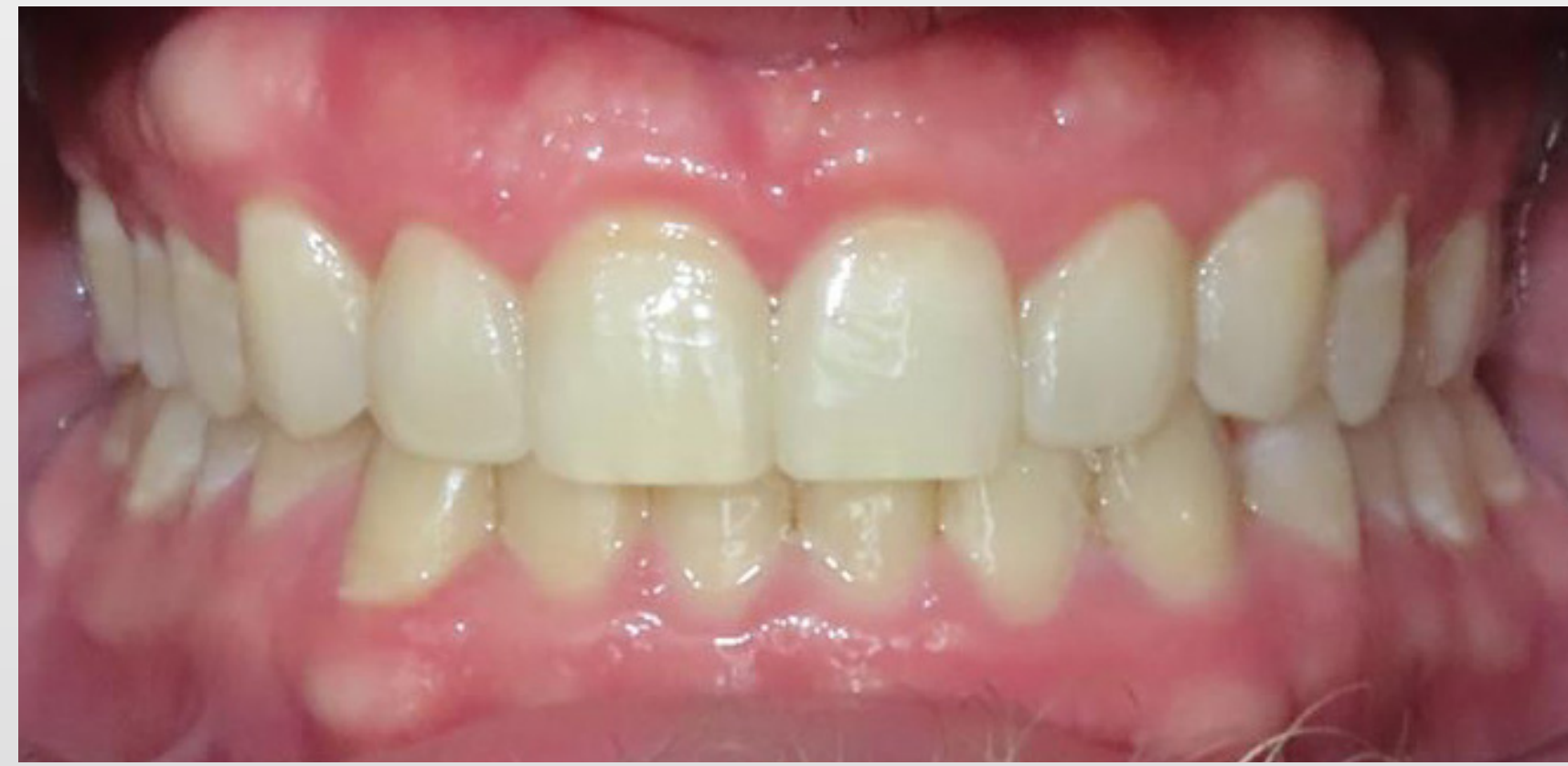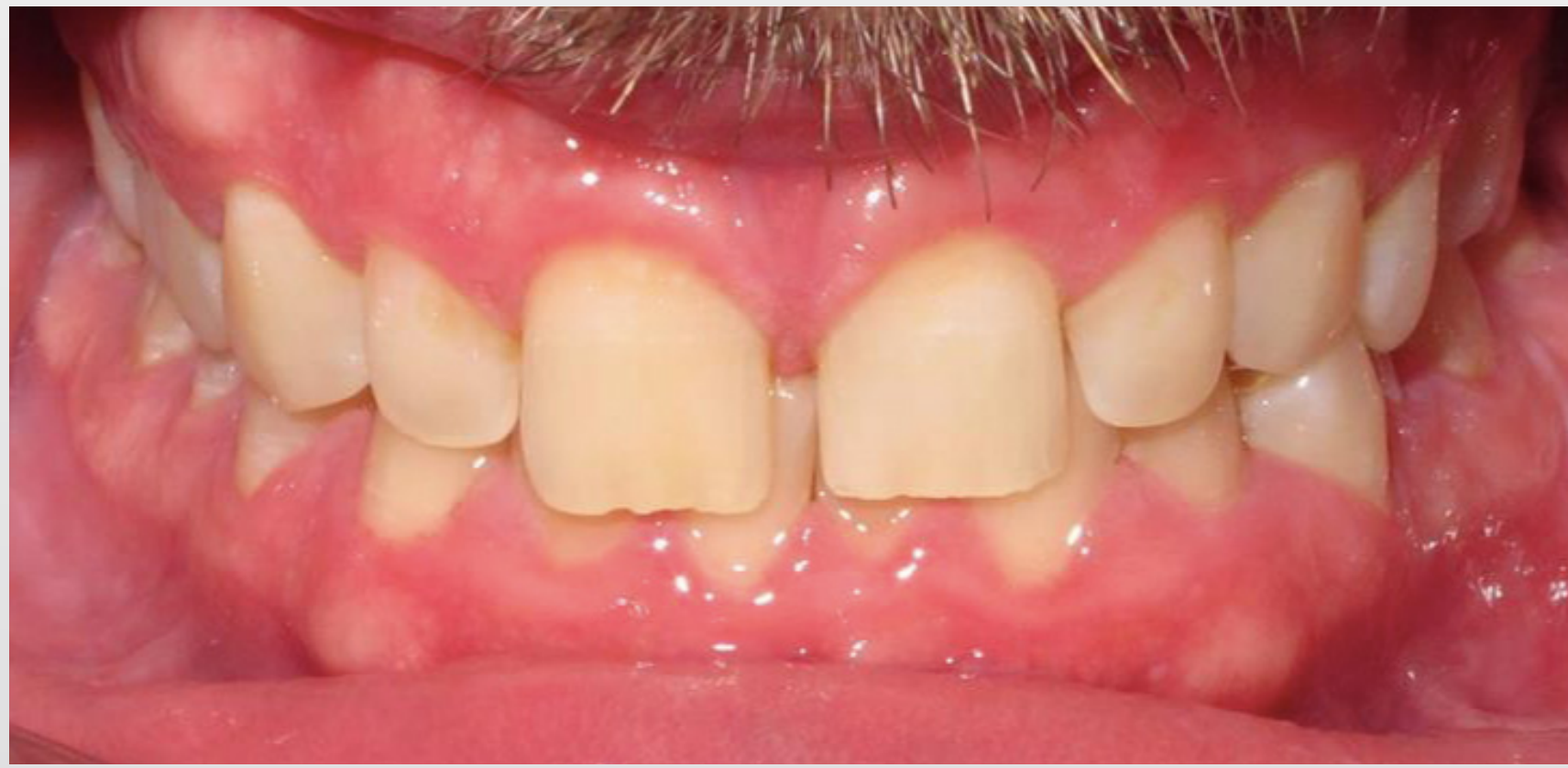**Initial**

**Final**

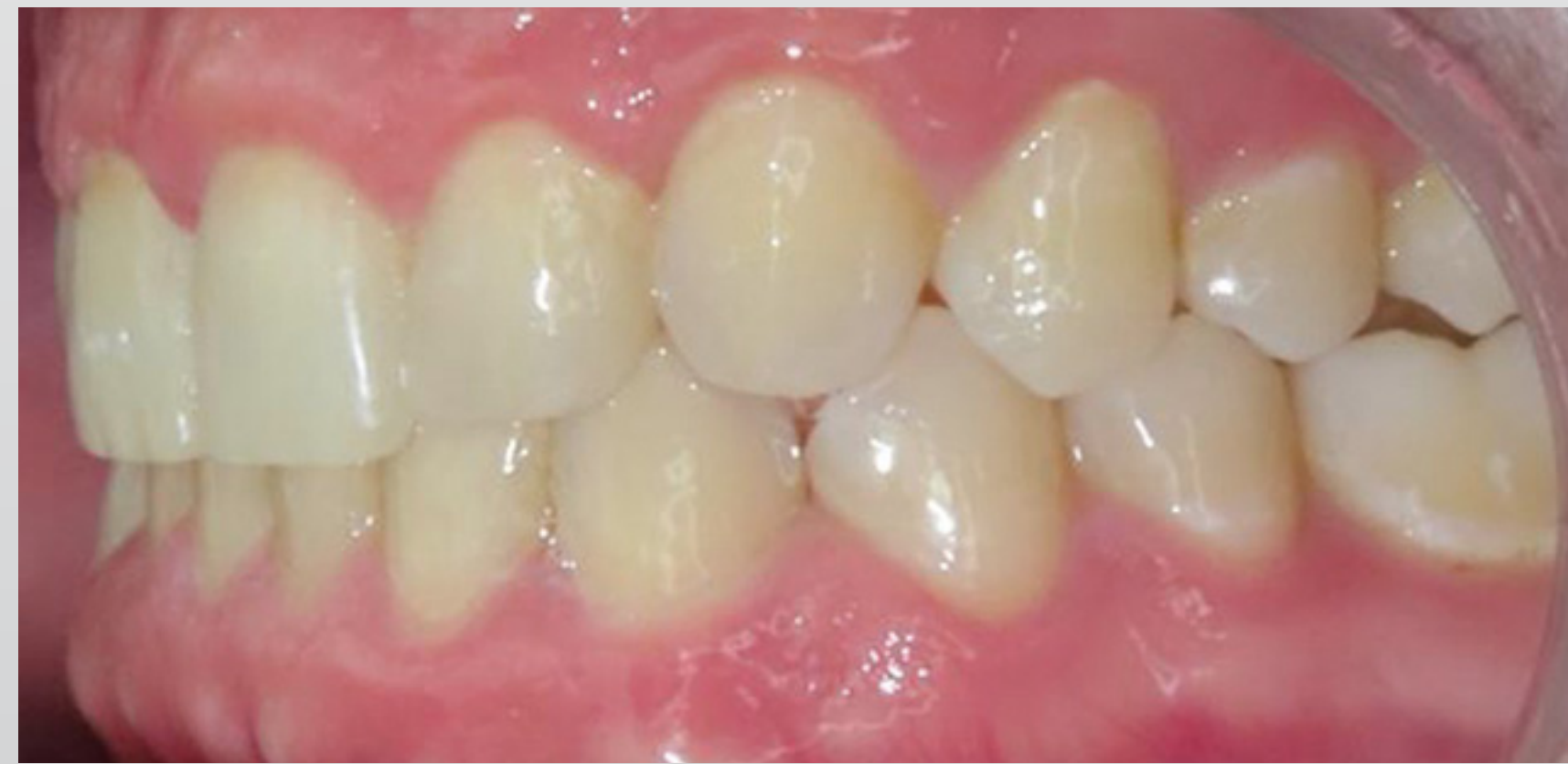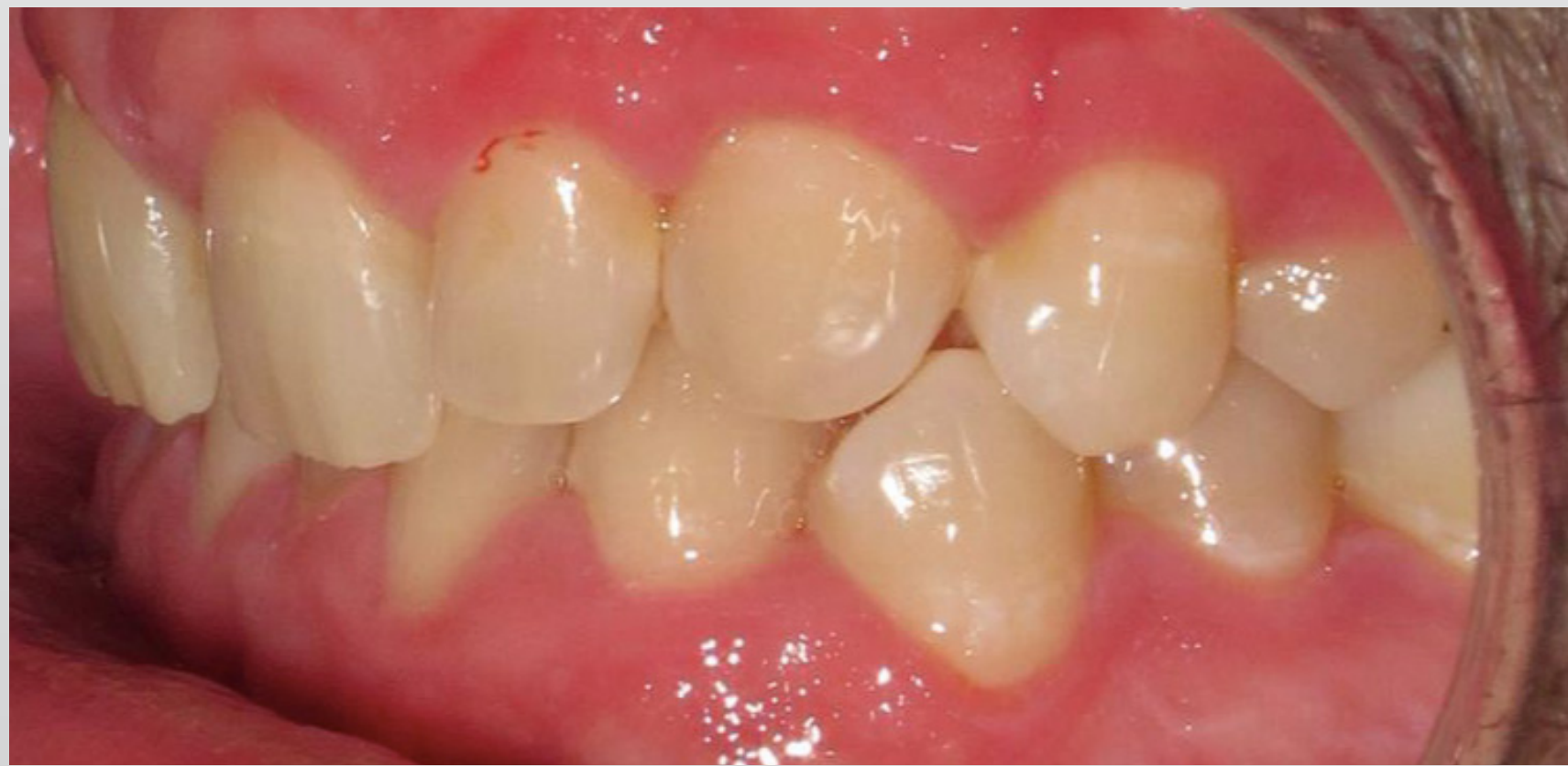**Retracted  
buccal – right**



**Retracted  
anterior biting**



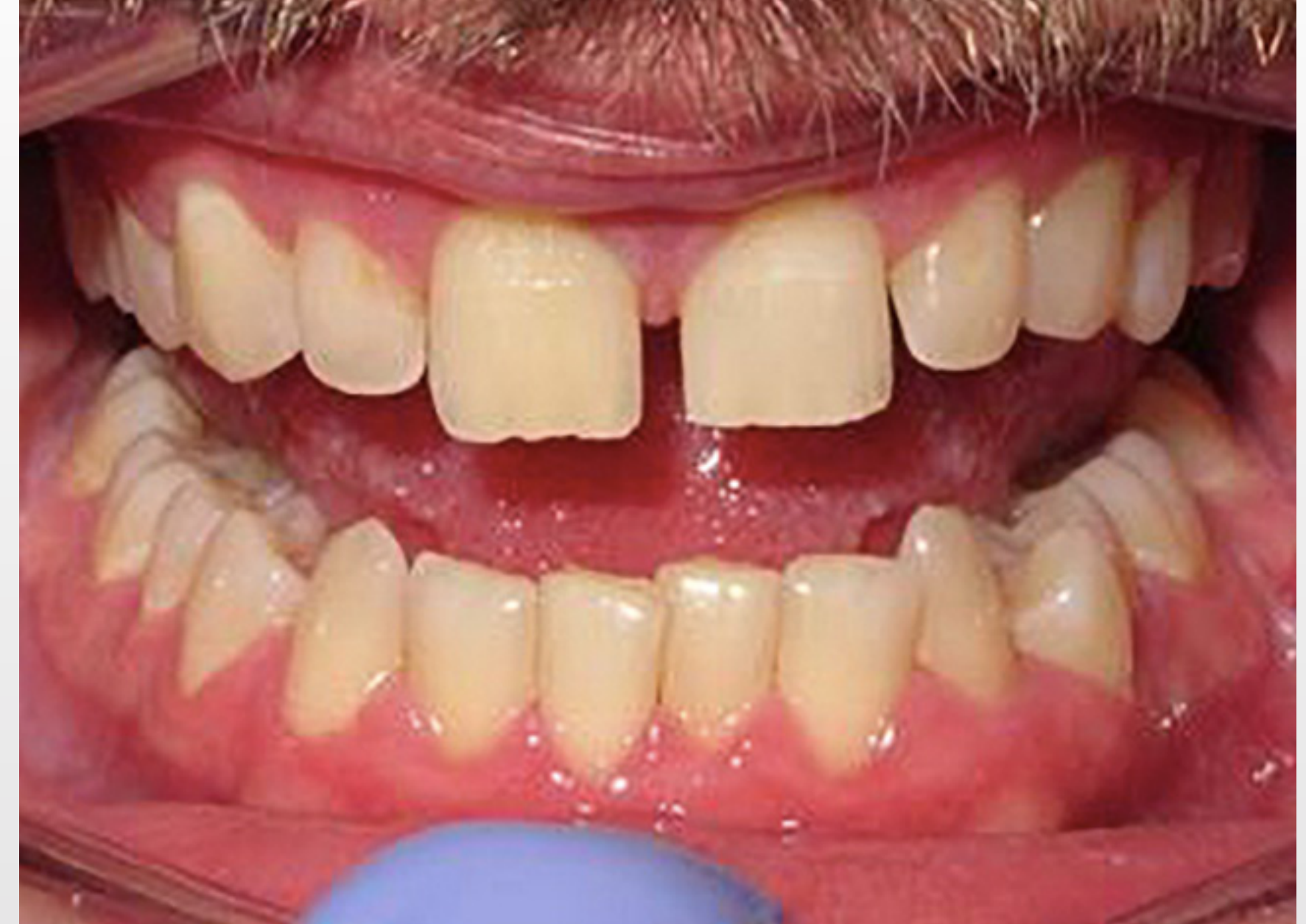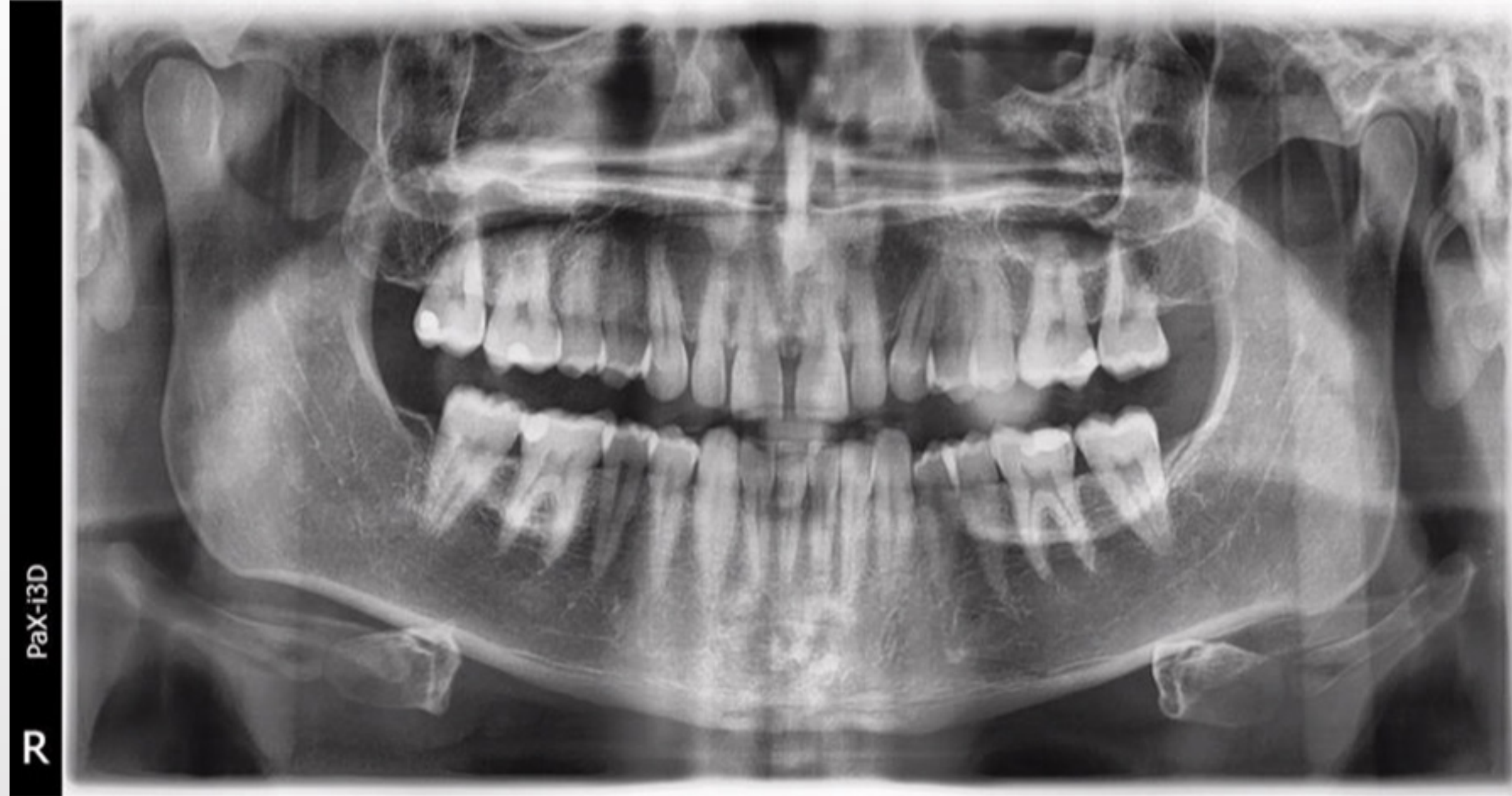**Retracted  
buccal – left**



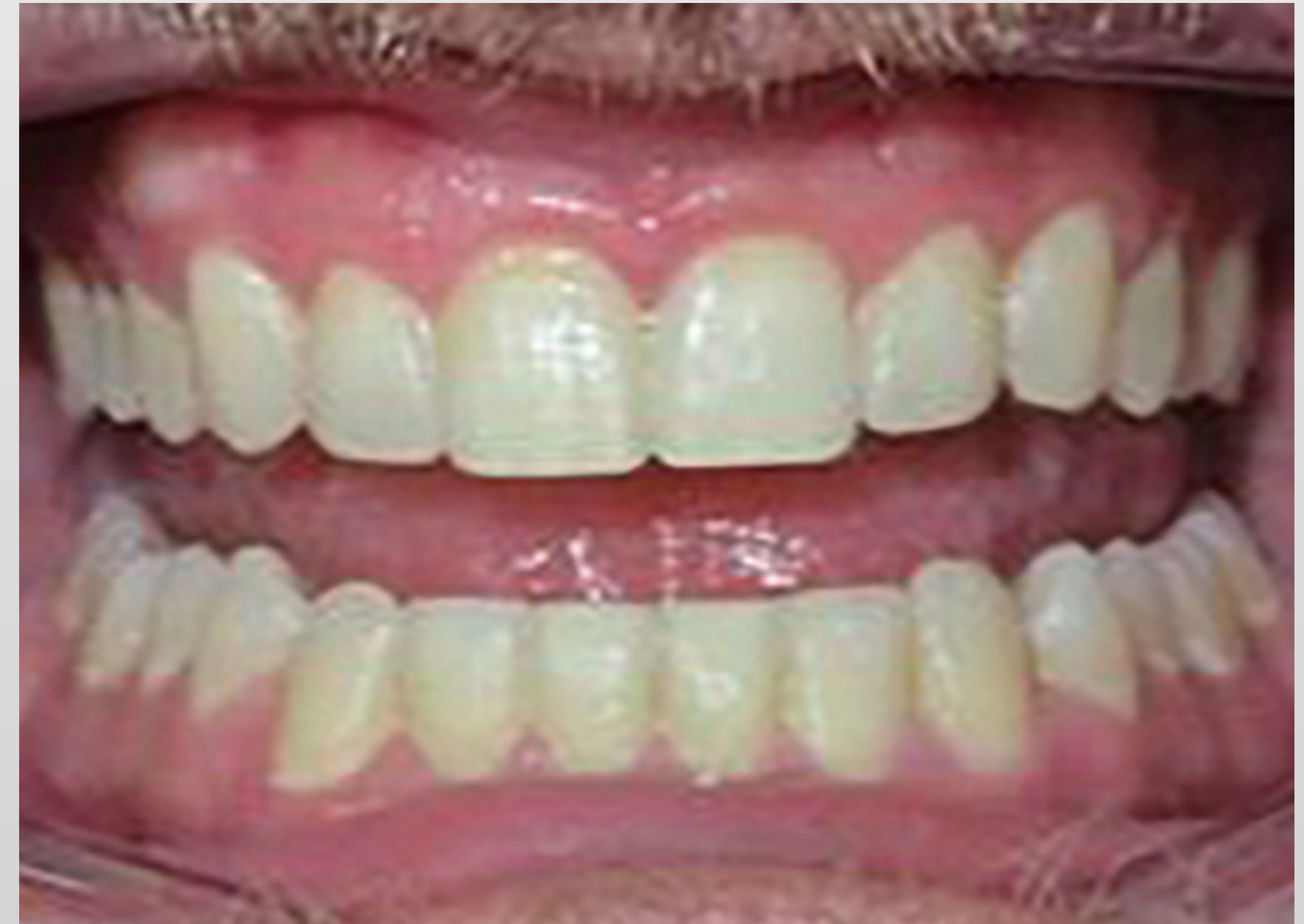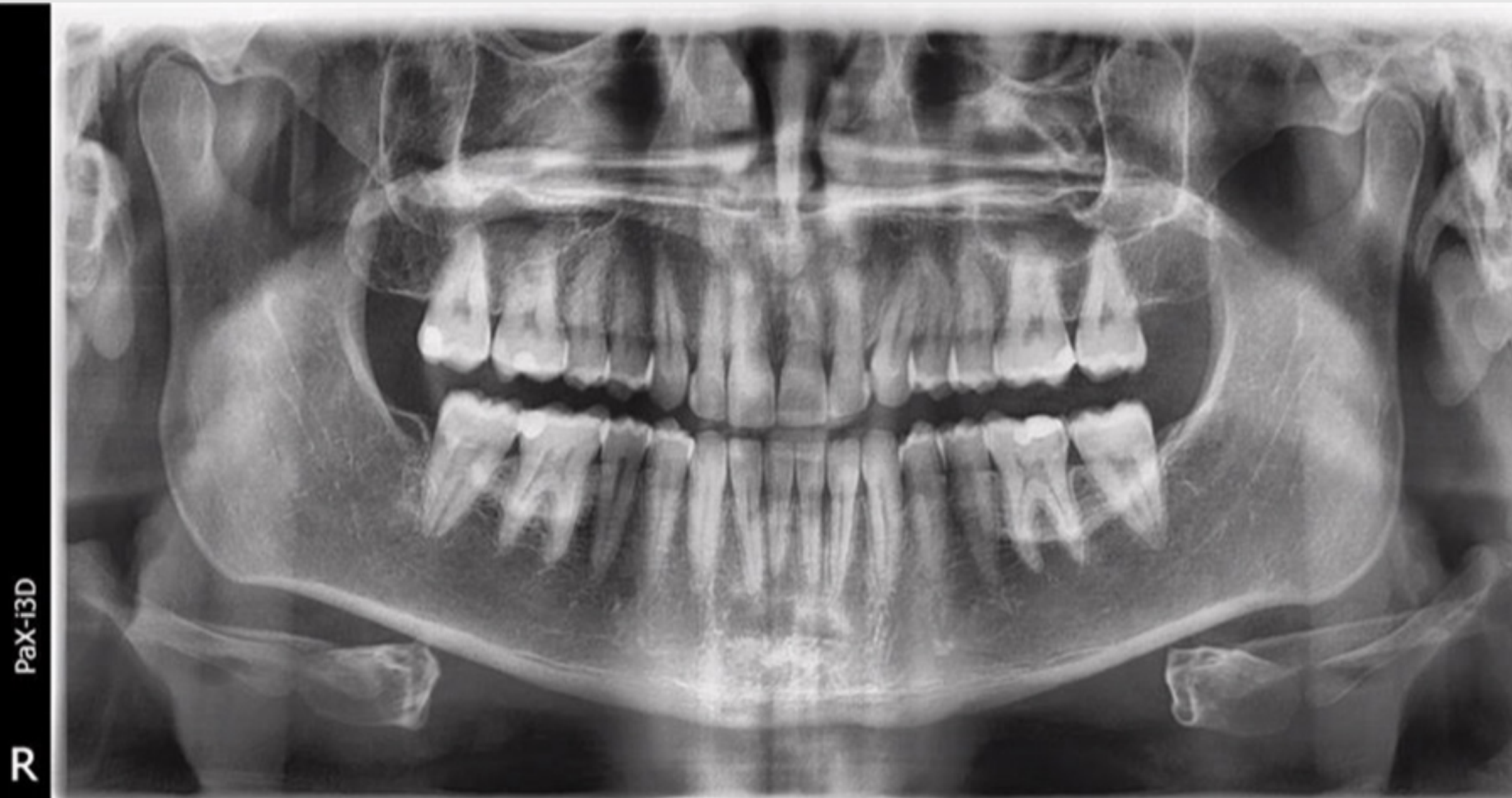Panoramic radiograph

Open

Initial



Final



## **Tx Design Video**

Treatment Plan  
Attachment Strategy  
Key Movements  
Summary of Final Results

**Best Fit Overlay**

