

Case Study: 3M™ Clarity™ Aligners

Anterior crossbite with deep bite.

Age: 13

Chief concern: “The underbite”

Case diagnostics:

Retrognathic maxilla/orthognathic mandible, Class III tendency, mild maxillary crowding, moderate mandibular spacing, deep overbite ~60%, negative overjet and complete anterior crossbite, supernumerary lower left premolar, fair to poor oral hygiene, and some sensory issues

Total number of aligners: 48

Initial Tx Design: stages 1-40 (40 aligners)

Refinement Tx Design: stages 41-48 (8 aligners)

Aligner Material: 3M™ Clarity™ Aligners Force

Wear interval: 7 days

Treatment time: 13 months

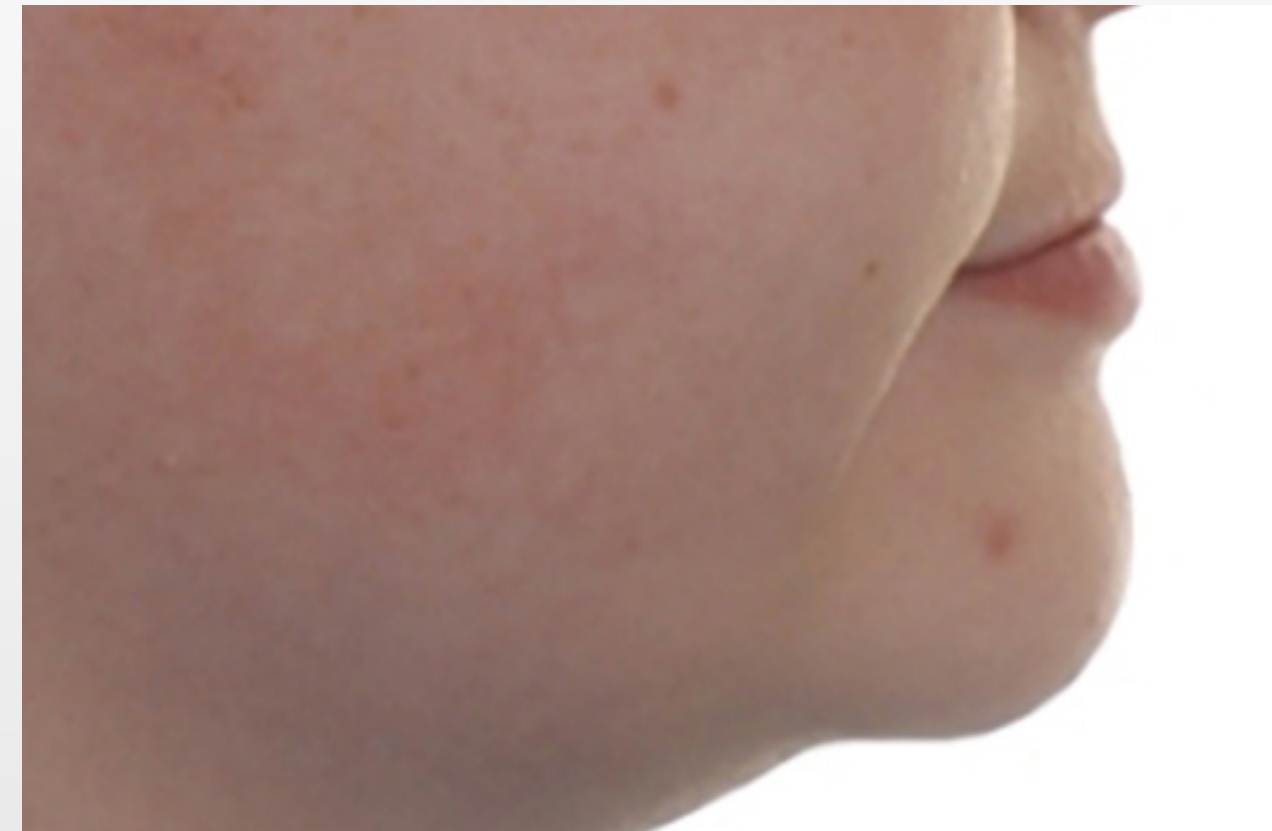Case courtesy of:

Dr. Matt Dunn
Scottsdale, AZ – USA

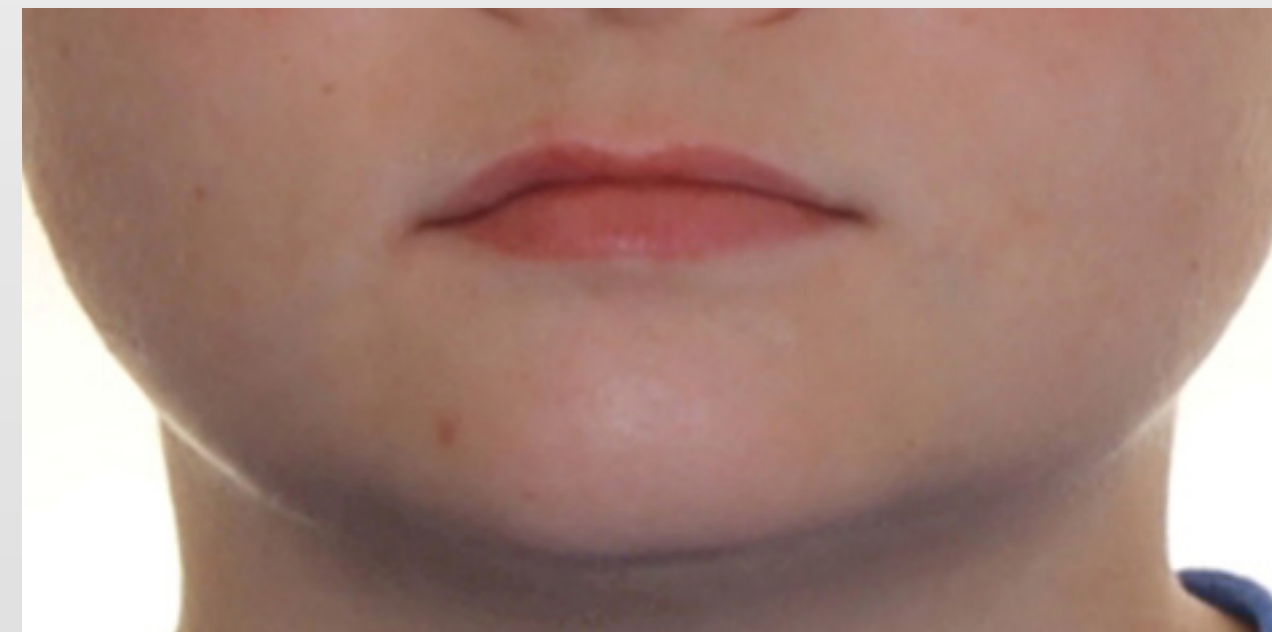
Initial

Final

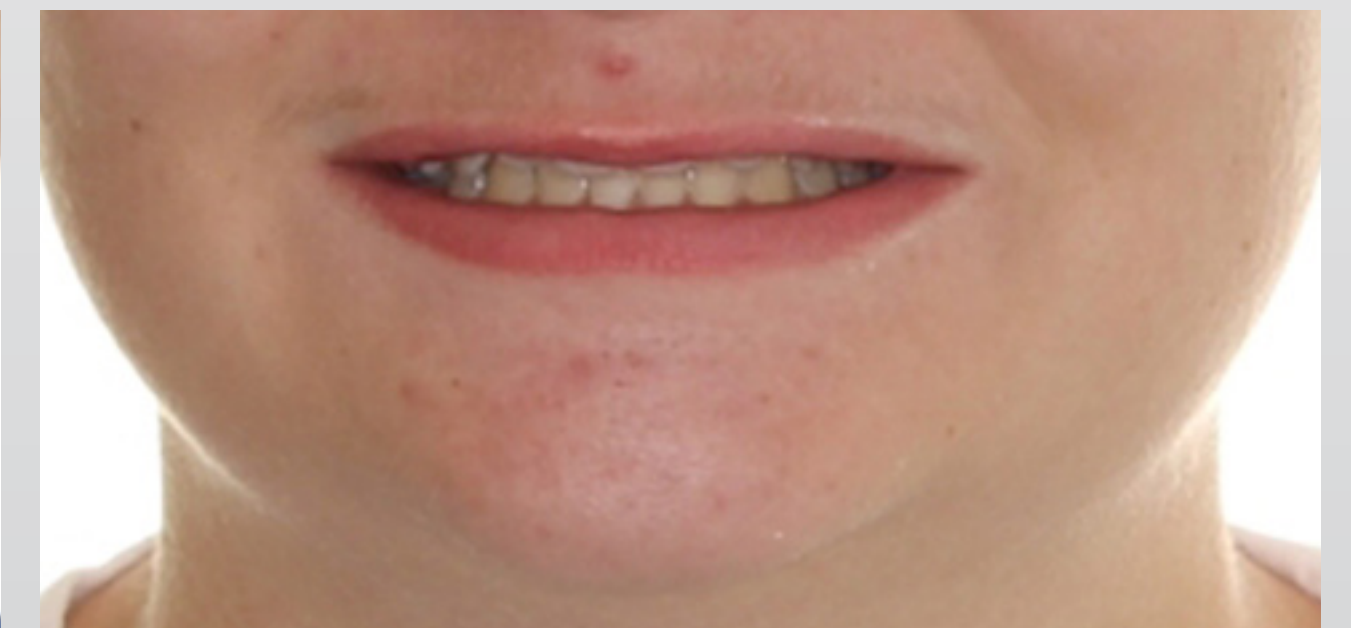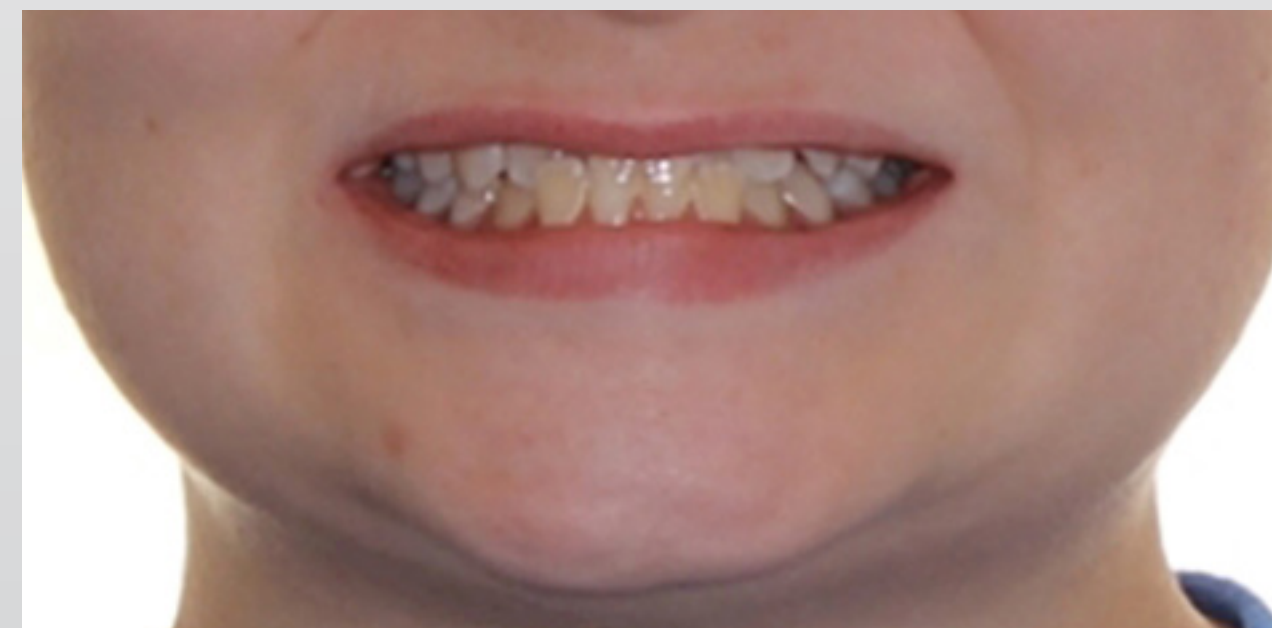Profile at rest



Face at rest



Face smiling

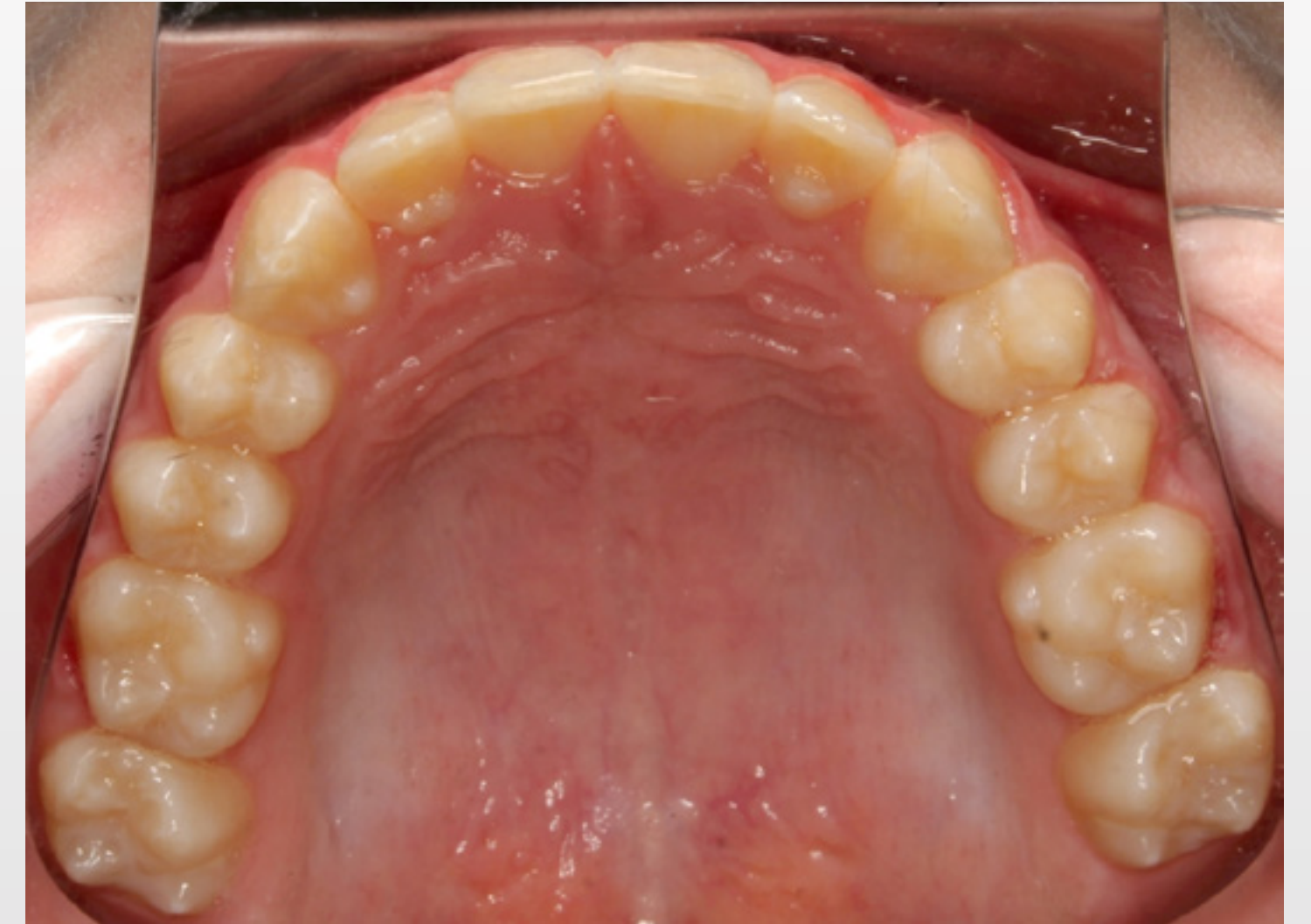
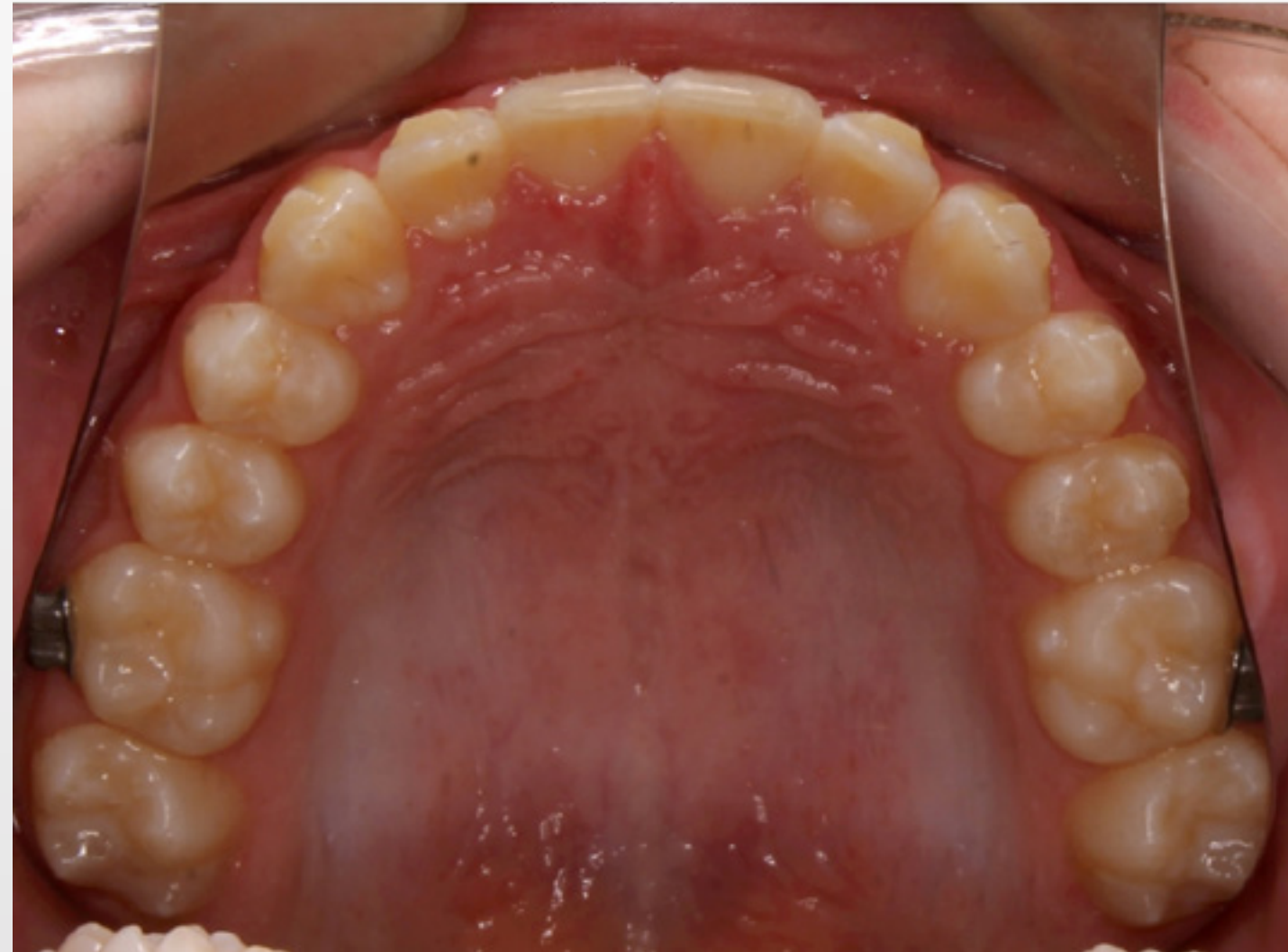
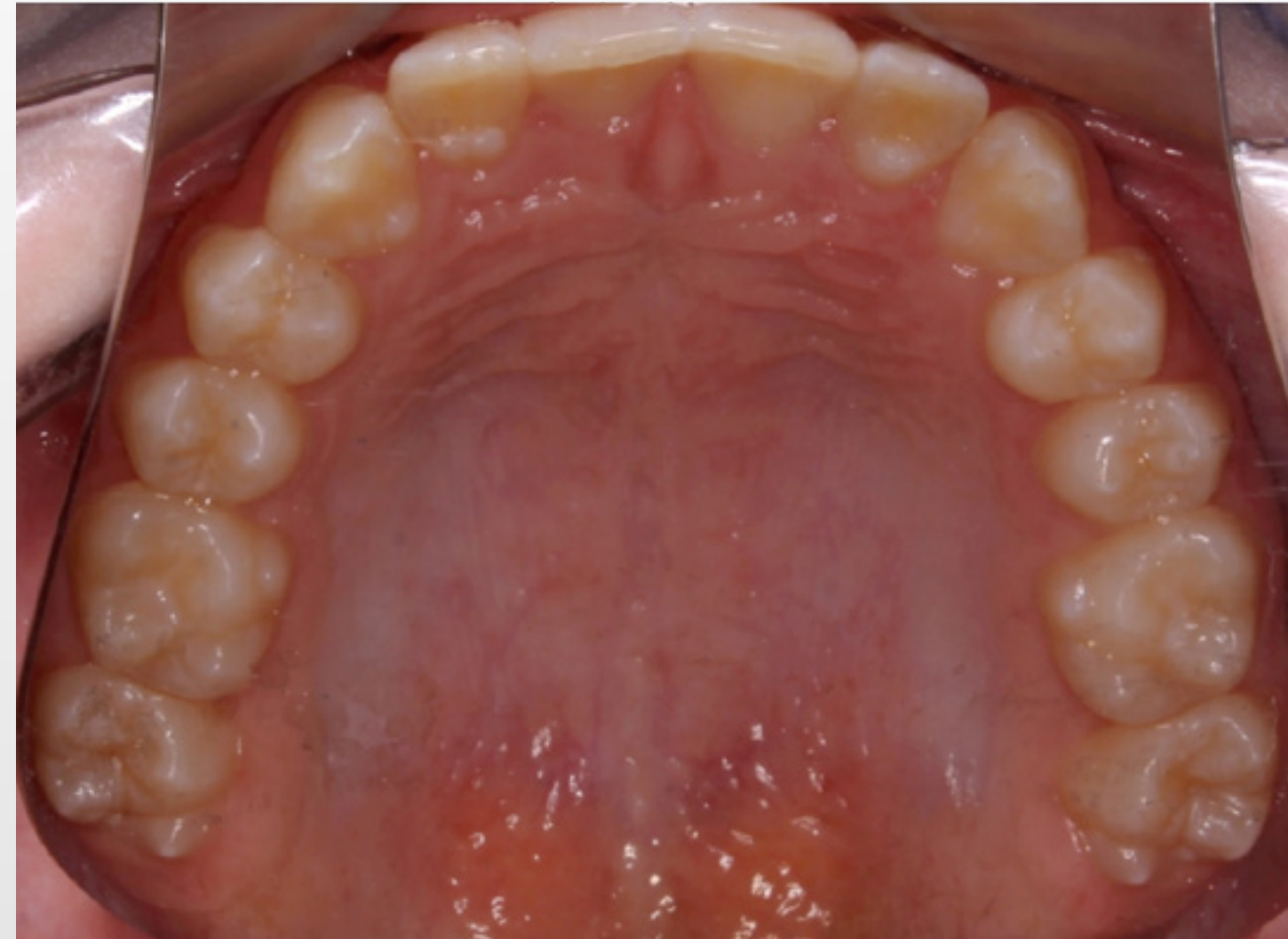
Initial

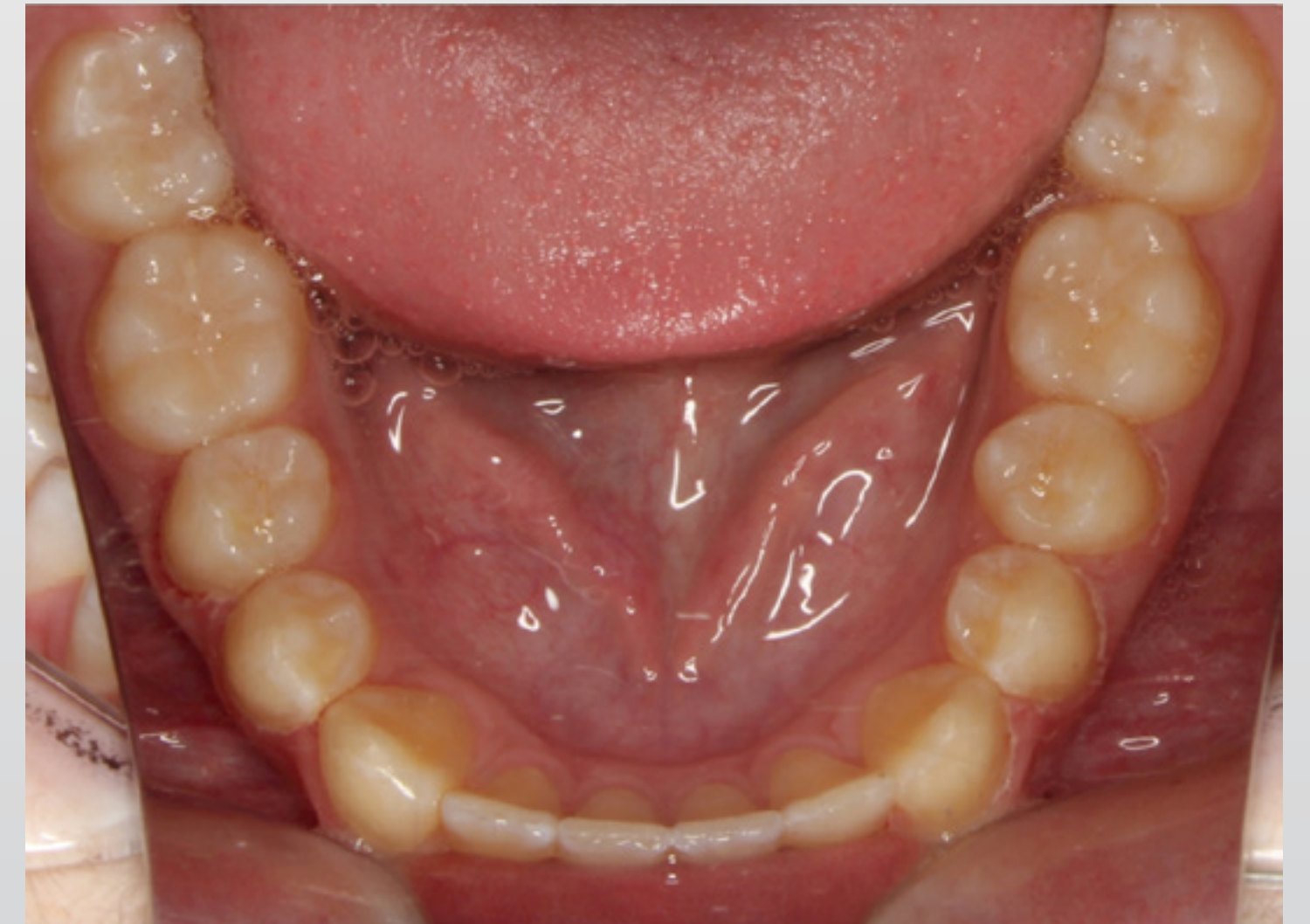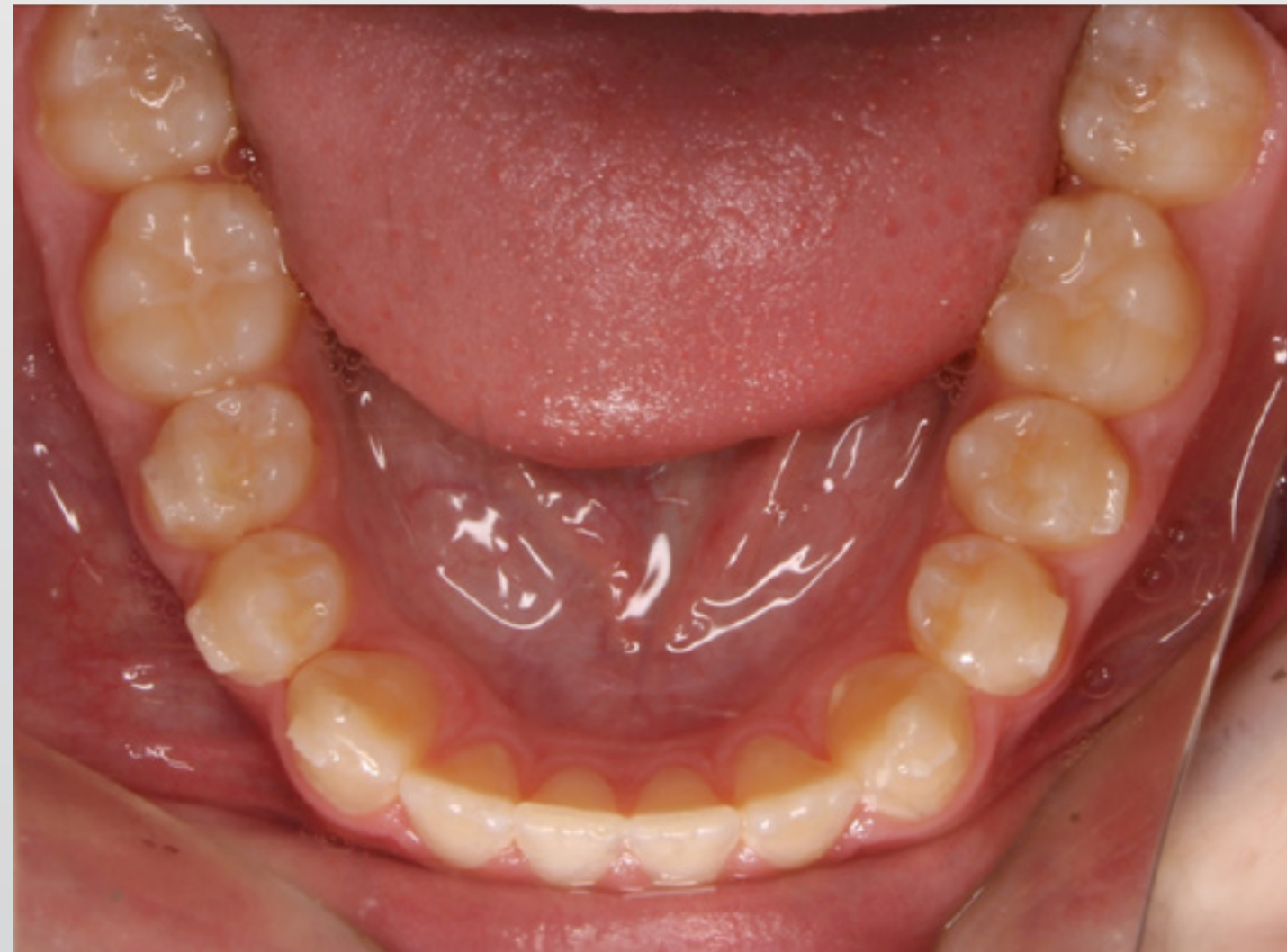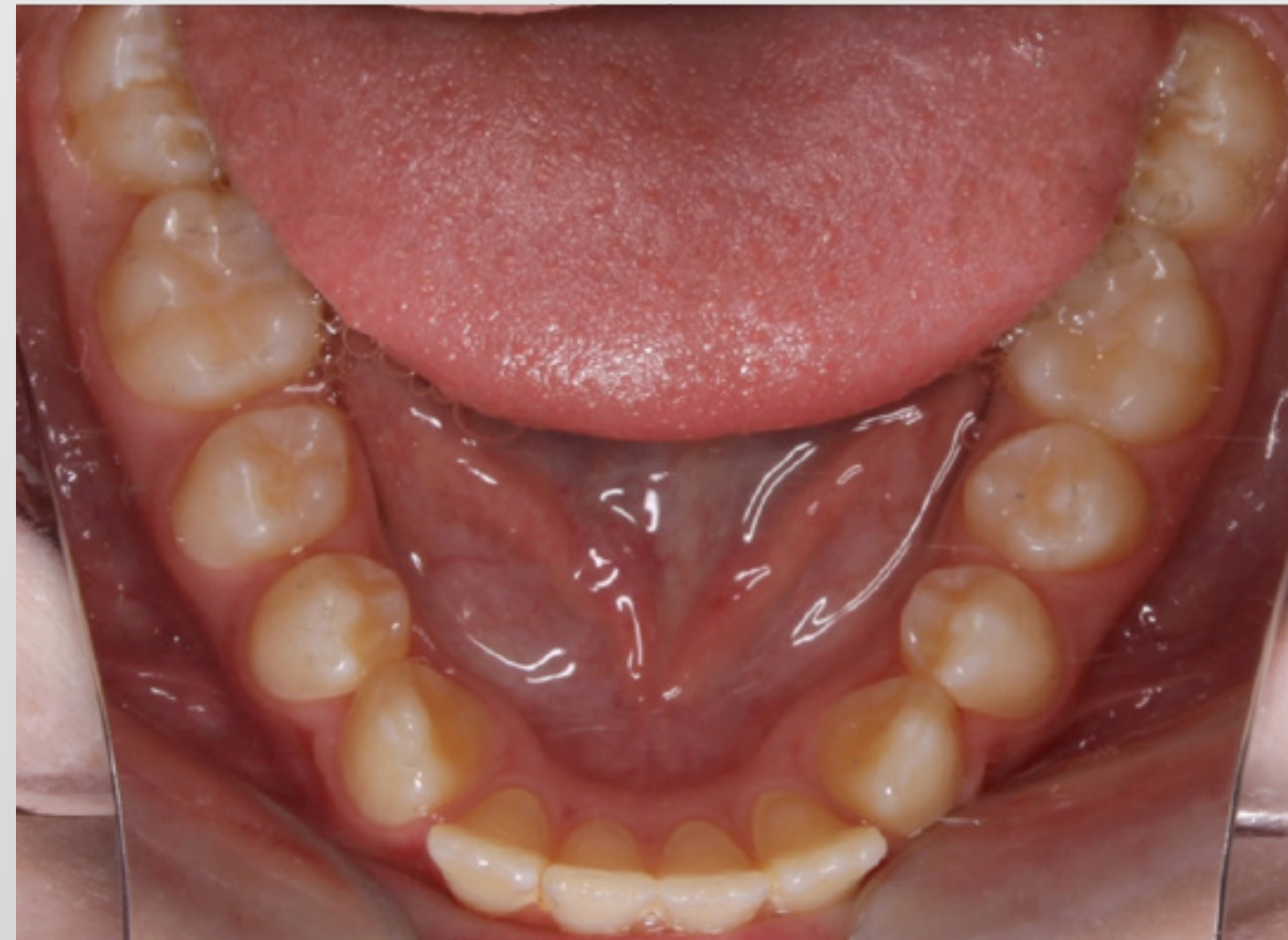Progress - Aligner 40

Final

**Occlusal –
maxillary**



**Occlusal –
mandibular**

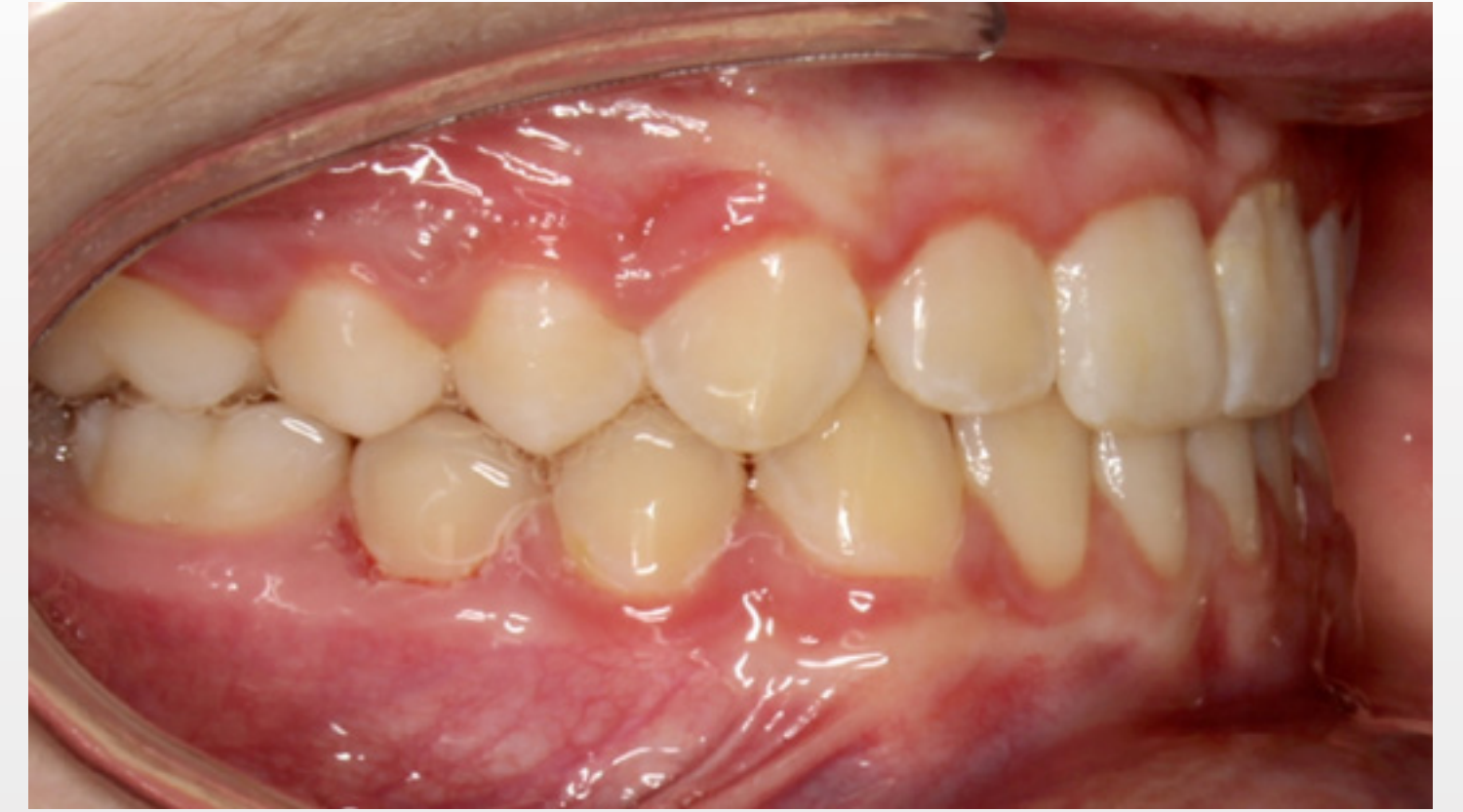
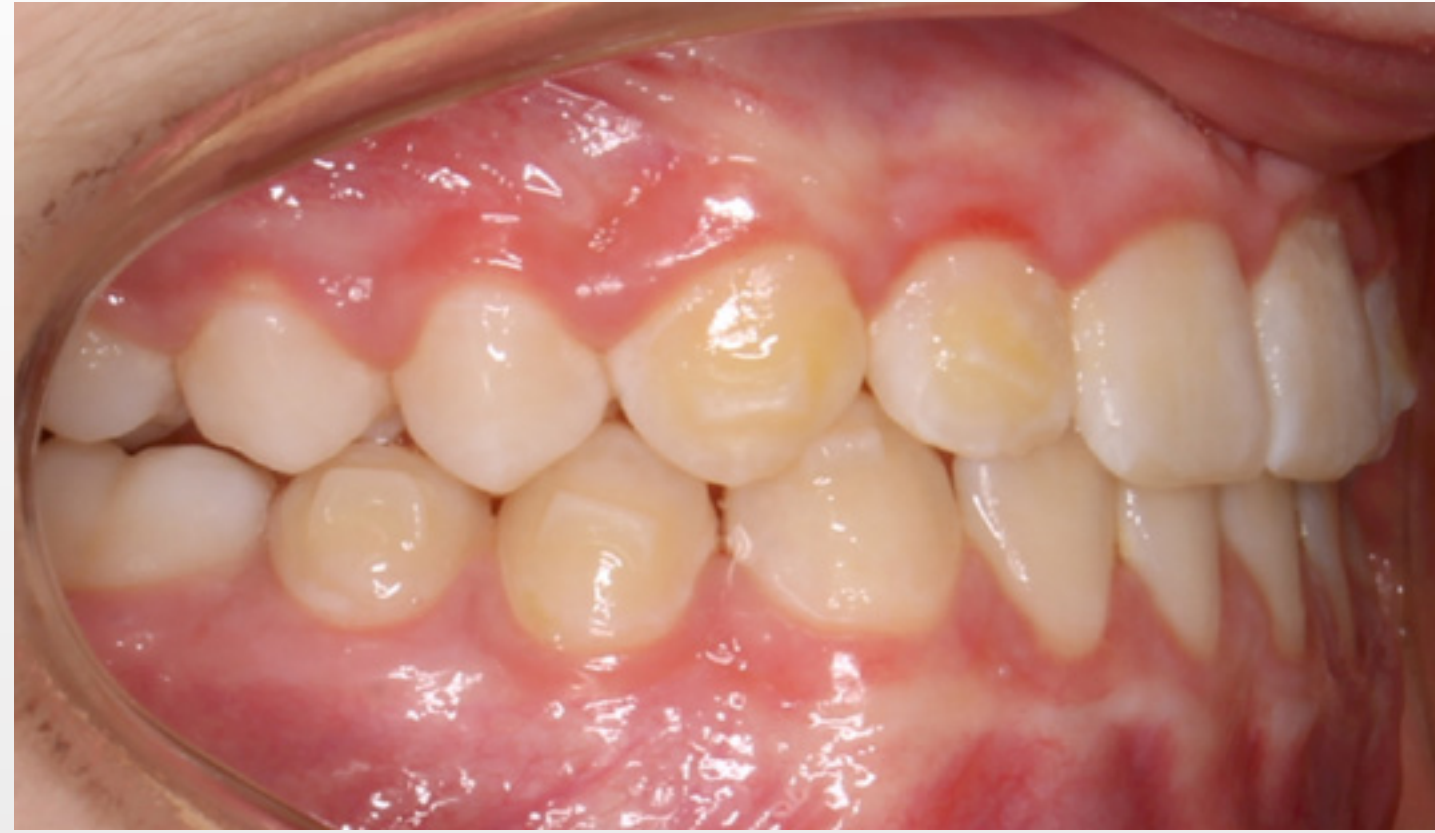
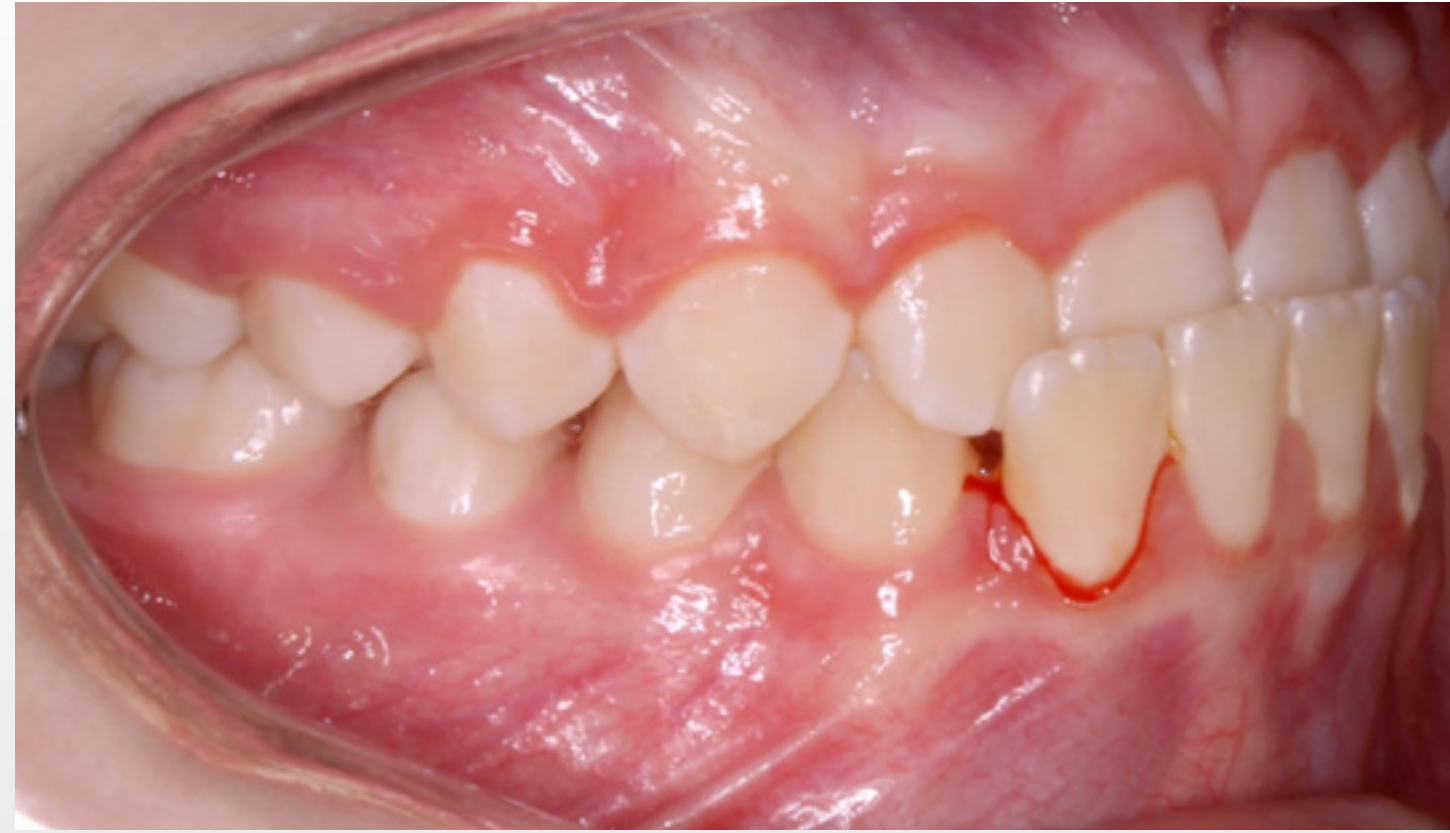Initial

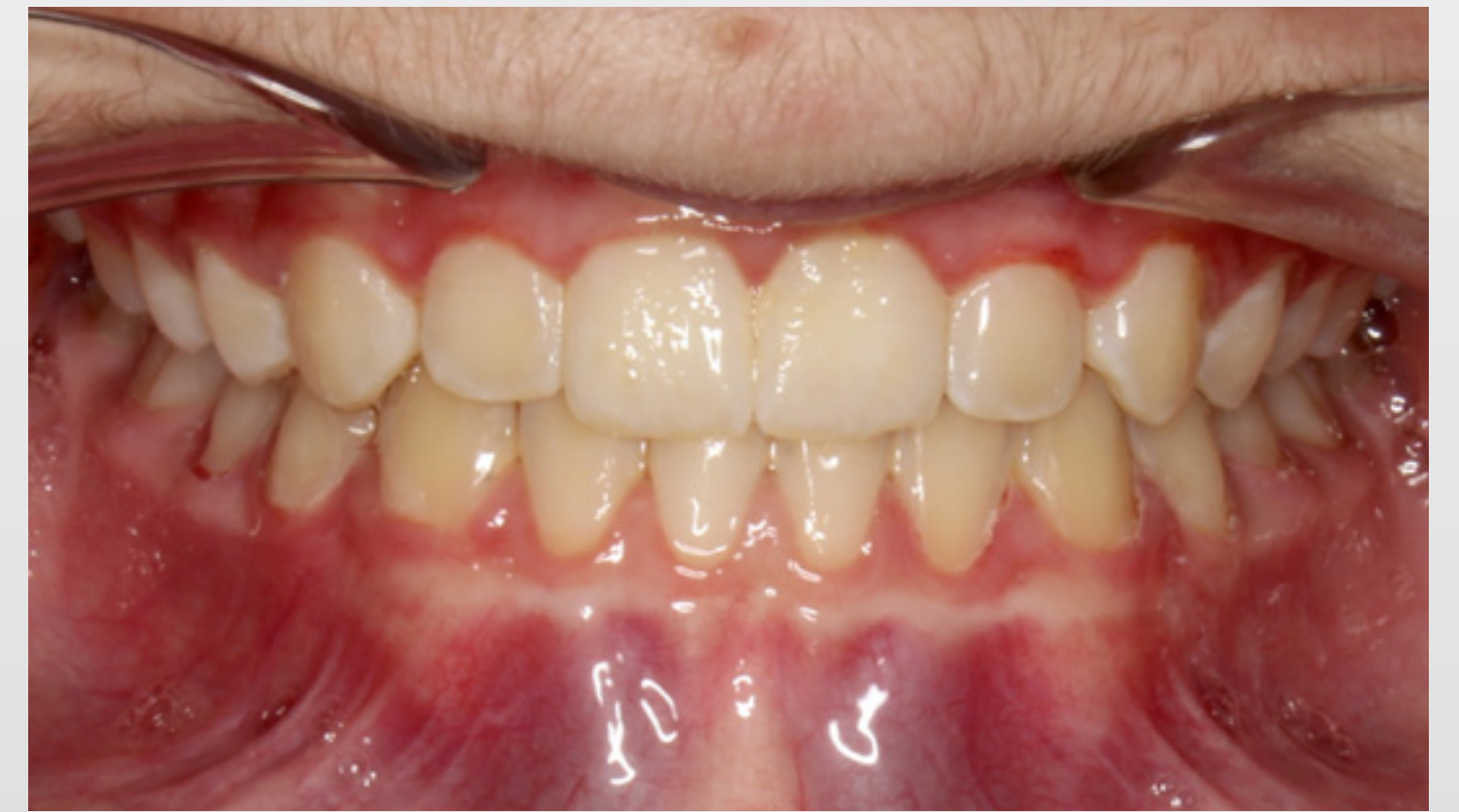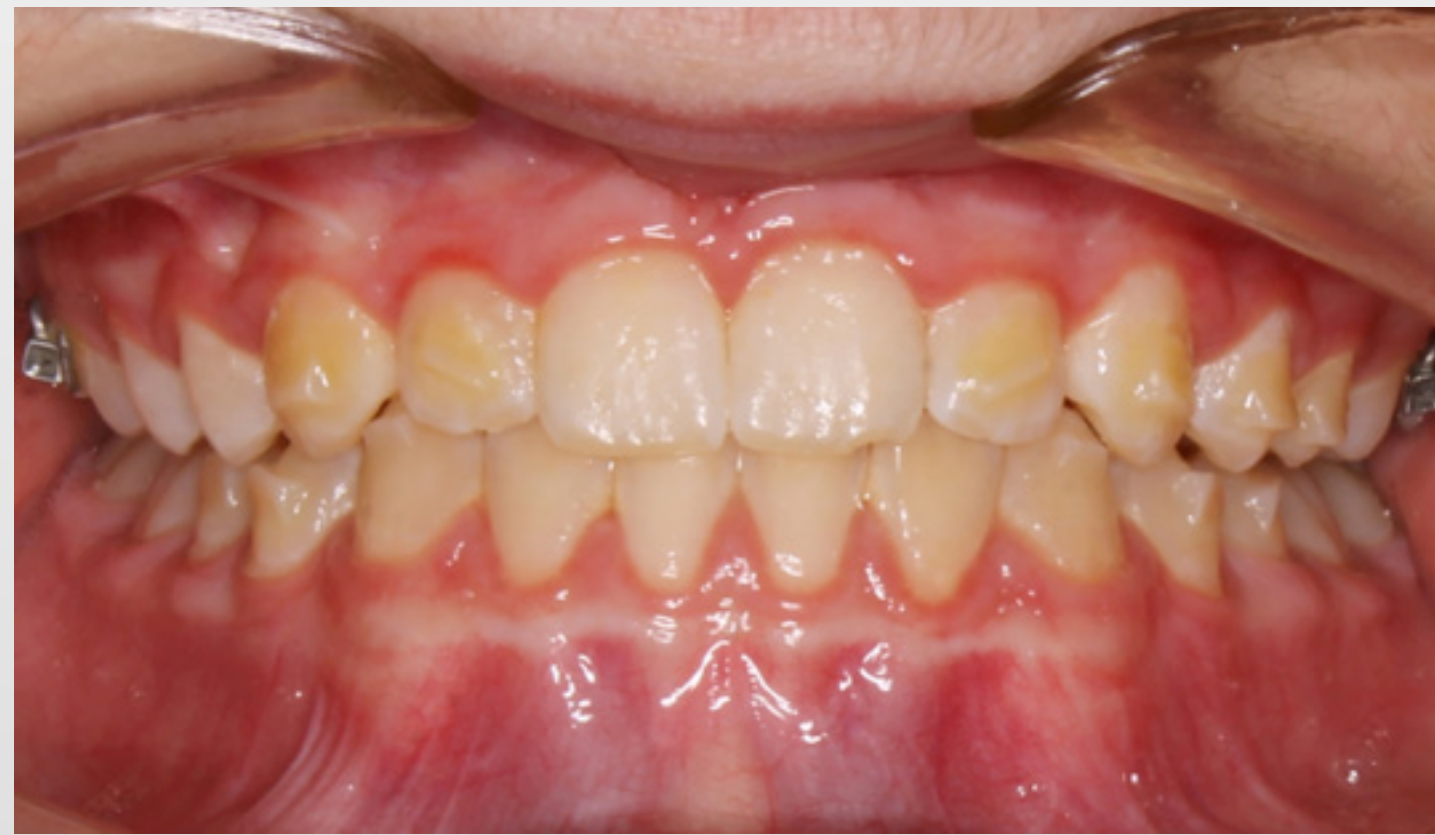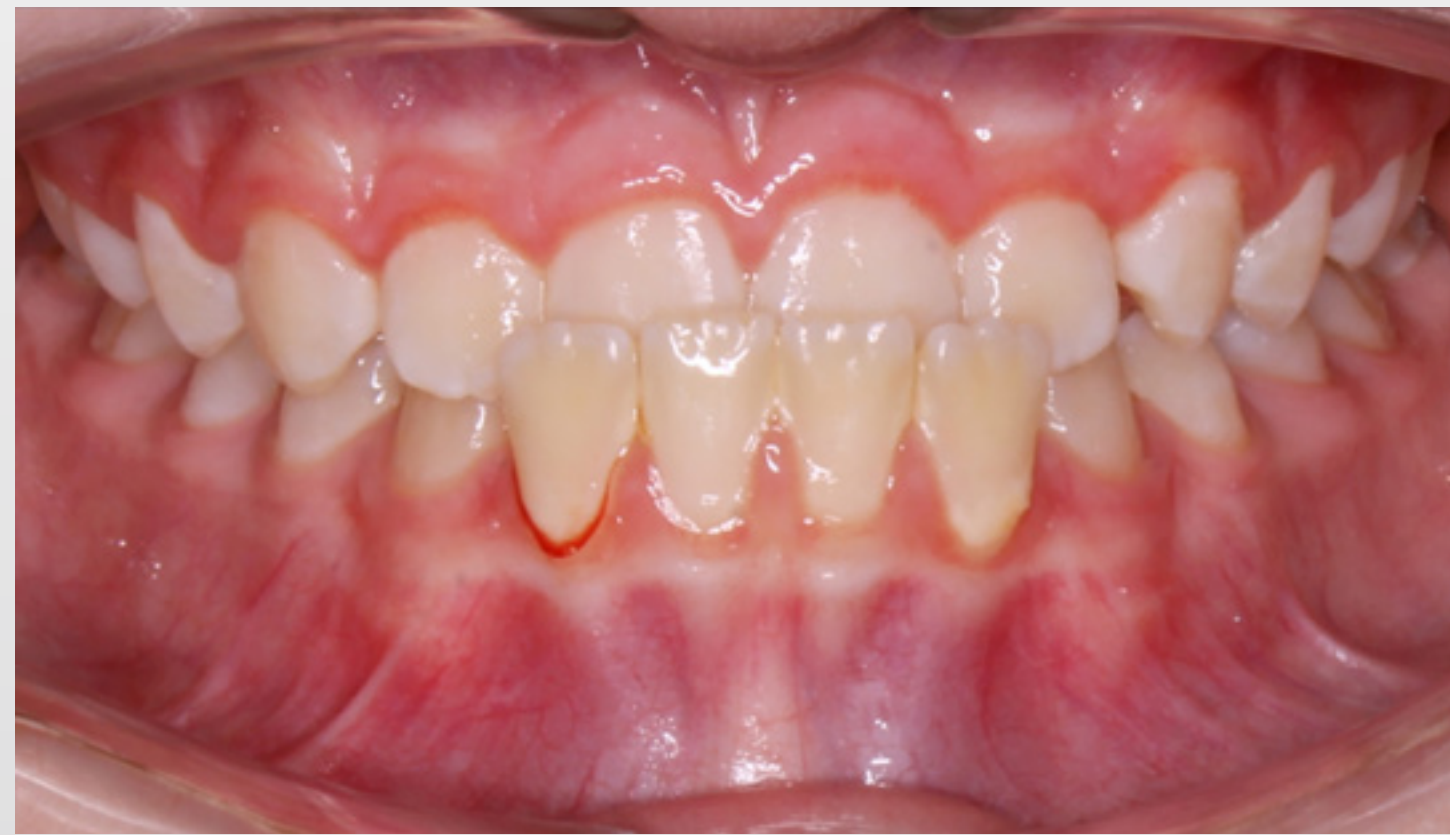Progress - Aligner 40

Final

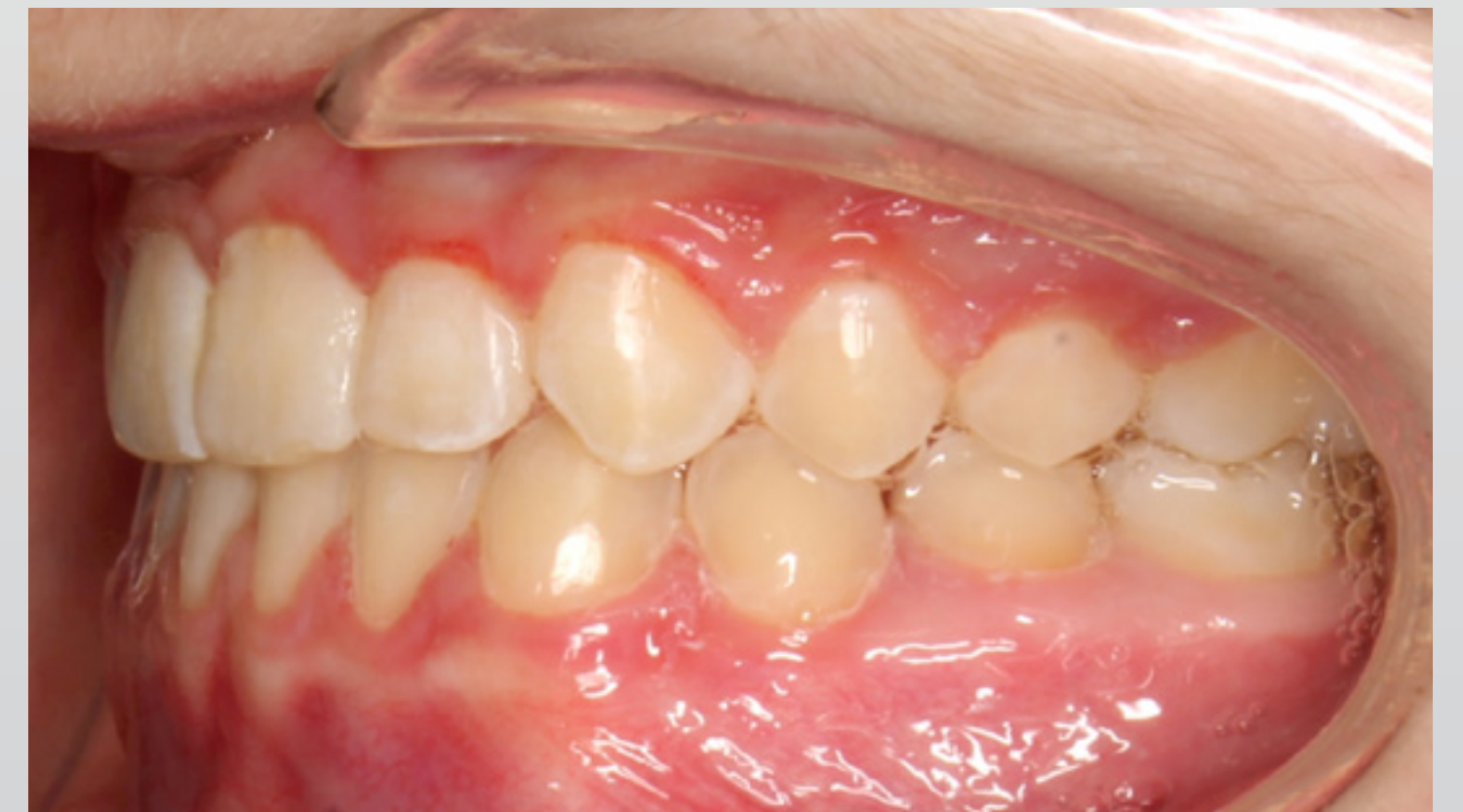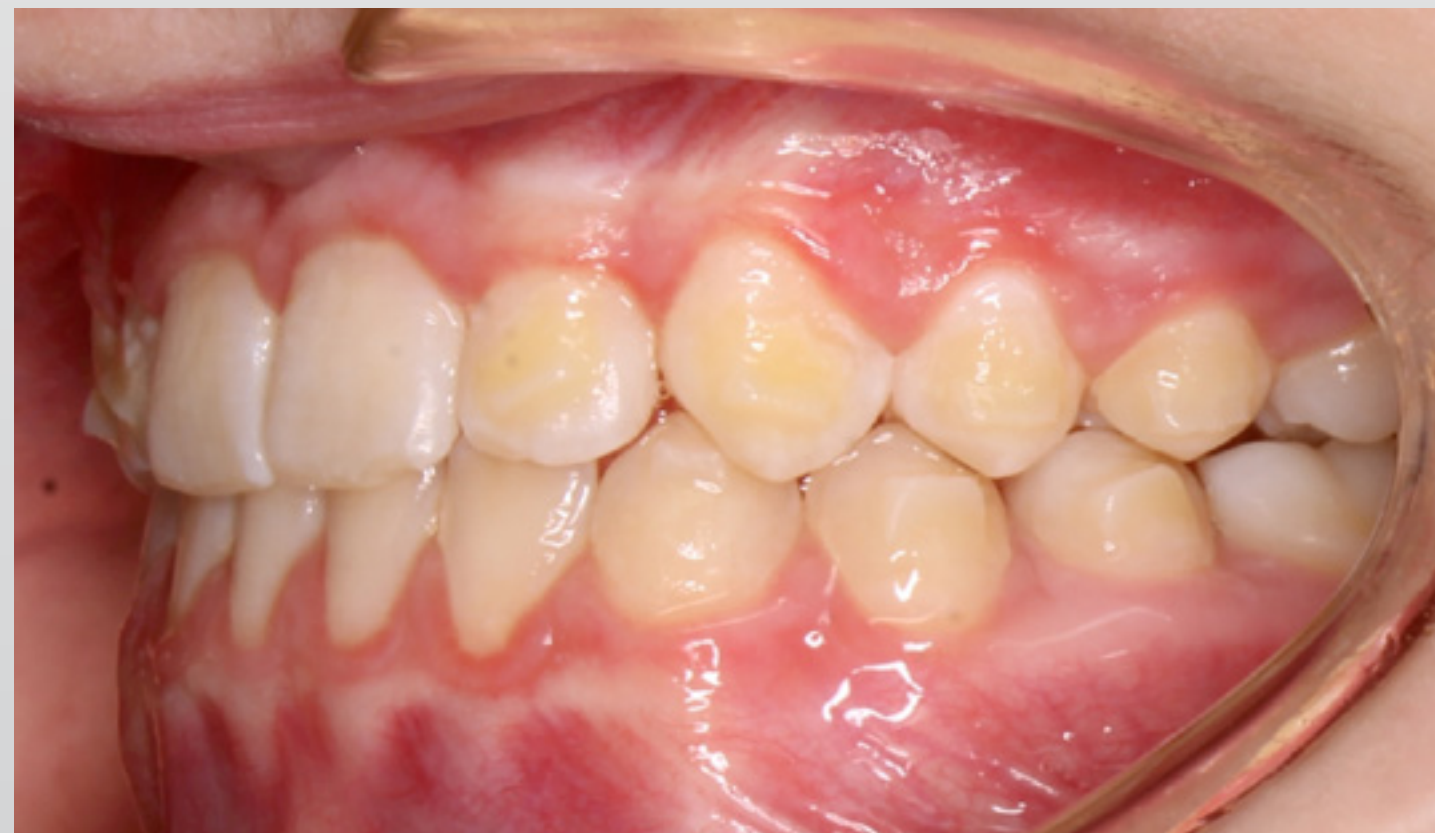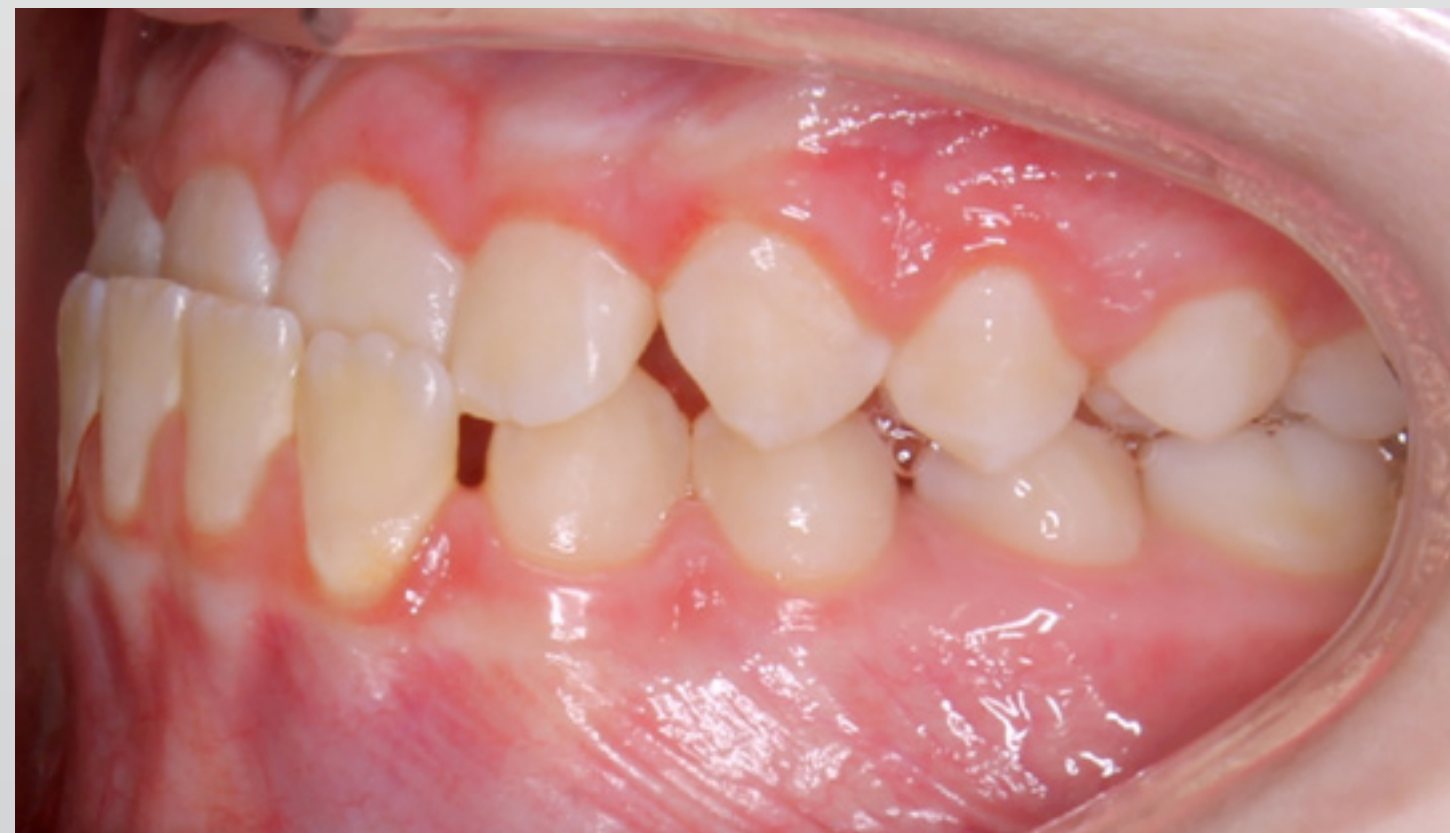**Retracted
buccal – right**



**Retracted
anterior
biting**



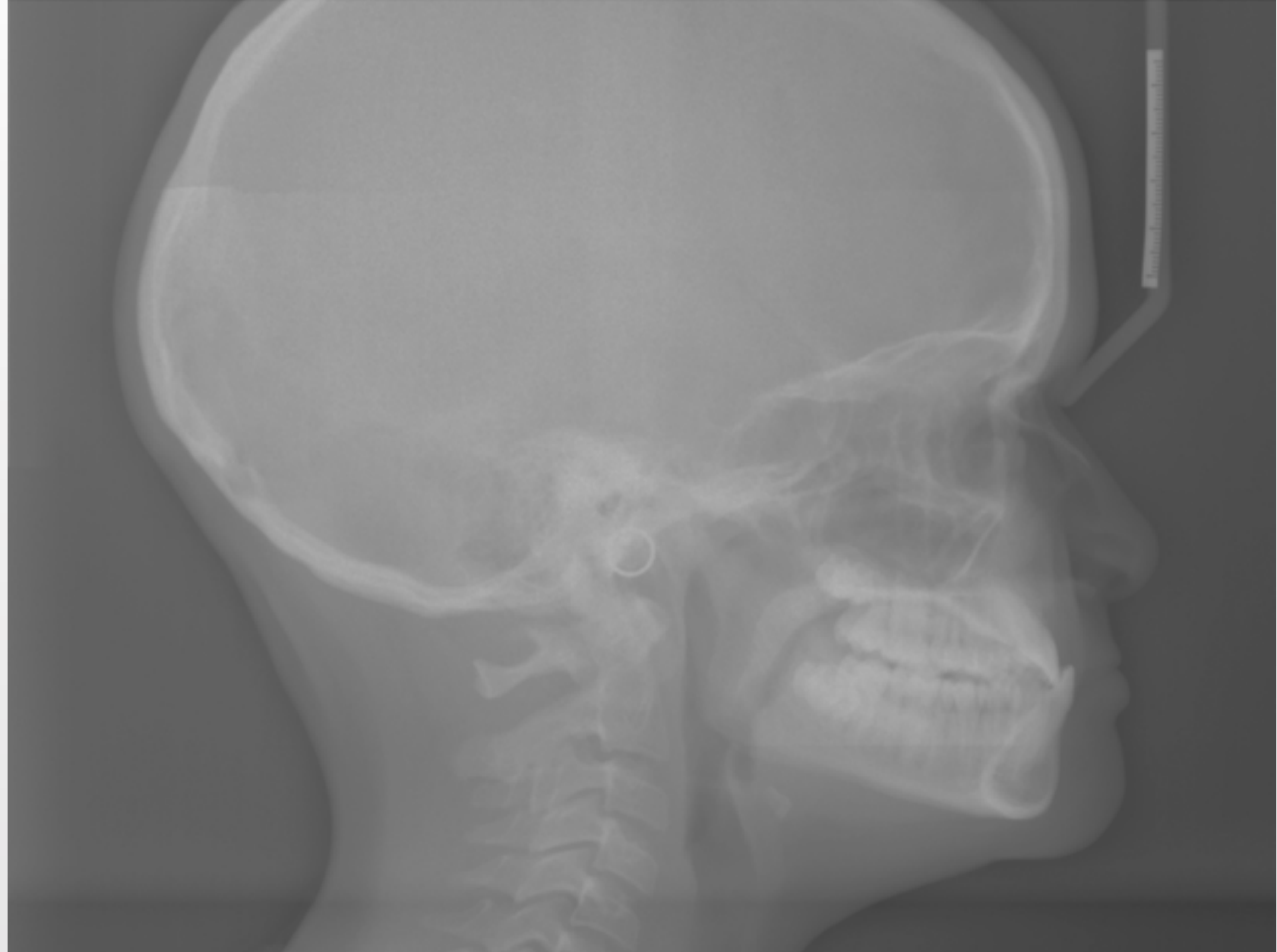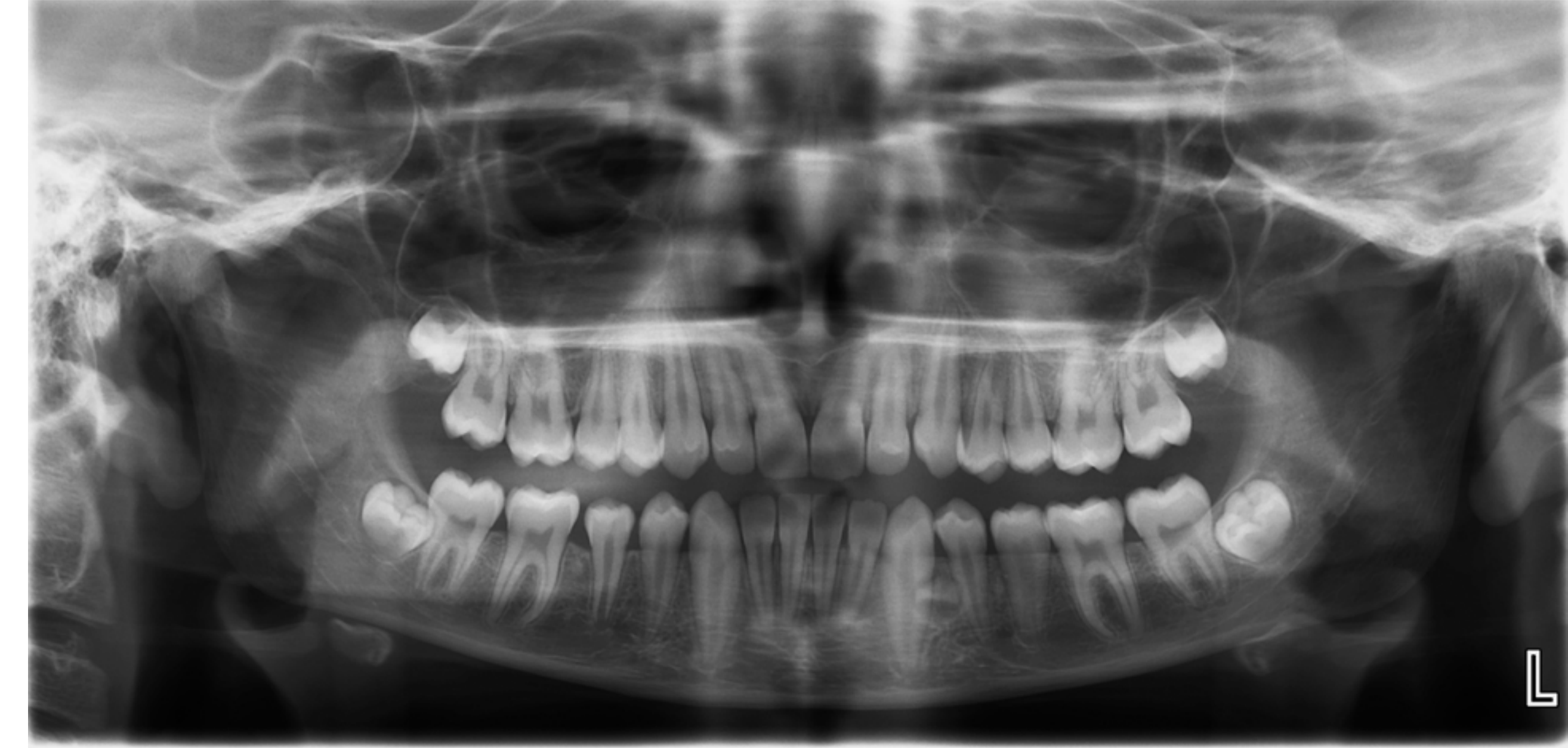**Retracted
buccal – left**



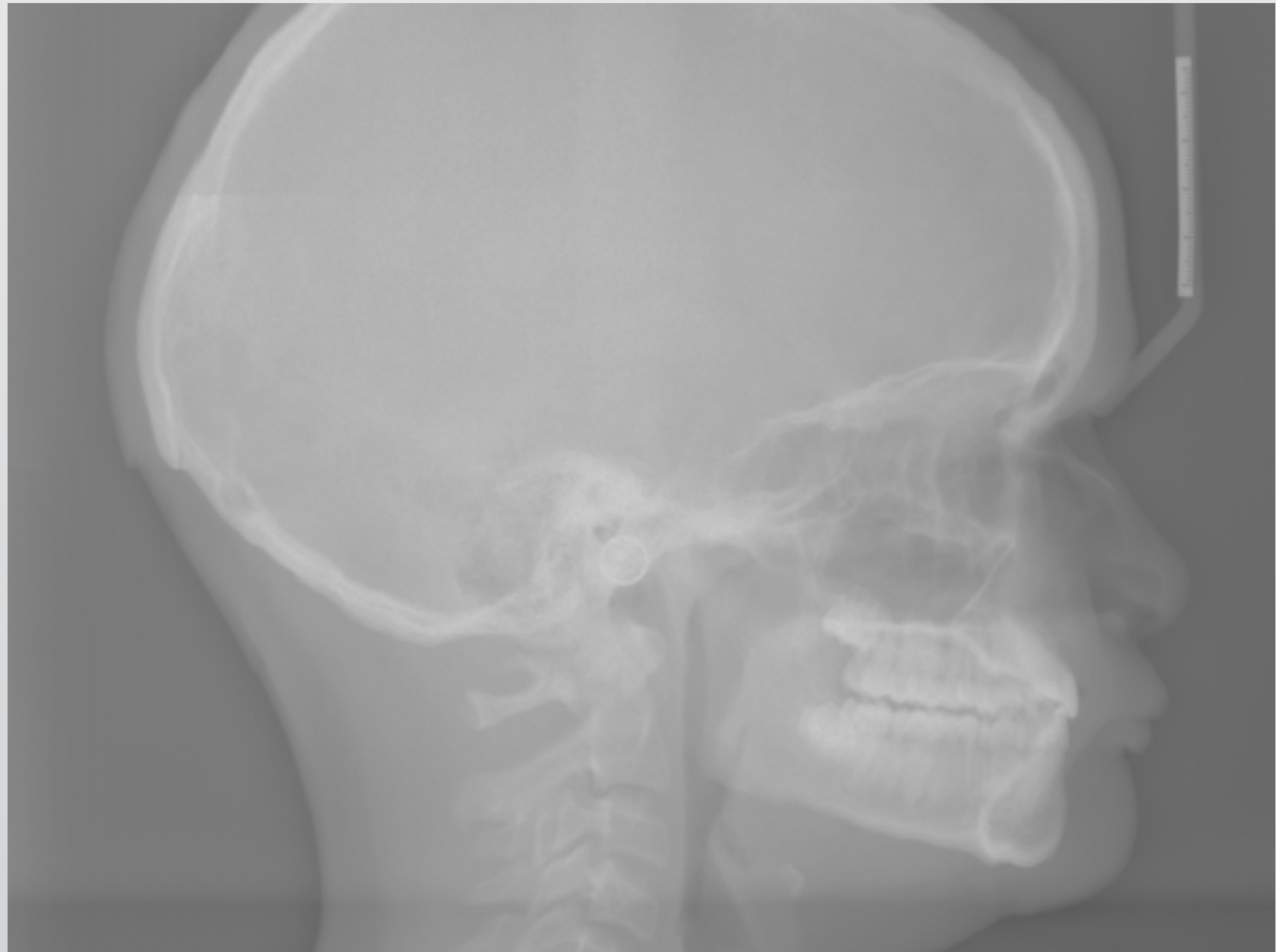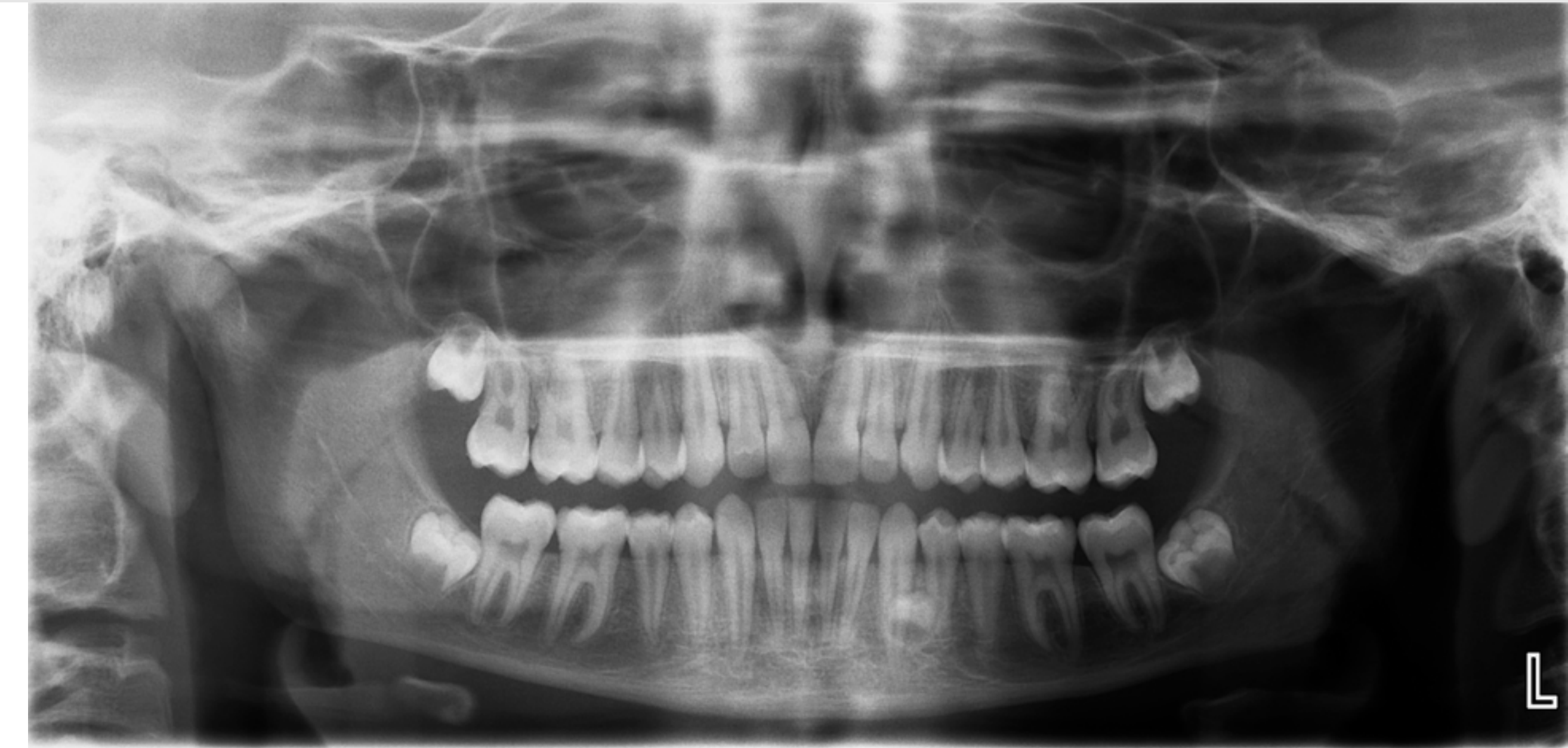Panoramic radiograph

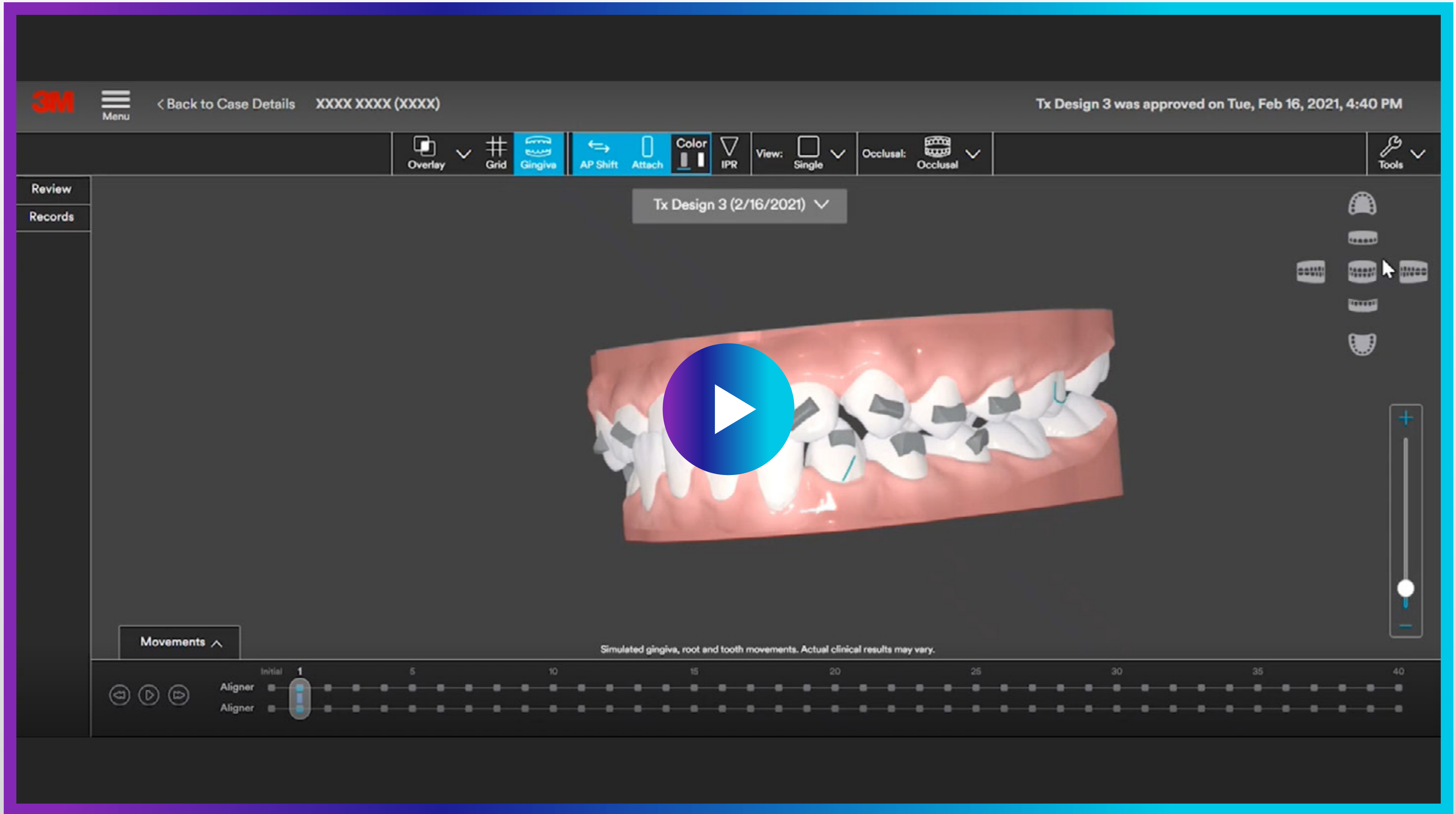
Cephalometric radiograph

Initial



Final





Tx Design Video


- Treatment Plan
- Attachment Strategy
- Key Movements
- Summary of Final Results

[Click here](#) to watch 11:51 minute video.

Ready to learn more?



Discover our proprietary new Clarity Aligners Flex Material!



See more cases from your peers on our Clinical Cases website!



Learn more about the Clarity Aligners system!



Rediscover the Oral Care Portal, submit a case today!