

Case Study: 3M™ Clarity™ Aligners

**Unilateral posterior crossbite
and anterior open bite.**

Age: 15

Chief concern: “I want straight teeth”

Case diagnostics:

Orthognathic maxilla/retrognathic mandible,
Class II tendency, mild maxillary/mandibular
crowding, midline discrepancy (mandibular midline
is ~ 3 mm to the right), anterior open bite, excess
overjet (~ 6 mm), finger sucking habit

Total number of aligners: 64

Initial Tx Design: stages 1-40 (40 aligners)

Refinement Tx Design: stages 41-64 (24 aligners)

Aligner Material: 3M™ Clarity™ Aligners Force

Wear interval: 7 days

Treatment time: 18 months

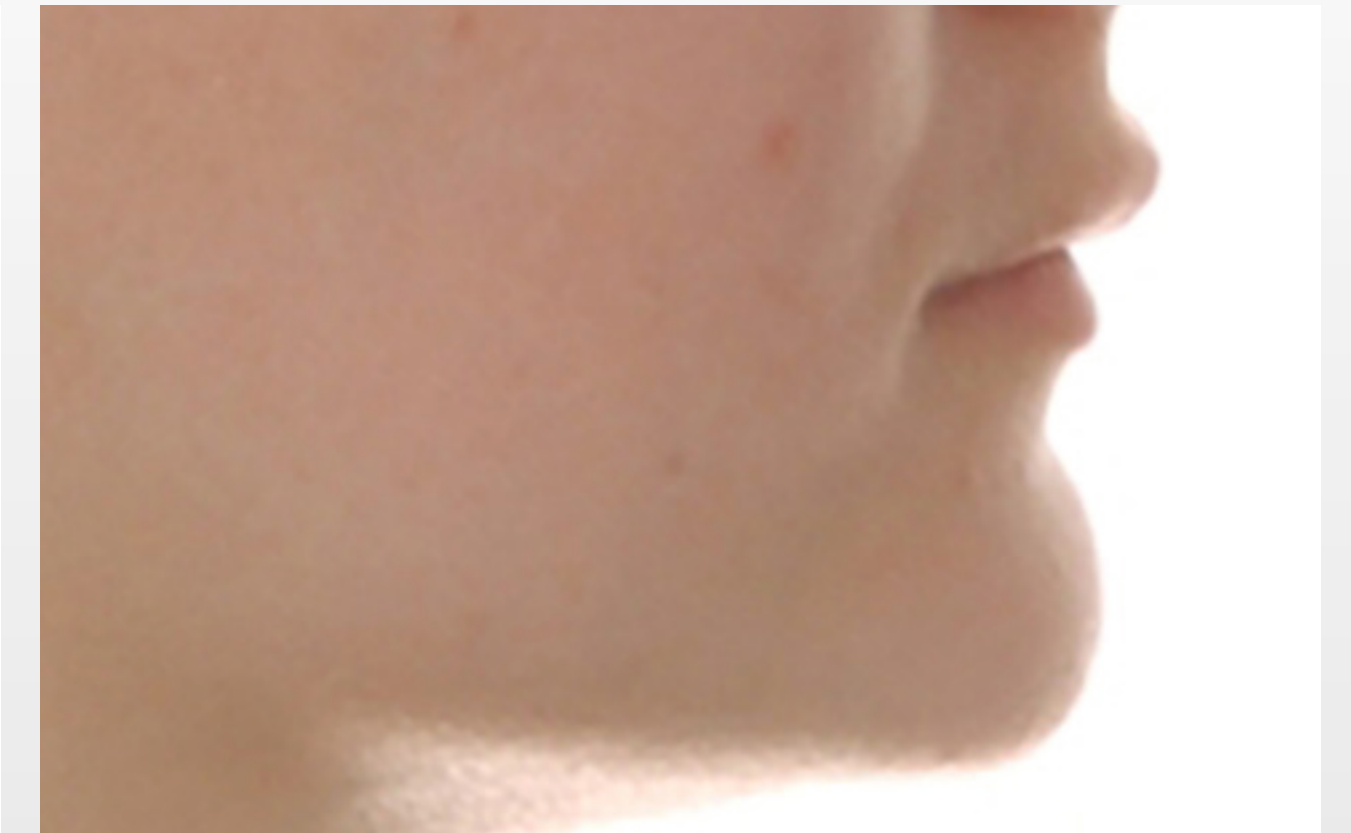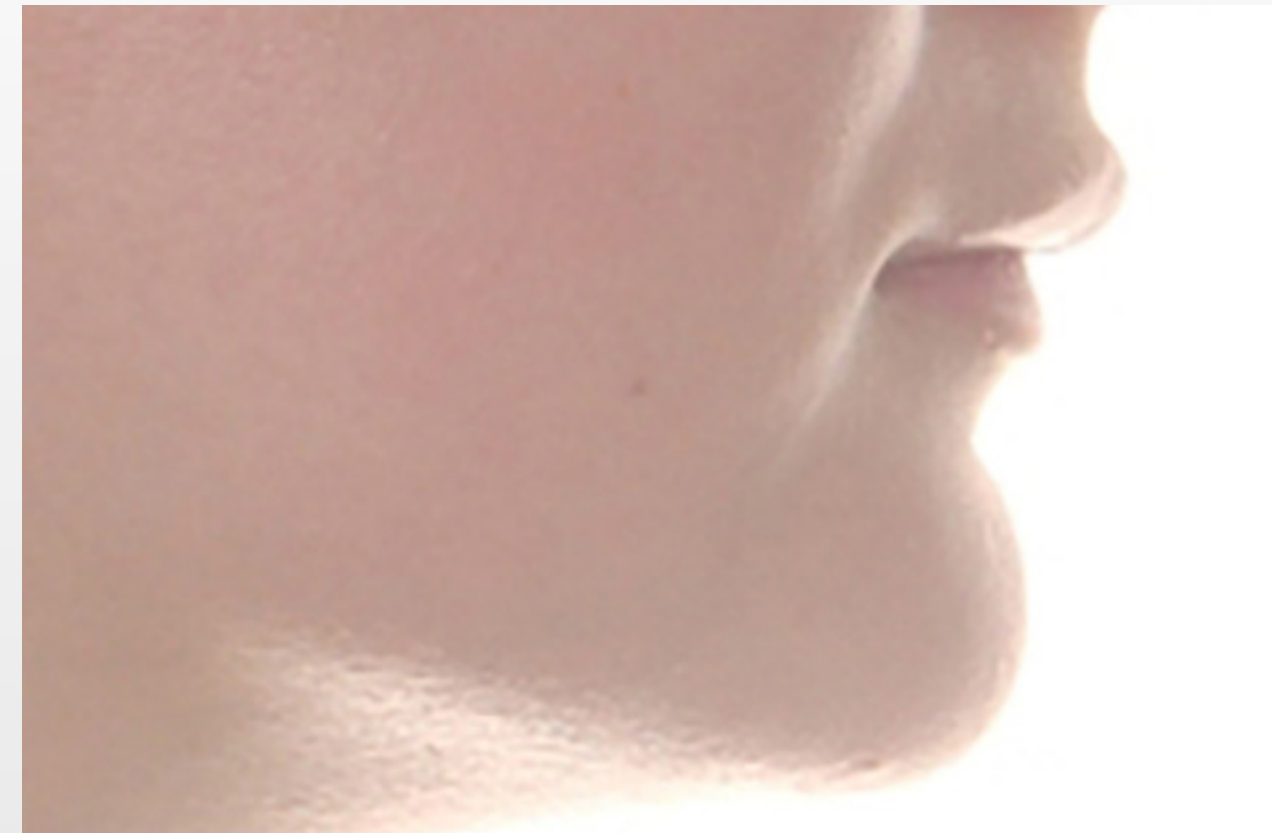Case courtesy of:

Dr. Matt Dunn
Scottsdale, AZ – USA

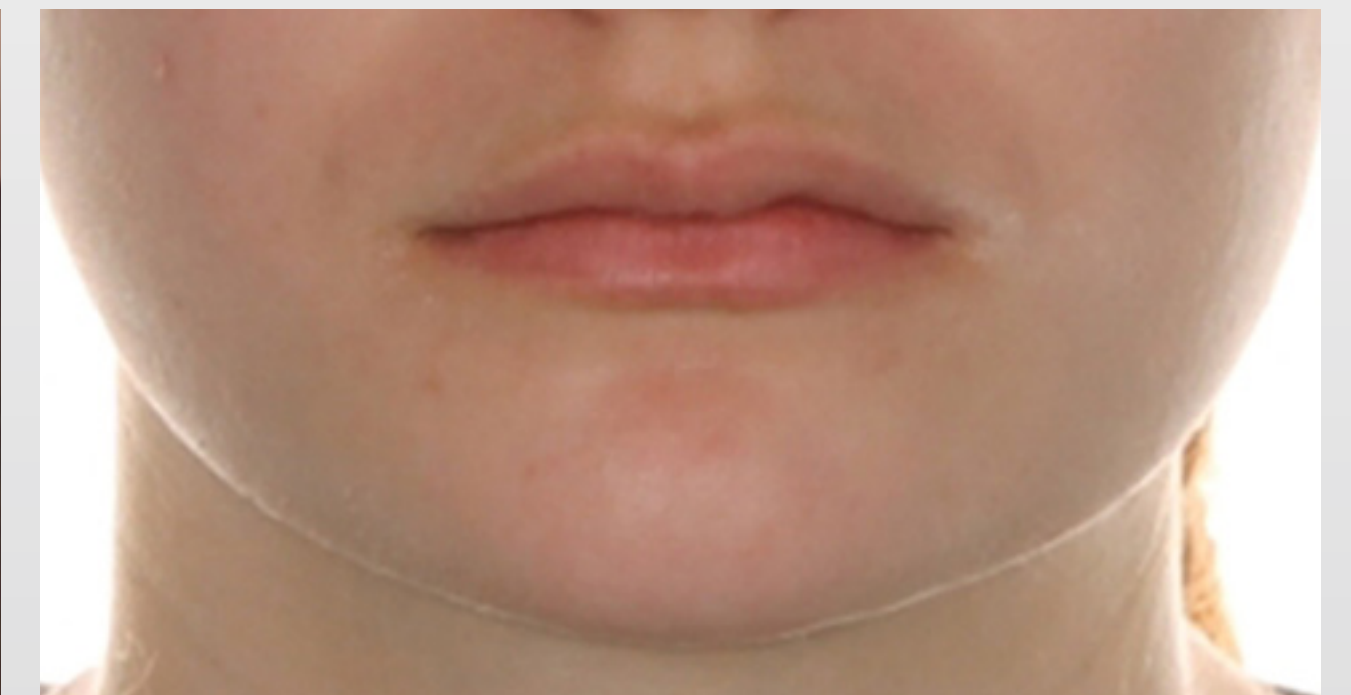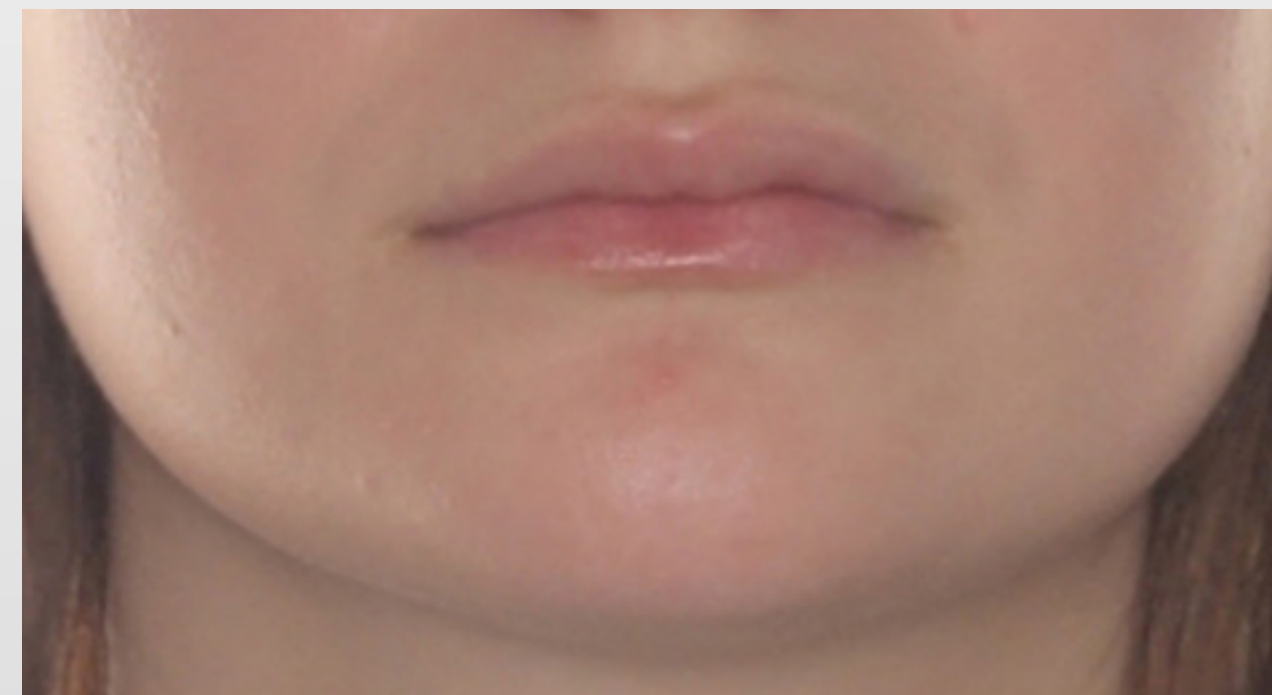Initial

Final

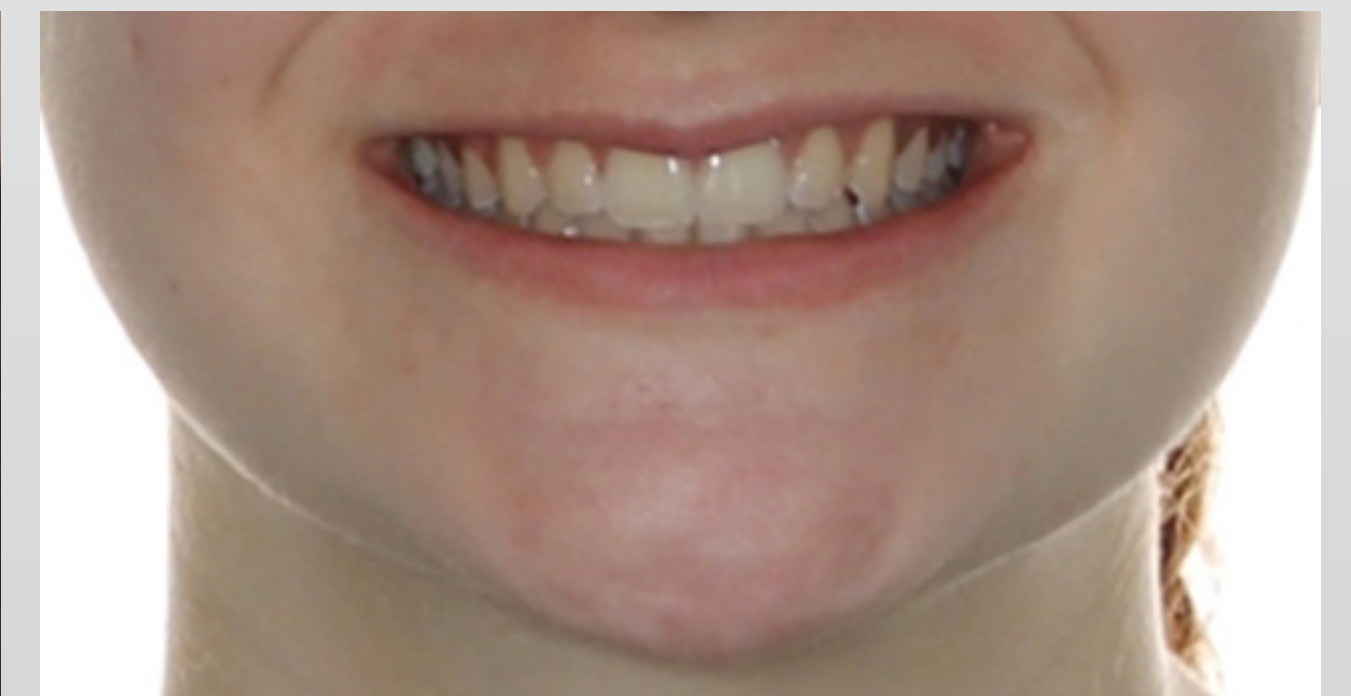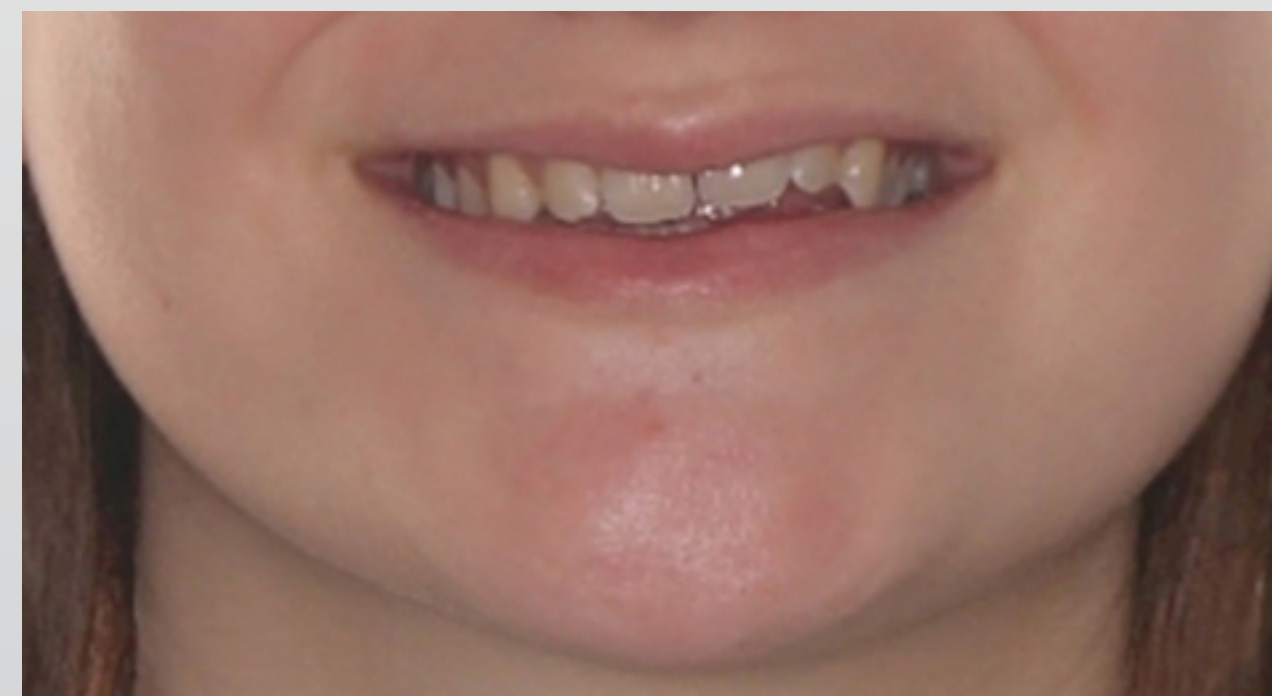Profile at rest



Face at rest



Face smiling

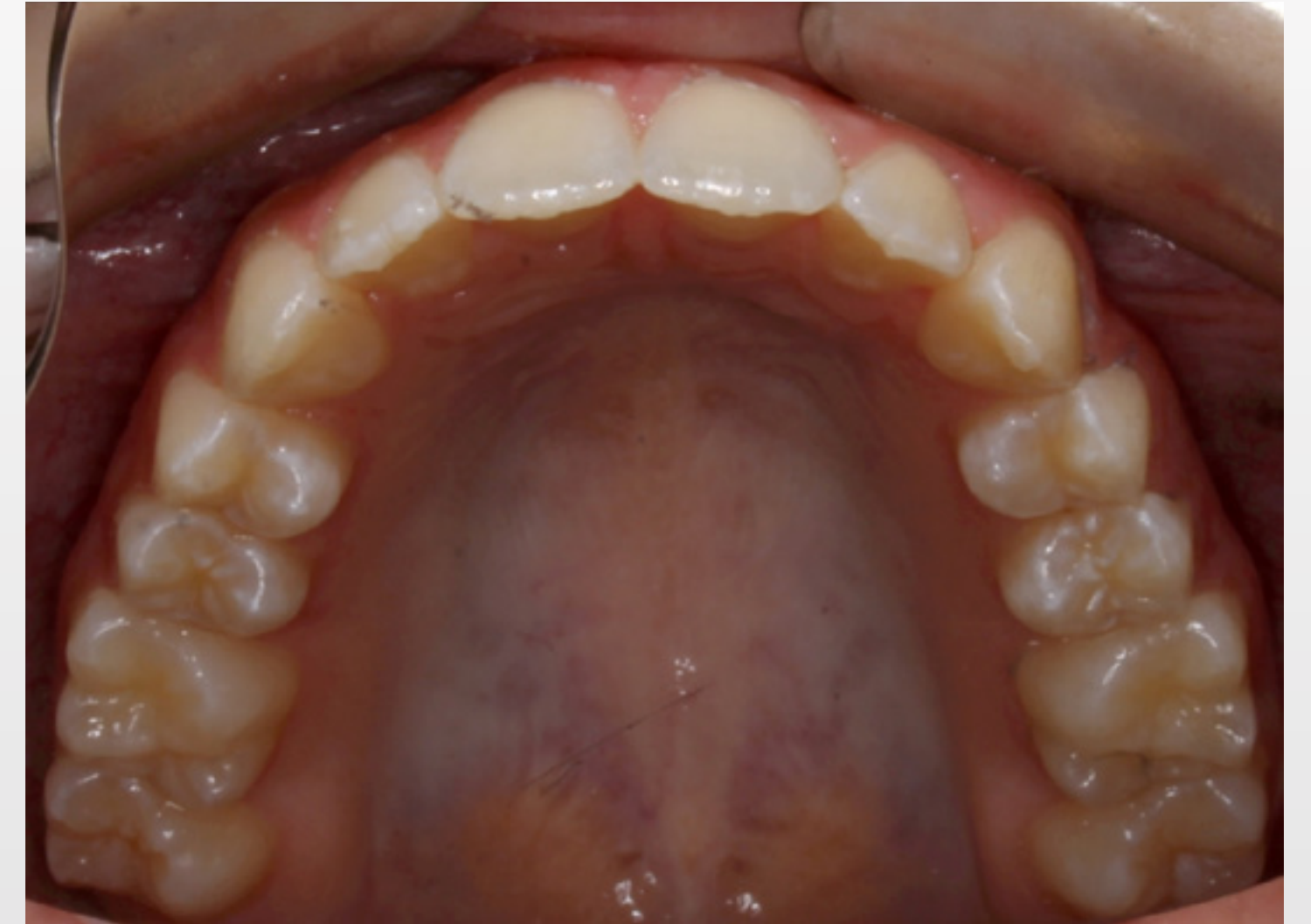
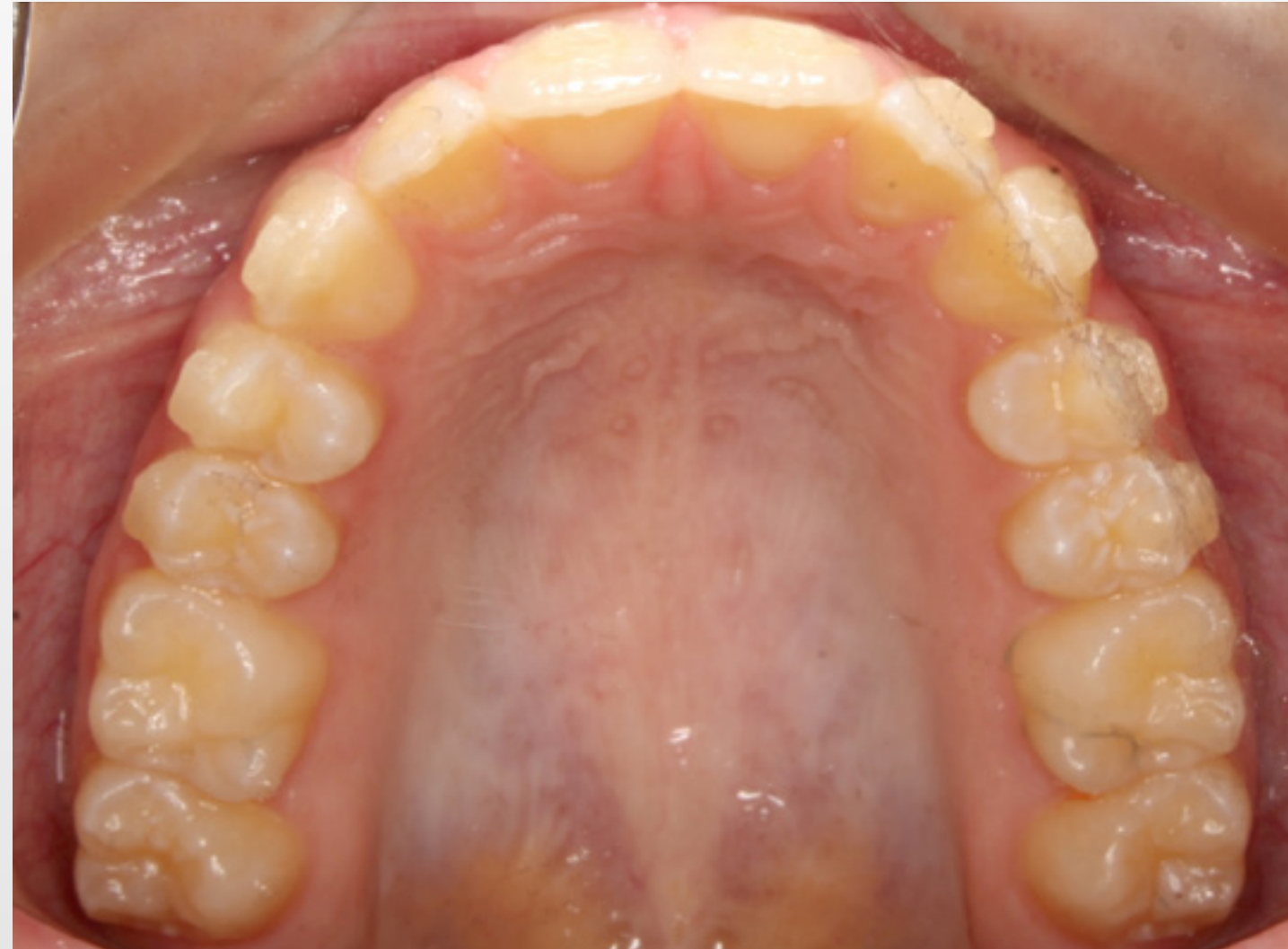
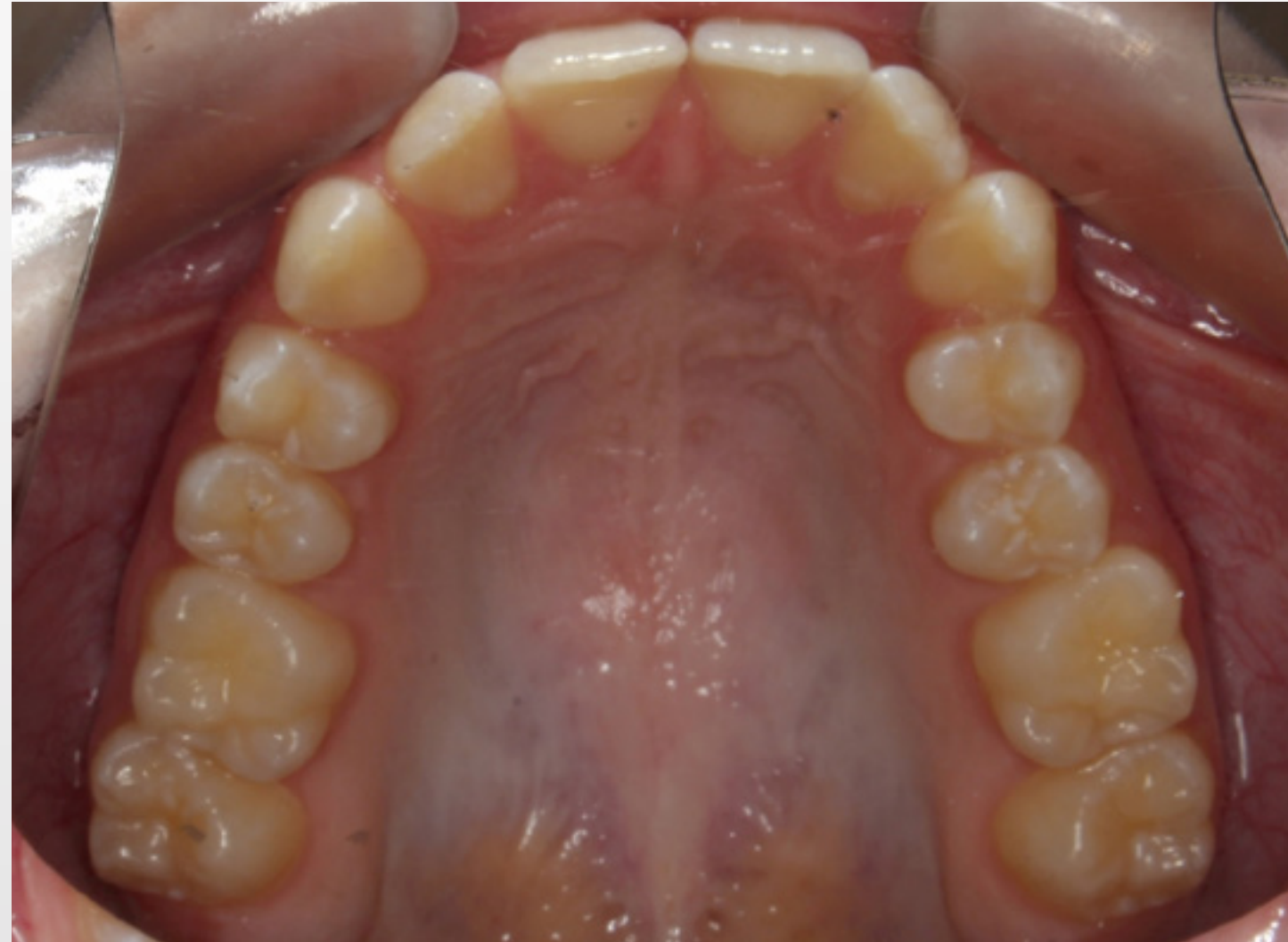Initial

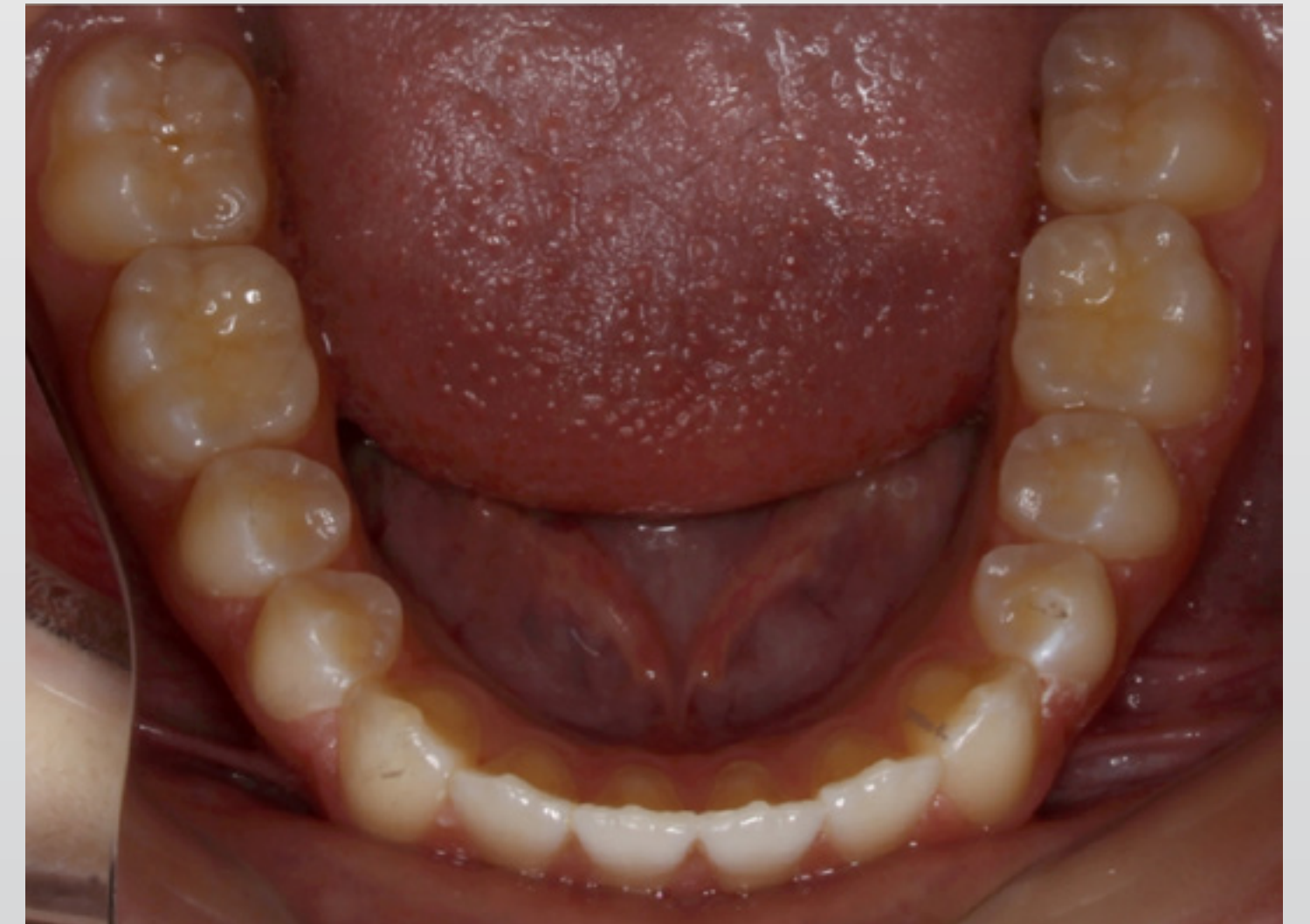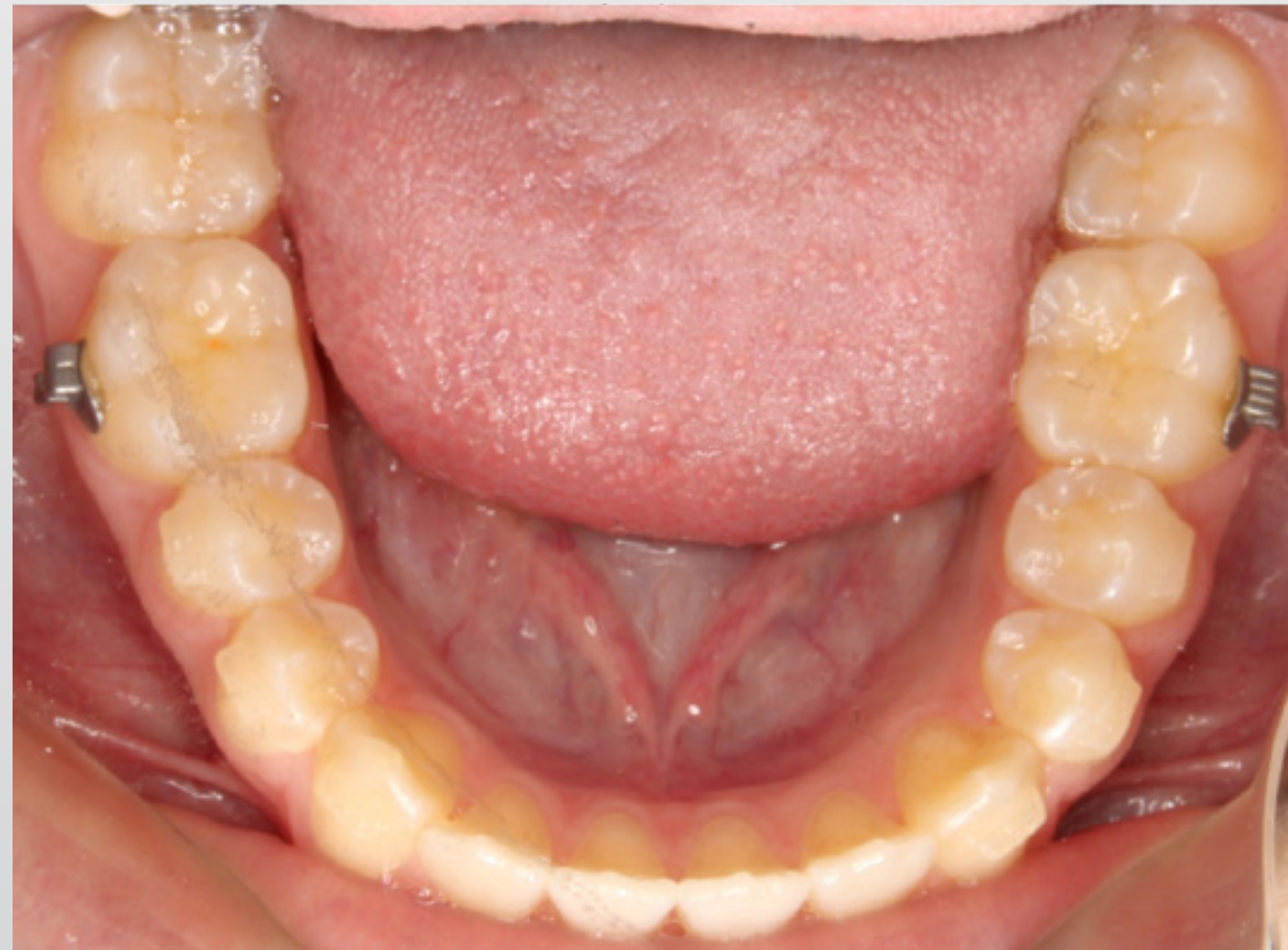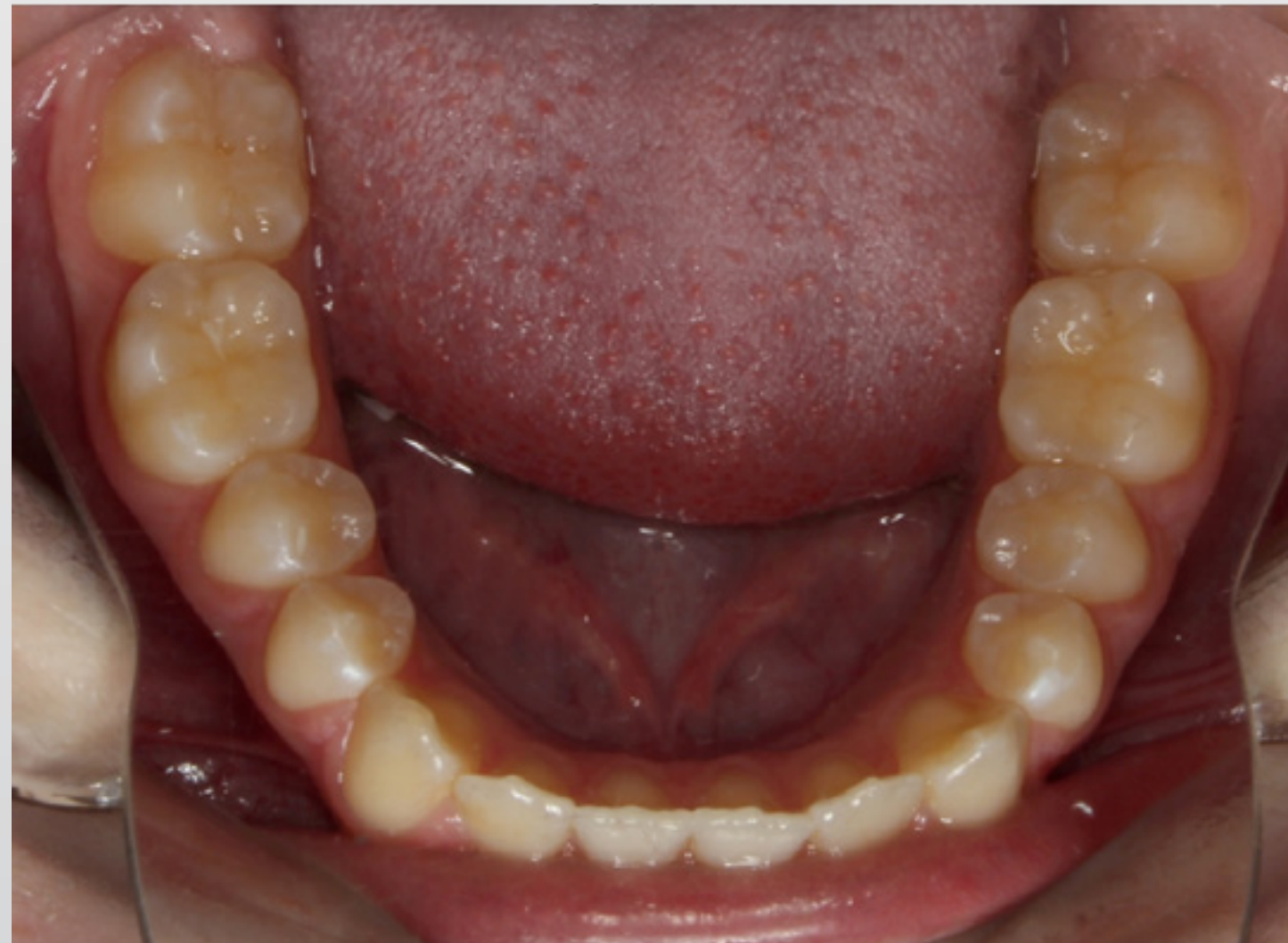Progress - Aligner 40

Final

**Occlusal –
maxillary**



**Occlusal –
mandibular**

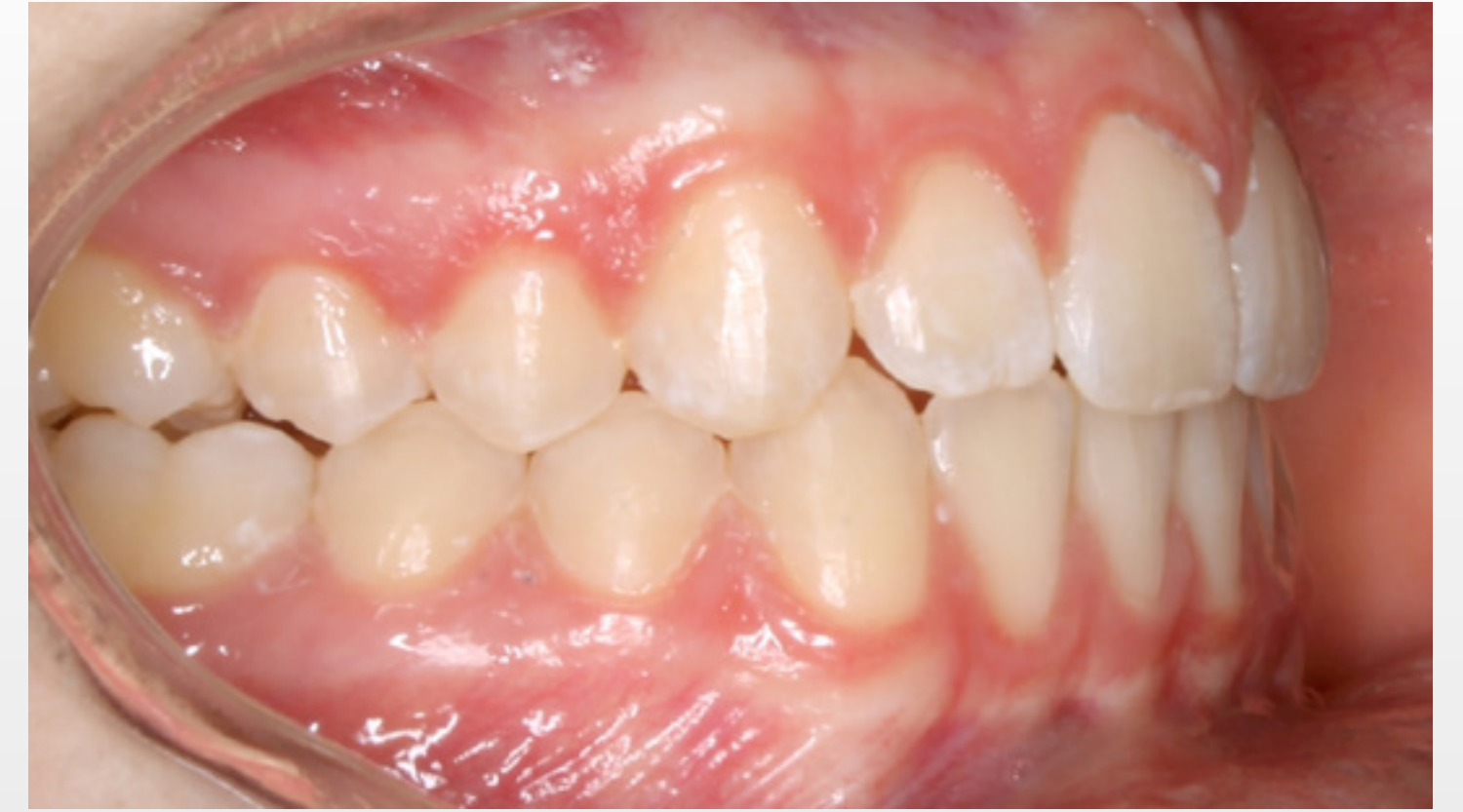
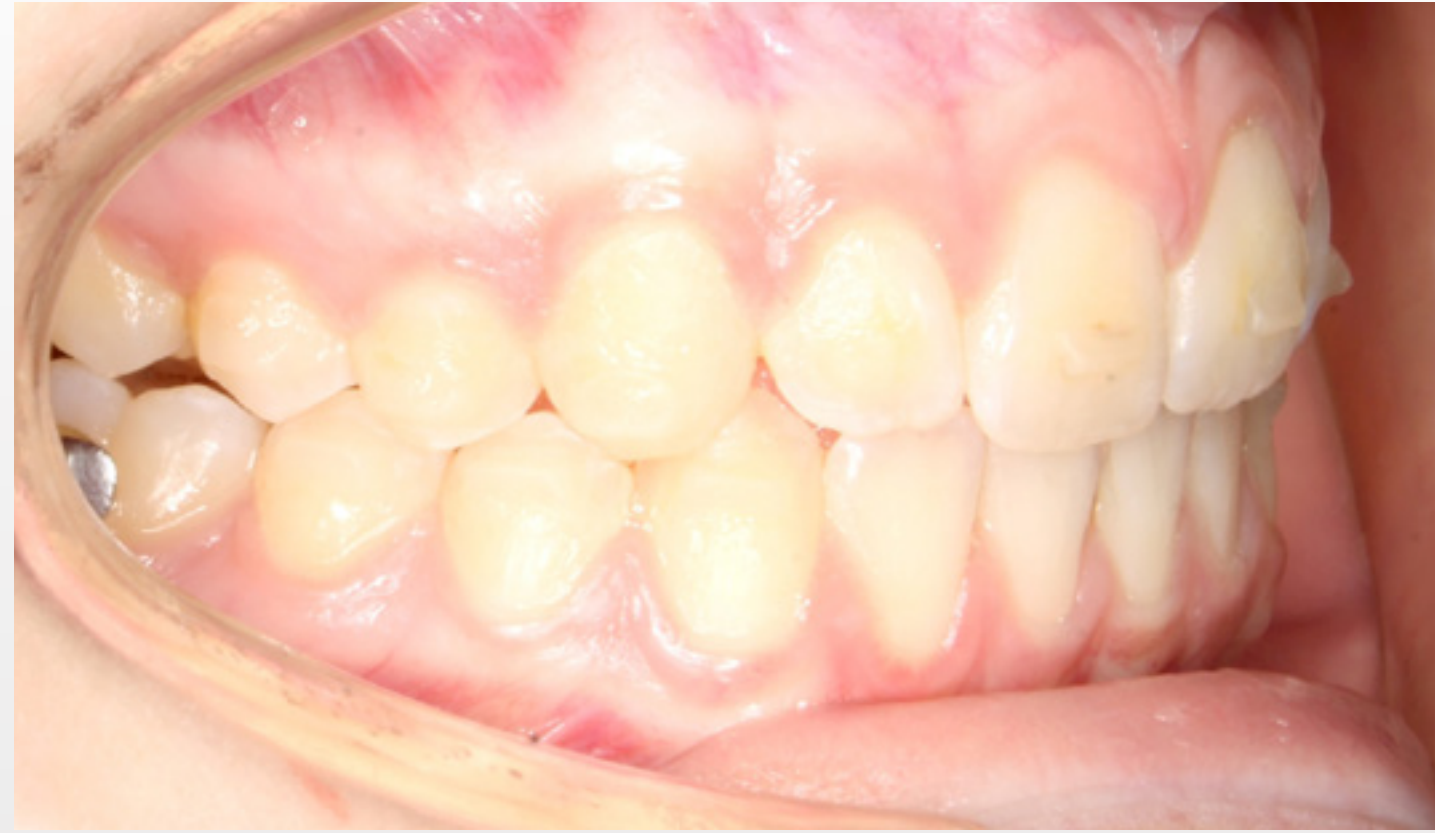
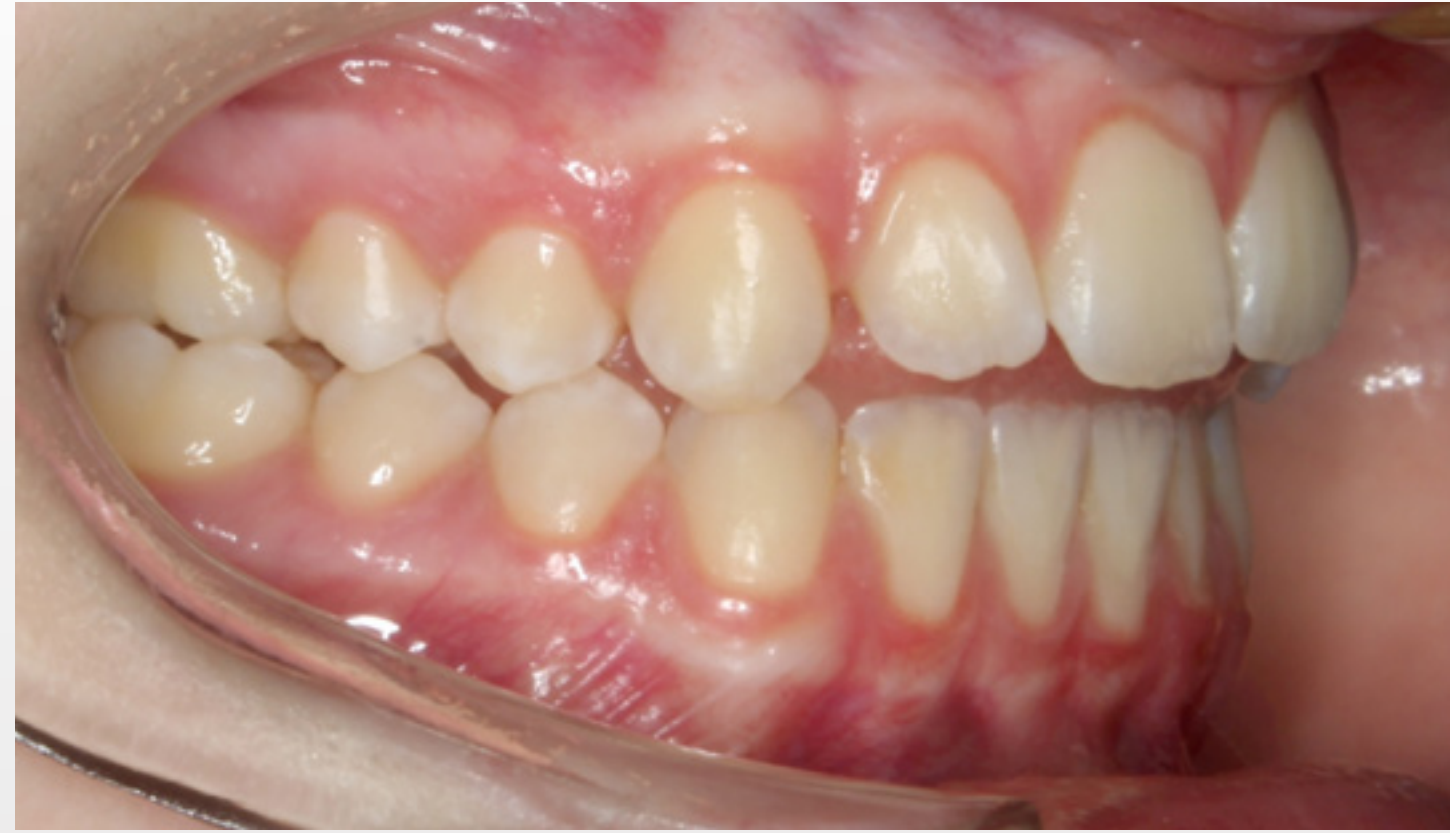Initial

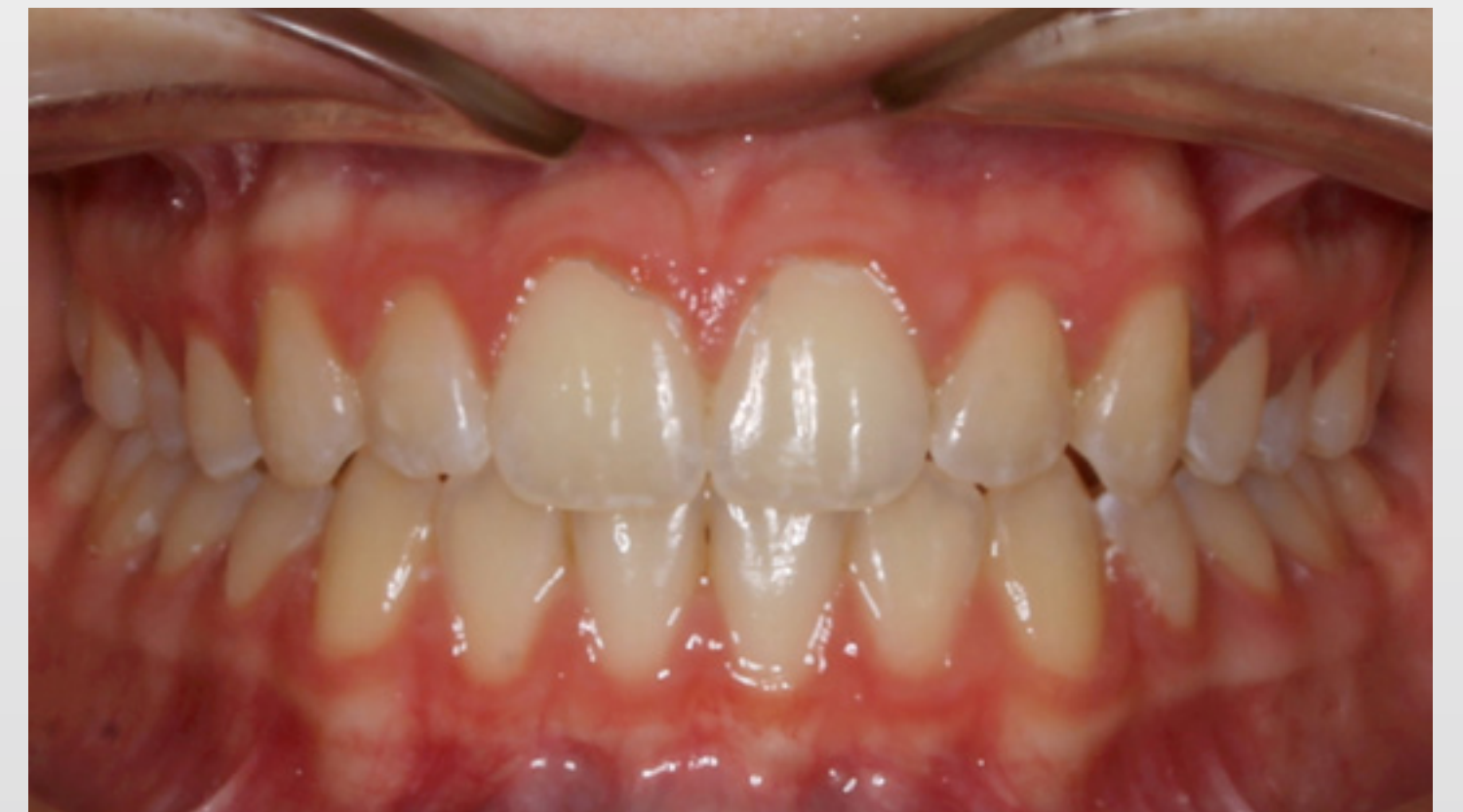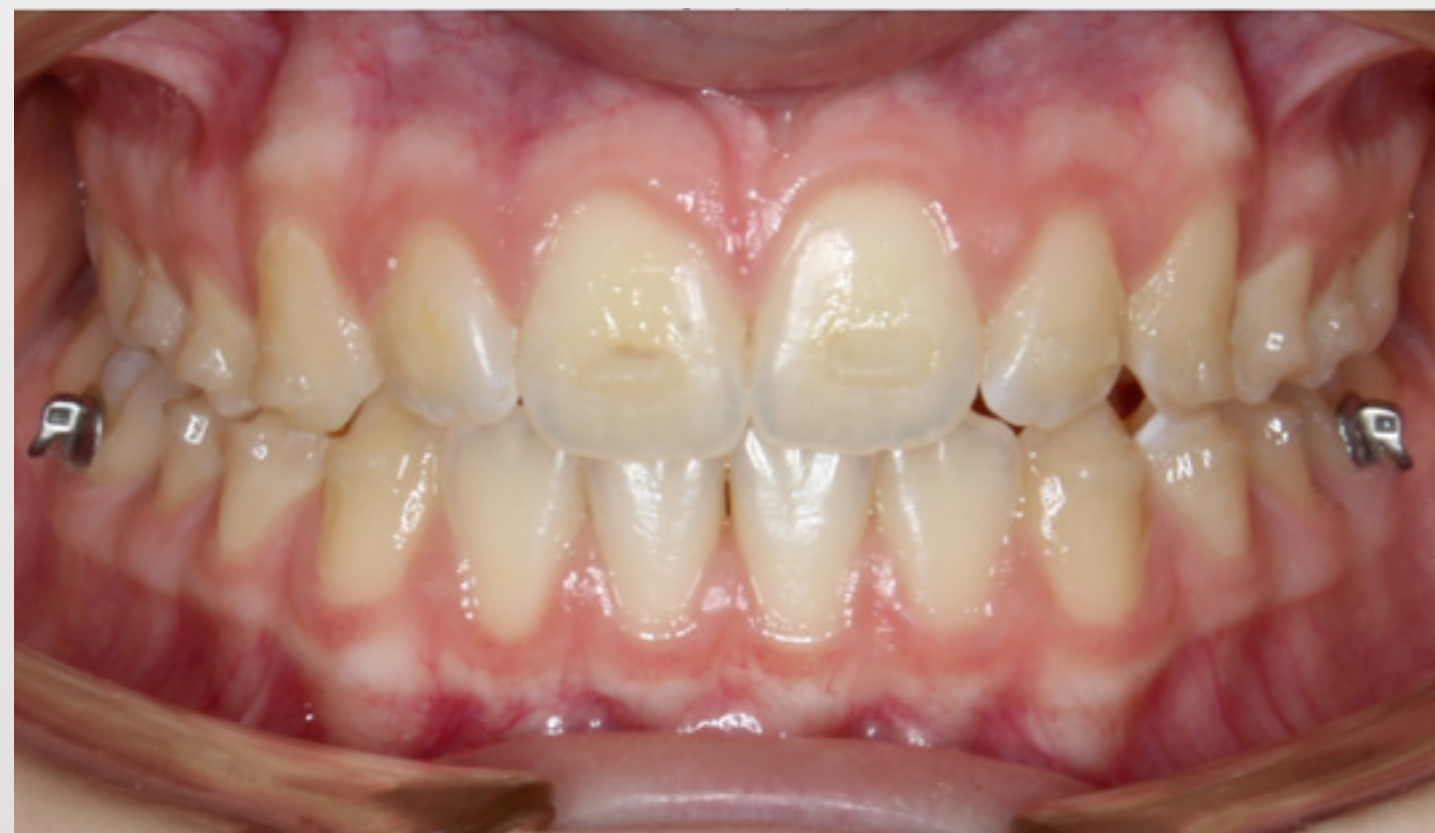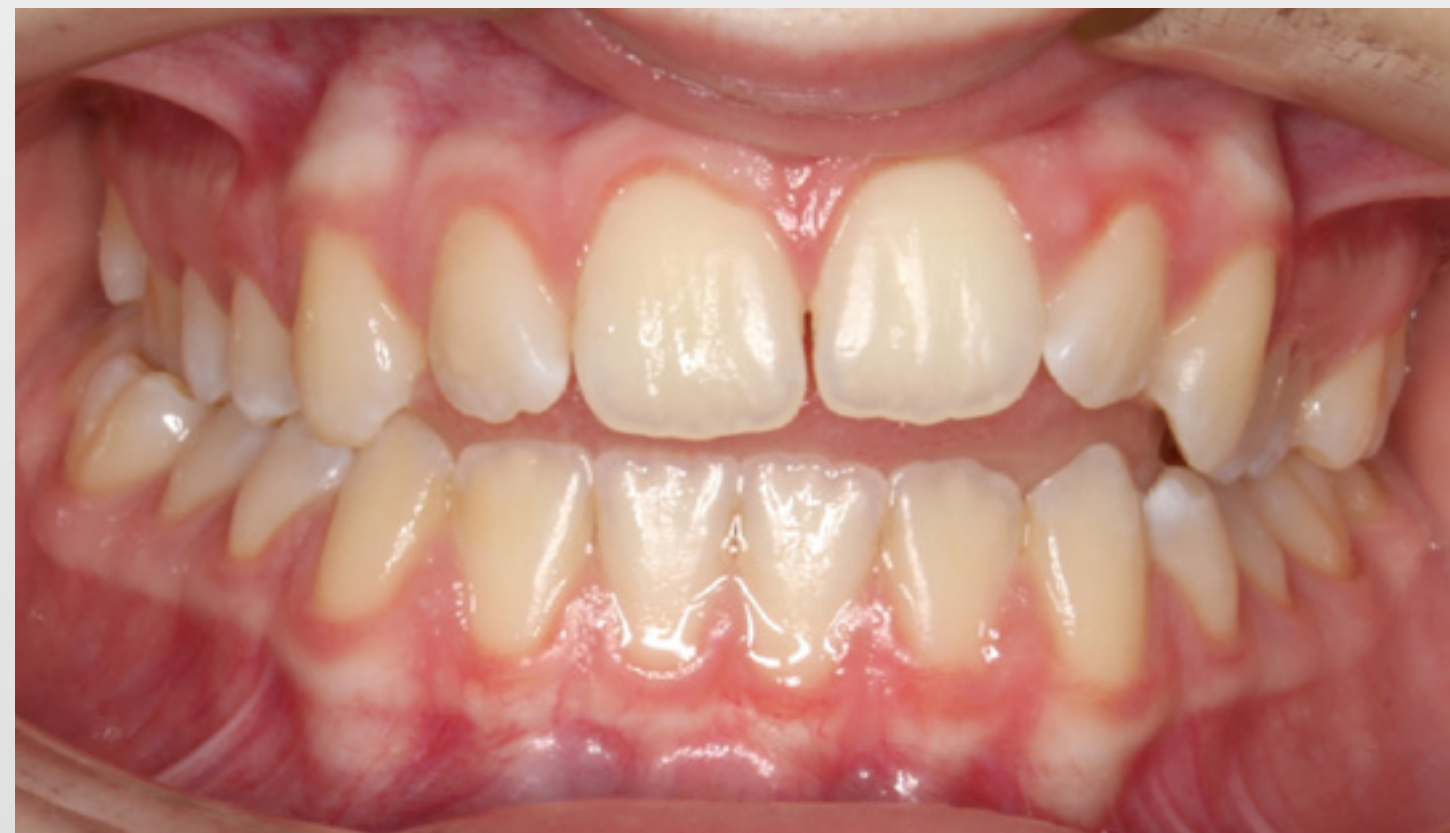Progress - Aligner 40

Final

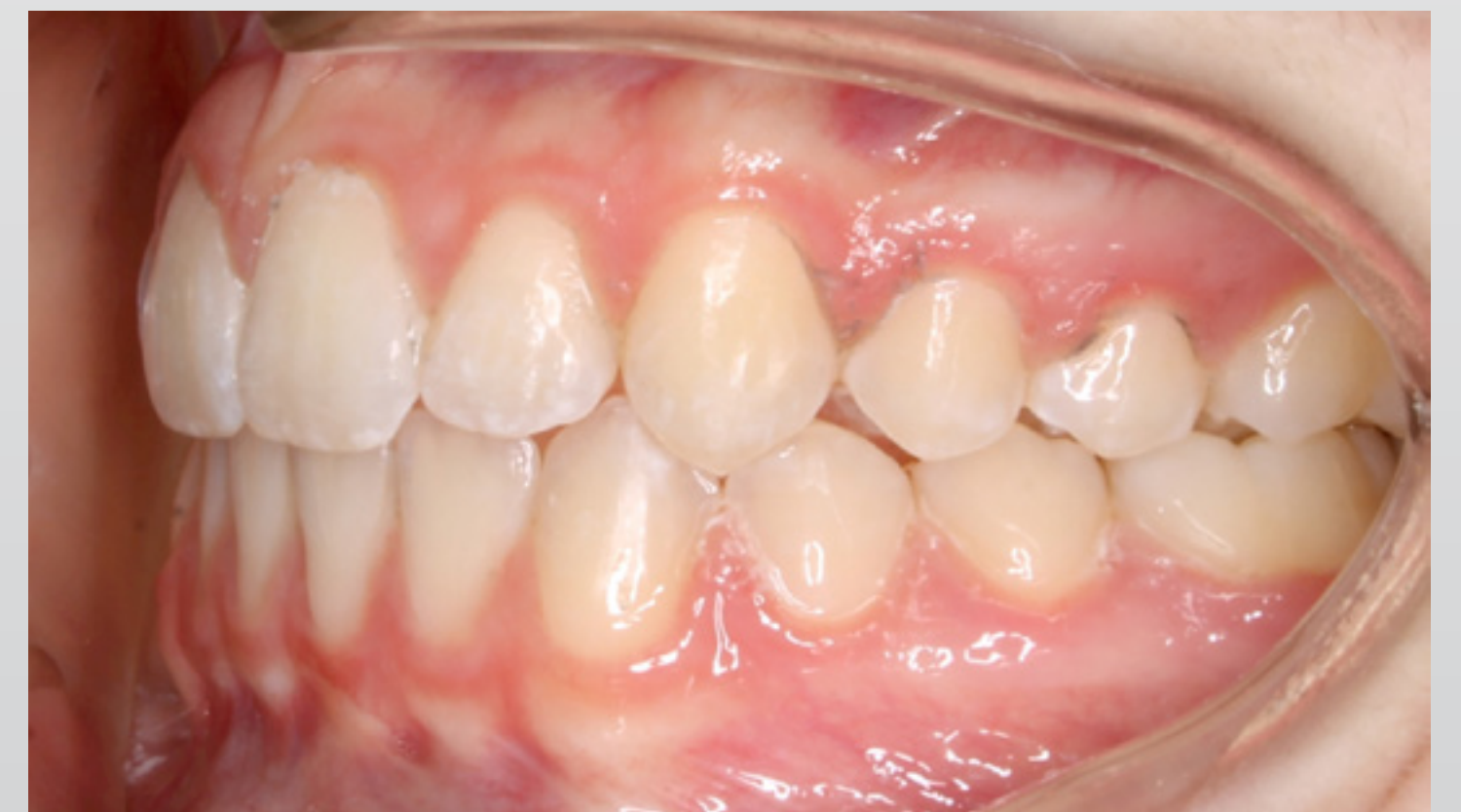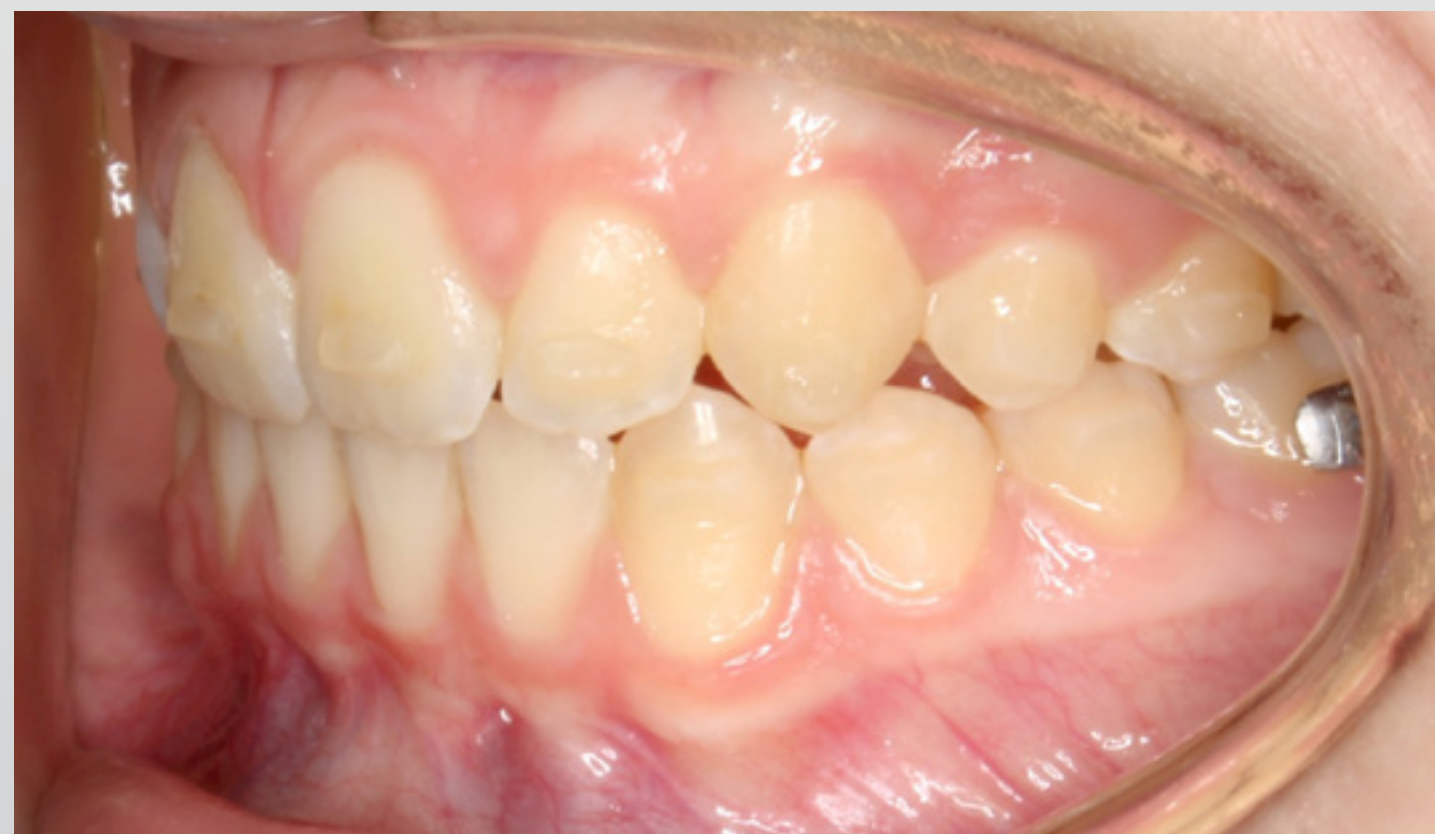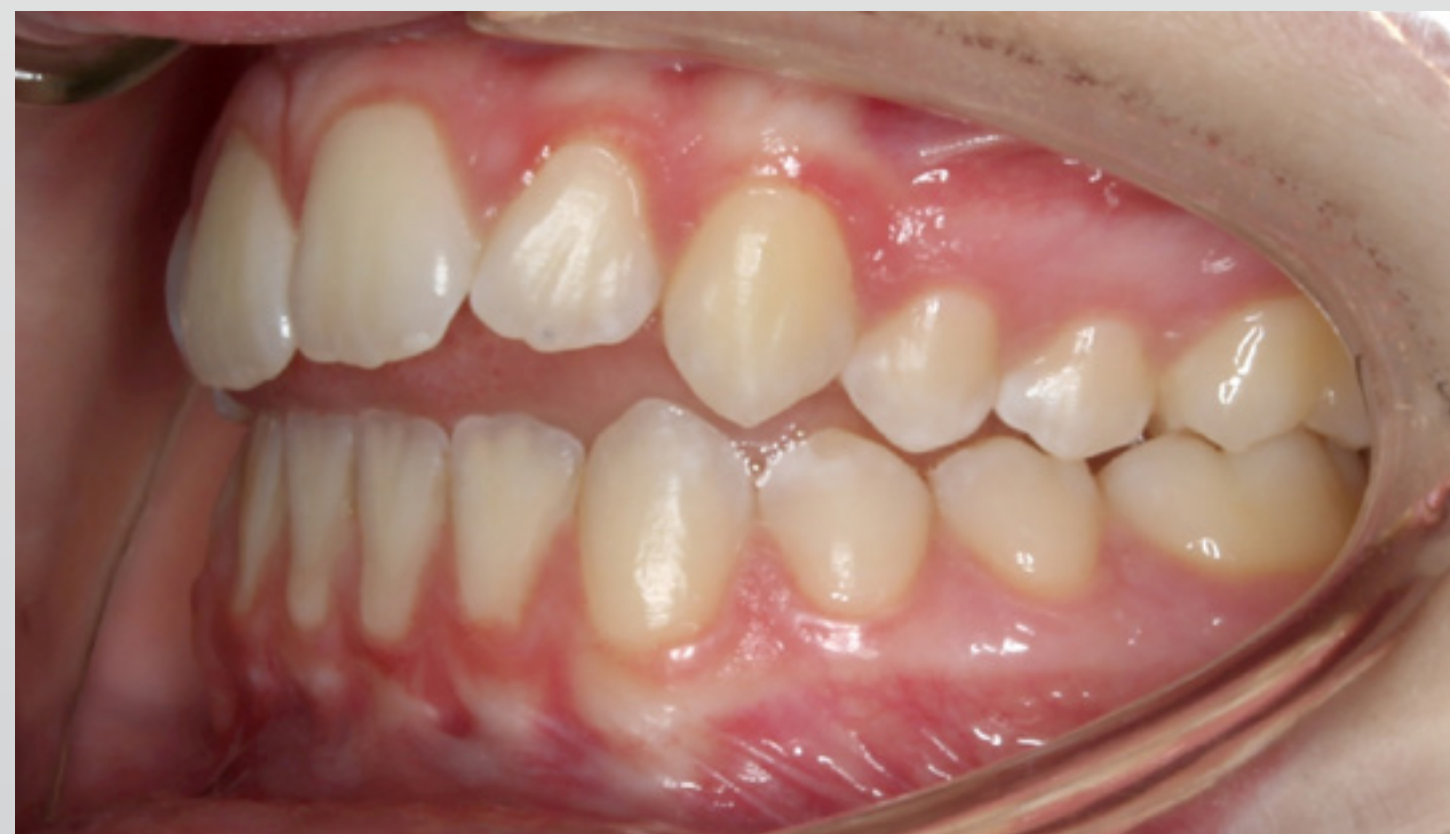**Retracted
buccal - right**



**Retracted
anterior
biting**



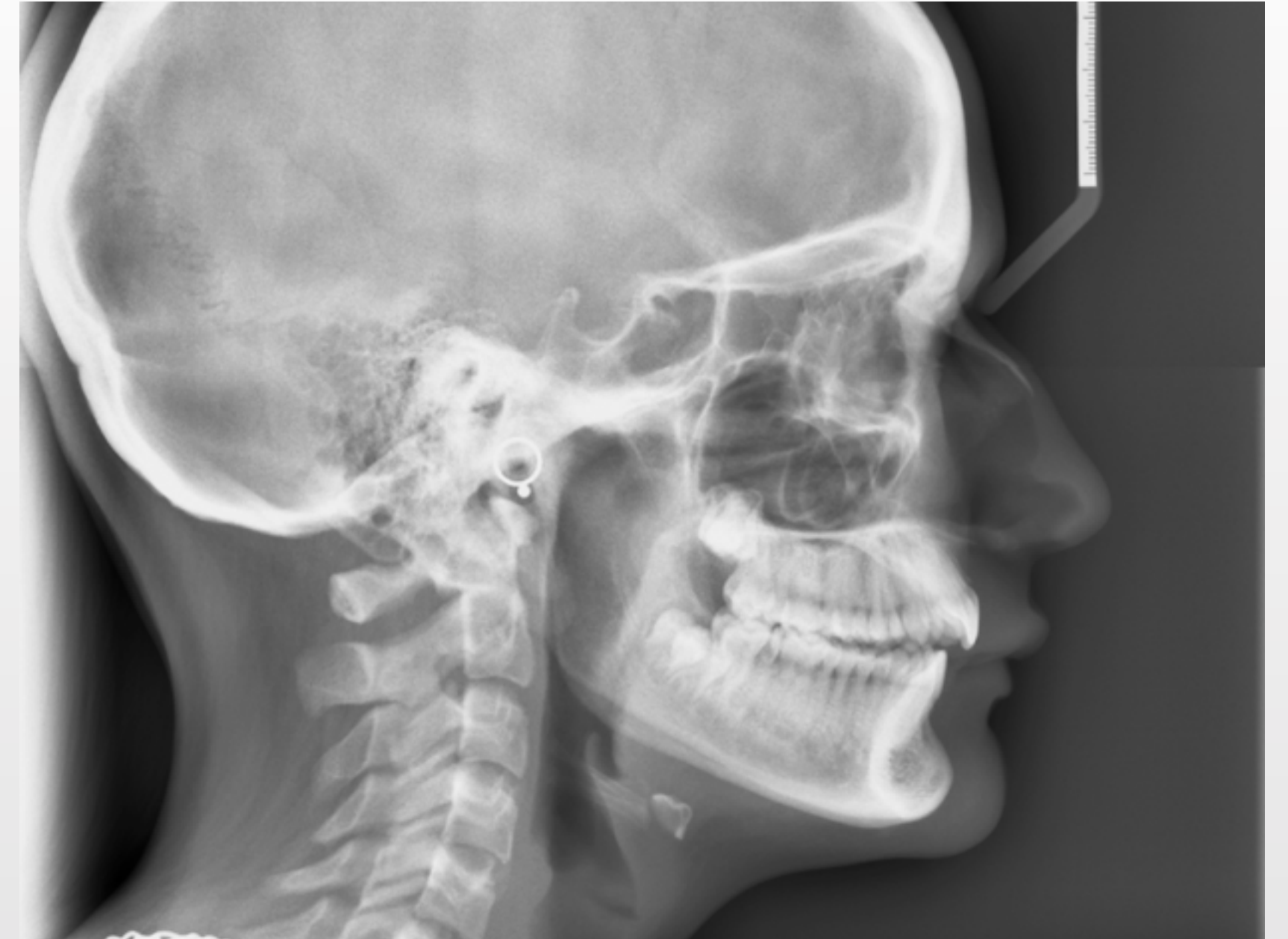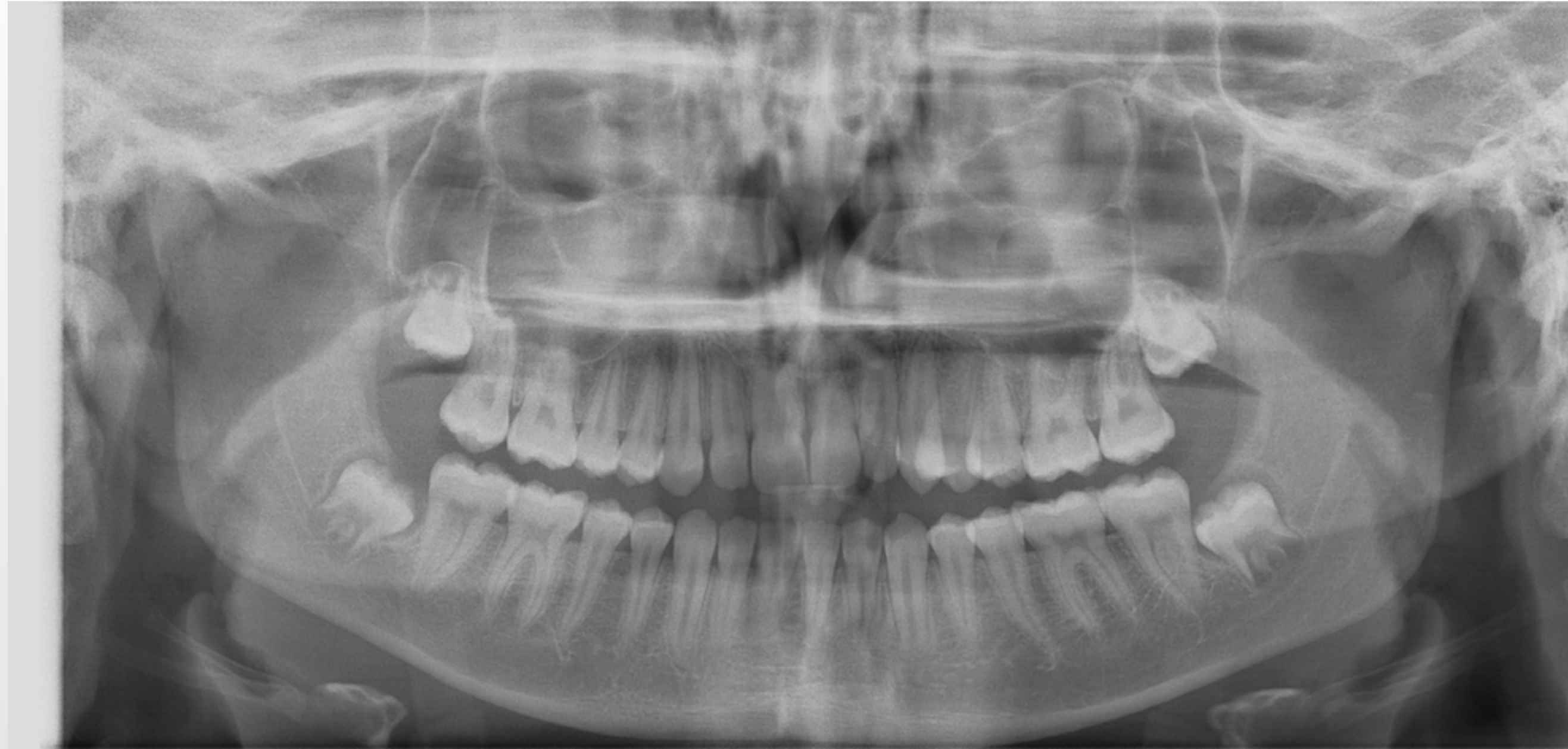**Retracted
buccal - left**



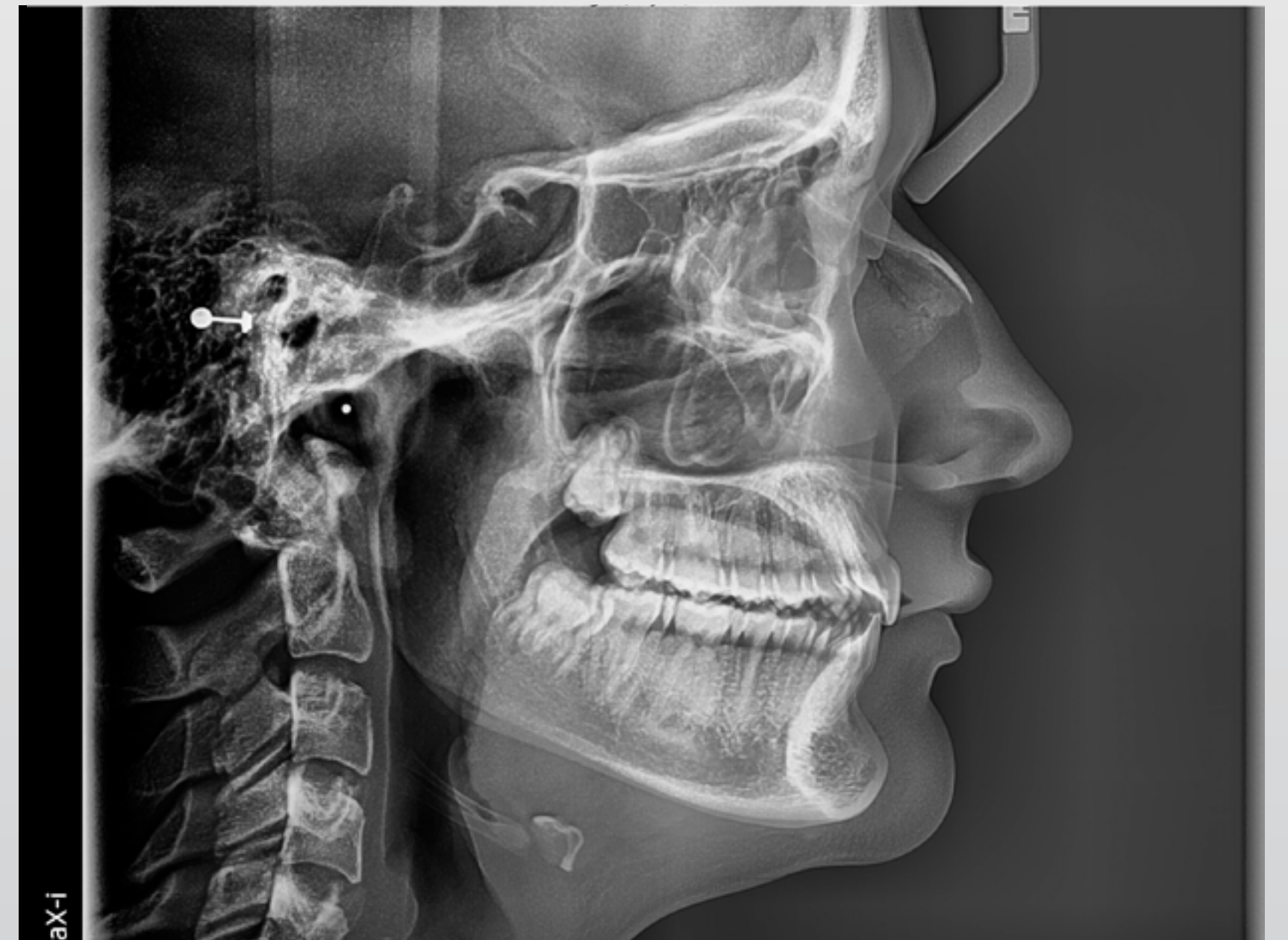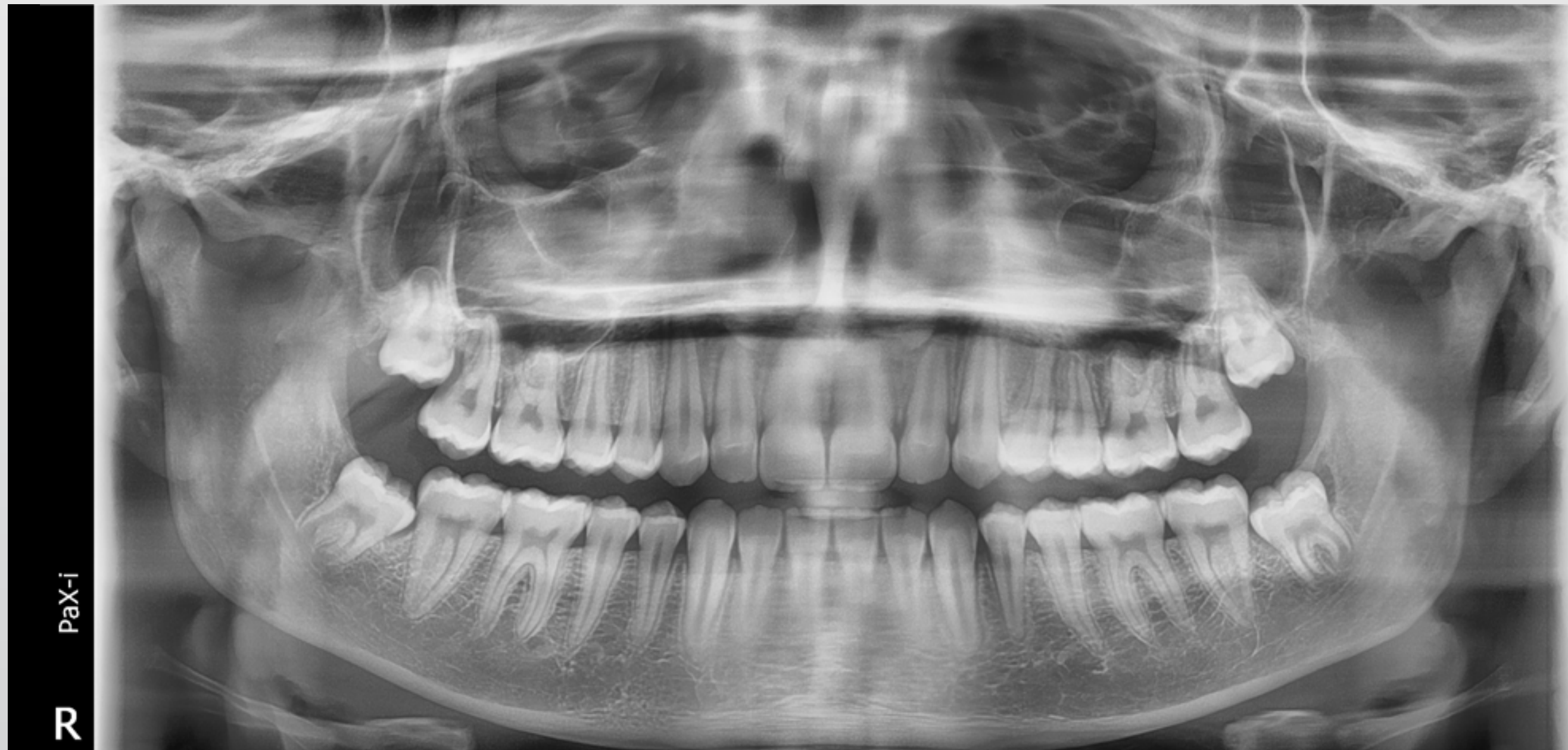Panoramic radiograph

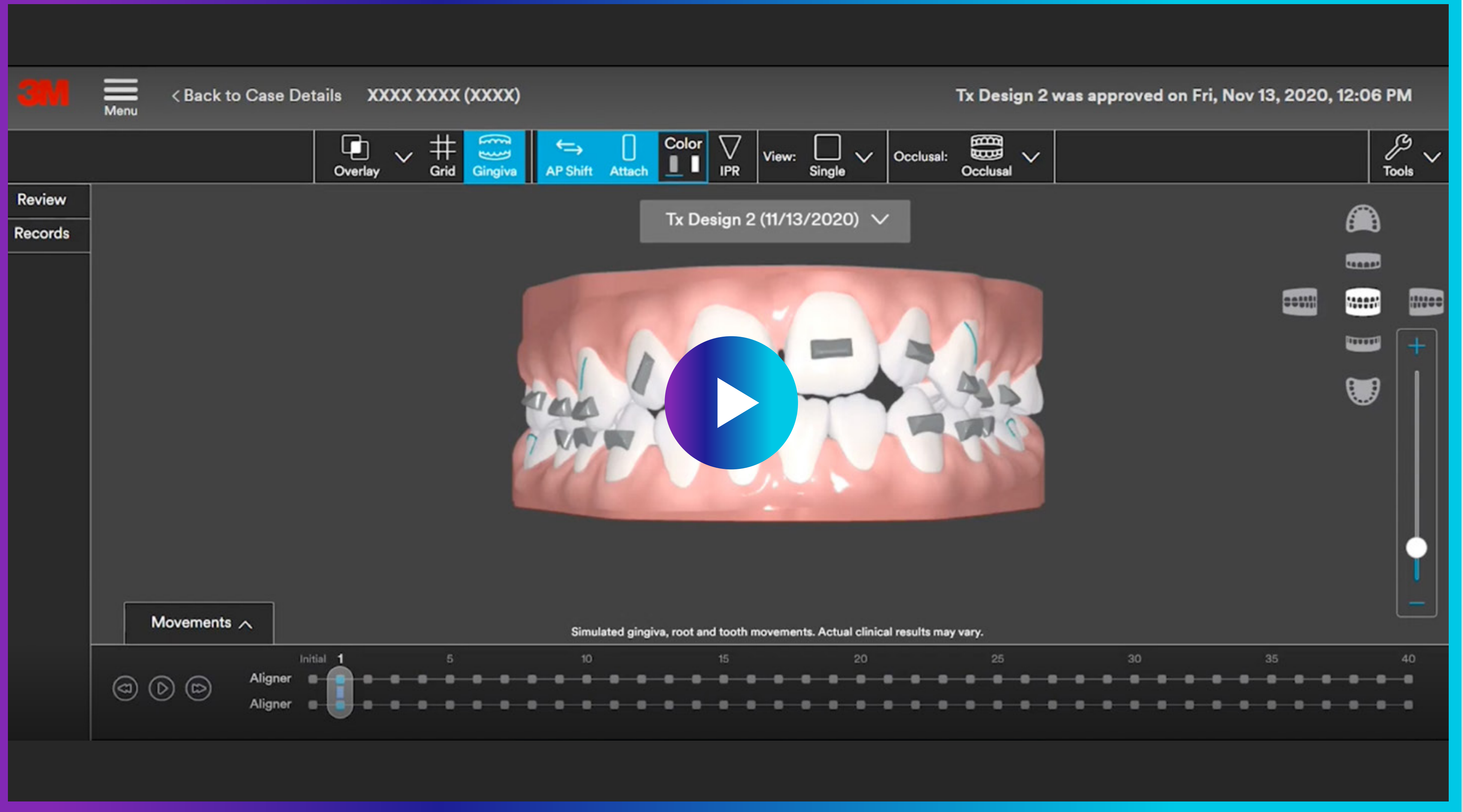
Cephalometric radiograph

Initial



Final





Tx Design Video


- Treatment Plan
- Attachment Strategy
- Key Movements
- Summary of Final Results

[Click here](#) to watch 14:51 minute video.

Ready to learn more?



Discover our proprietary new Clarity Aligners Flex Material!



See more cases from your peers on our Clinical Cases website!



Learn more about the Clarity Aligners system!



Rediscover the Oral Care Portal, submit a case today!