

**Case Brief:**

# Bonding with 3M™ Clarity™ Precision Grip Attachments

**Age:** 34

**Chief concern:** “Straighten front teeth and close upper spacing” was the patient’s initial request. End goal/plan after discussing with dentist was to distribute upper spacing to allow for veneers/crowns from Upper 4-4.

**Case diagnostics:** Mild skeletal class III, Dent class I. Missing lower 5s/retained lower Es. Small/hypoplastic upper 542|245. “Cosmetic” bonding remains on UL2, LL3,4. Bonding on UL3 were removed, patient refused to remove others pre-treatment. 50% deep OB, minimal OJ due to class III pattern.

**Tx Plan:** Not an ideal plan as patient refused to remove all old bondings prior to treatment and will plan veneers/crowns on upper 4-4 after orthodontic treatment, which will still leave him with spaces mesial to upper 5s. Space opened UR2 for veneer to be same size as bonding on UL2. Lower space closure and IPR lower 3-3 to allow lower anterior retraction which in turn will allow more upper space reduction. Lower Es will be maintained.

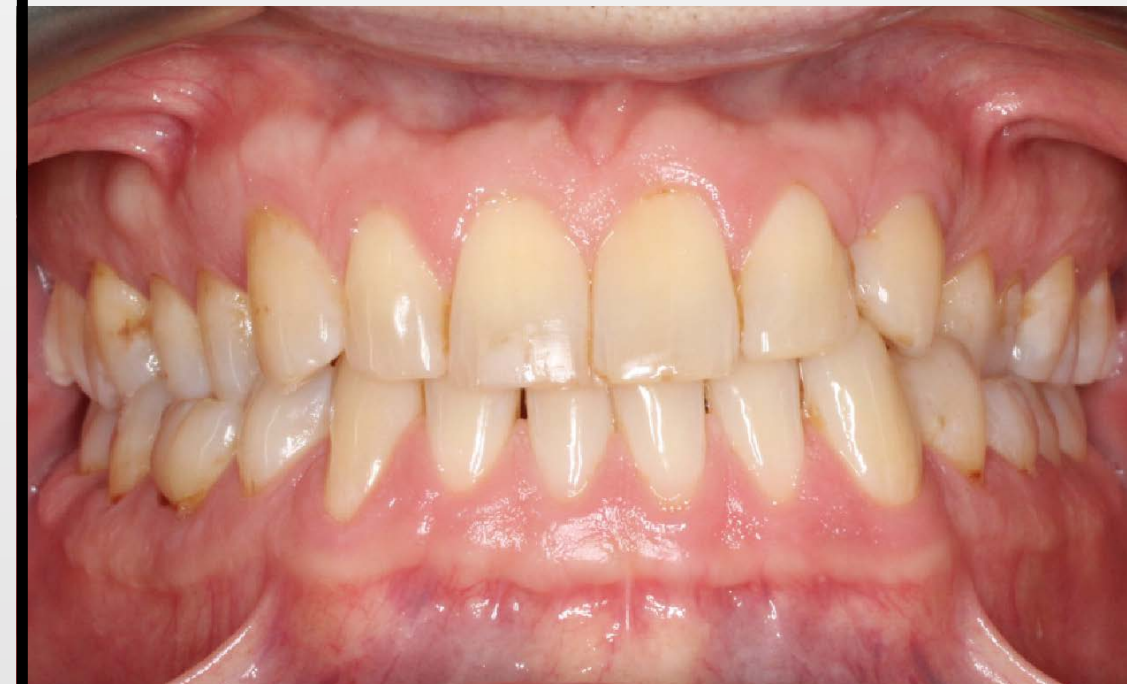**Bonding Procedure:** 10-15 minutes for bonding preparation and bonding procedure.

**Case courtesy of:**

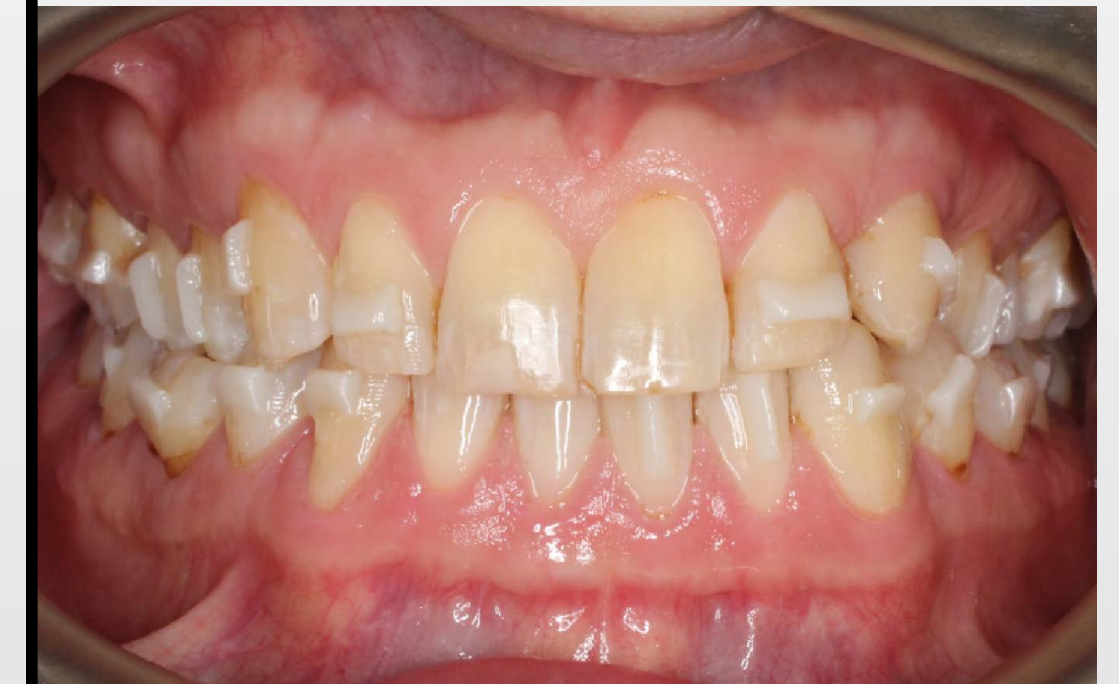Dr. Doug Palaganas, Consultant for Solventum  
New York, NY – US

## Retracted anterior

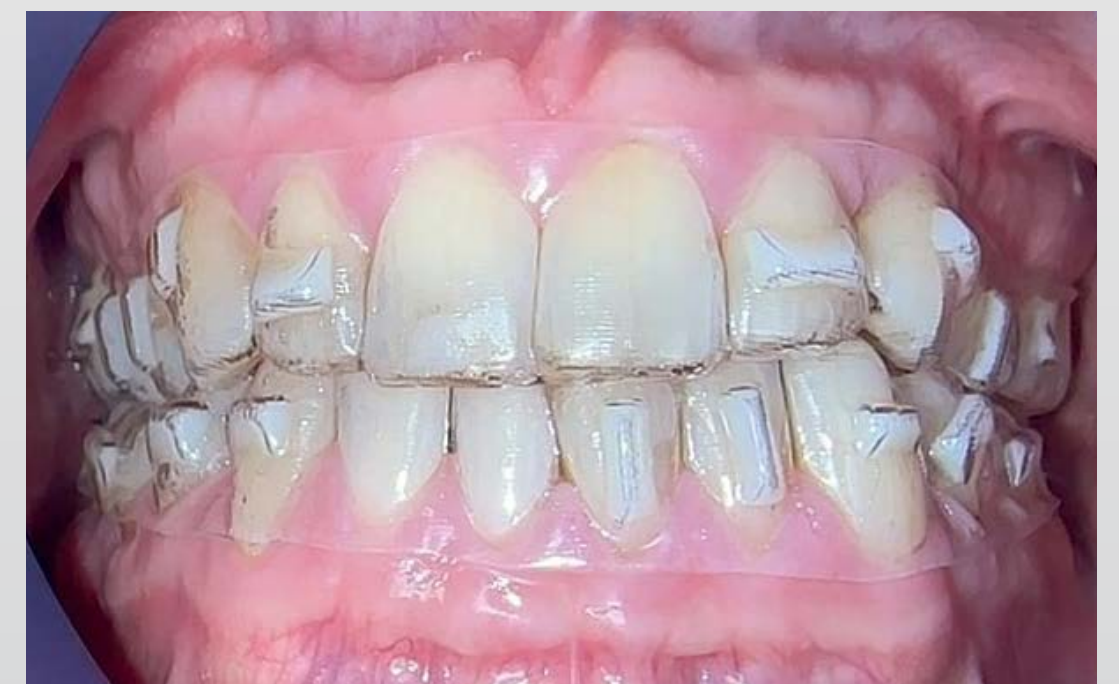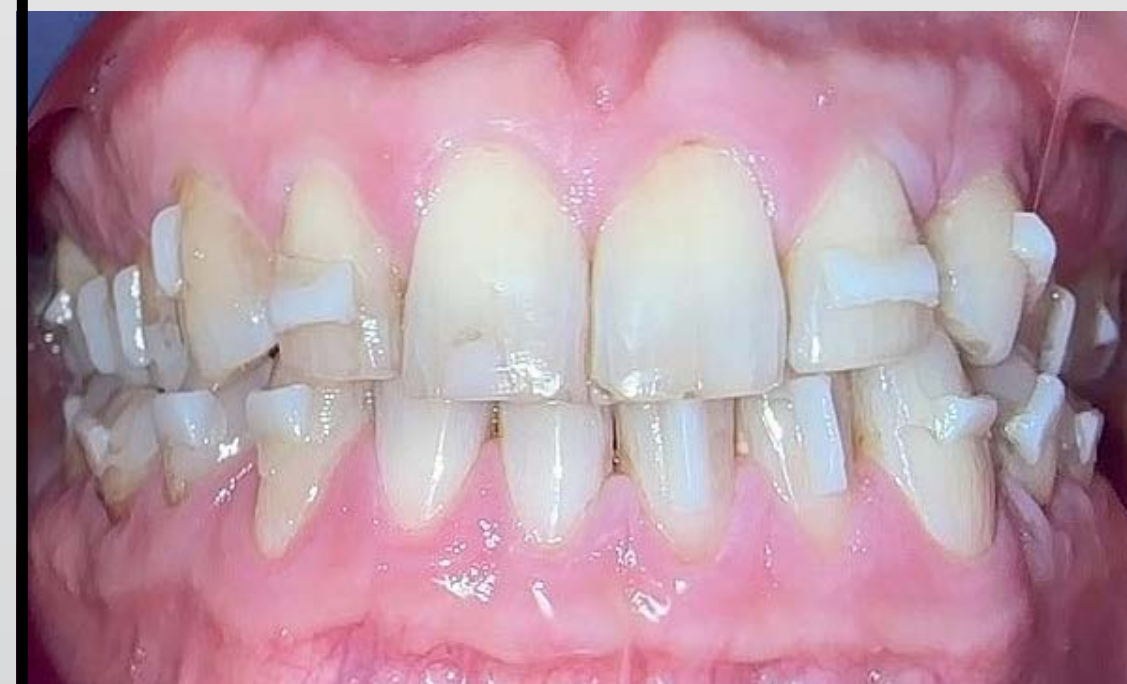**Pre-bonding**



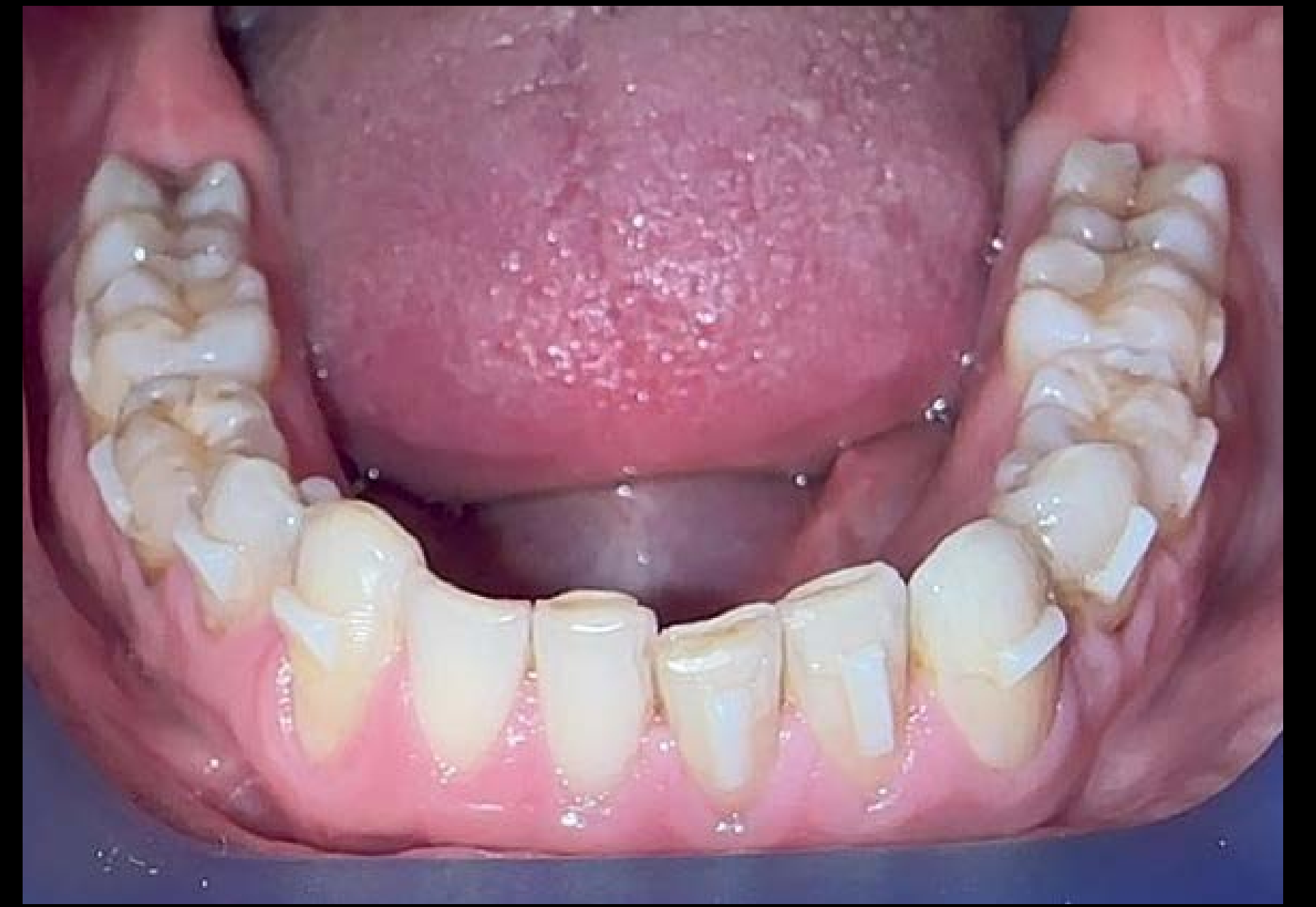
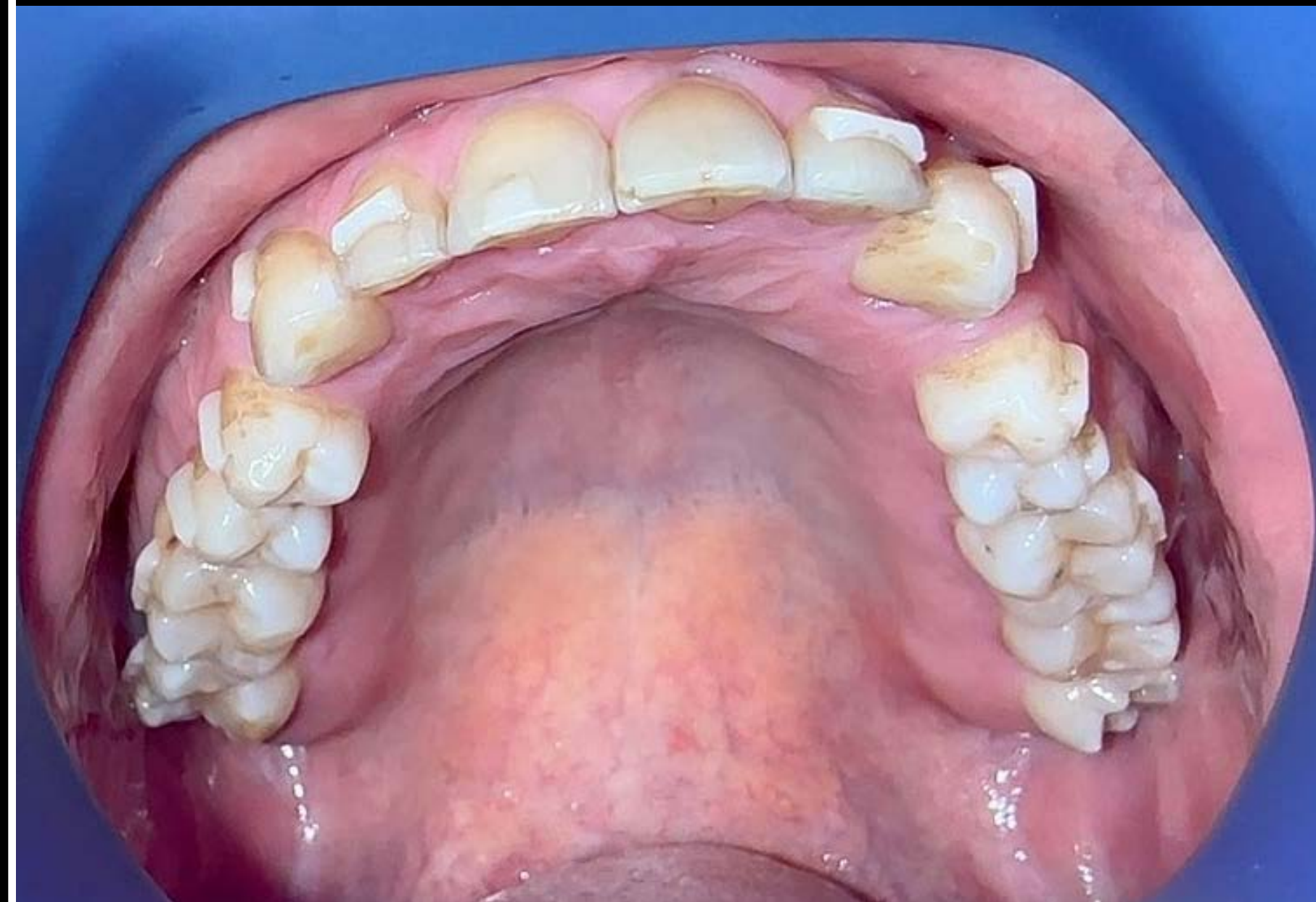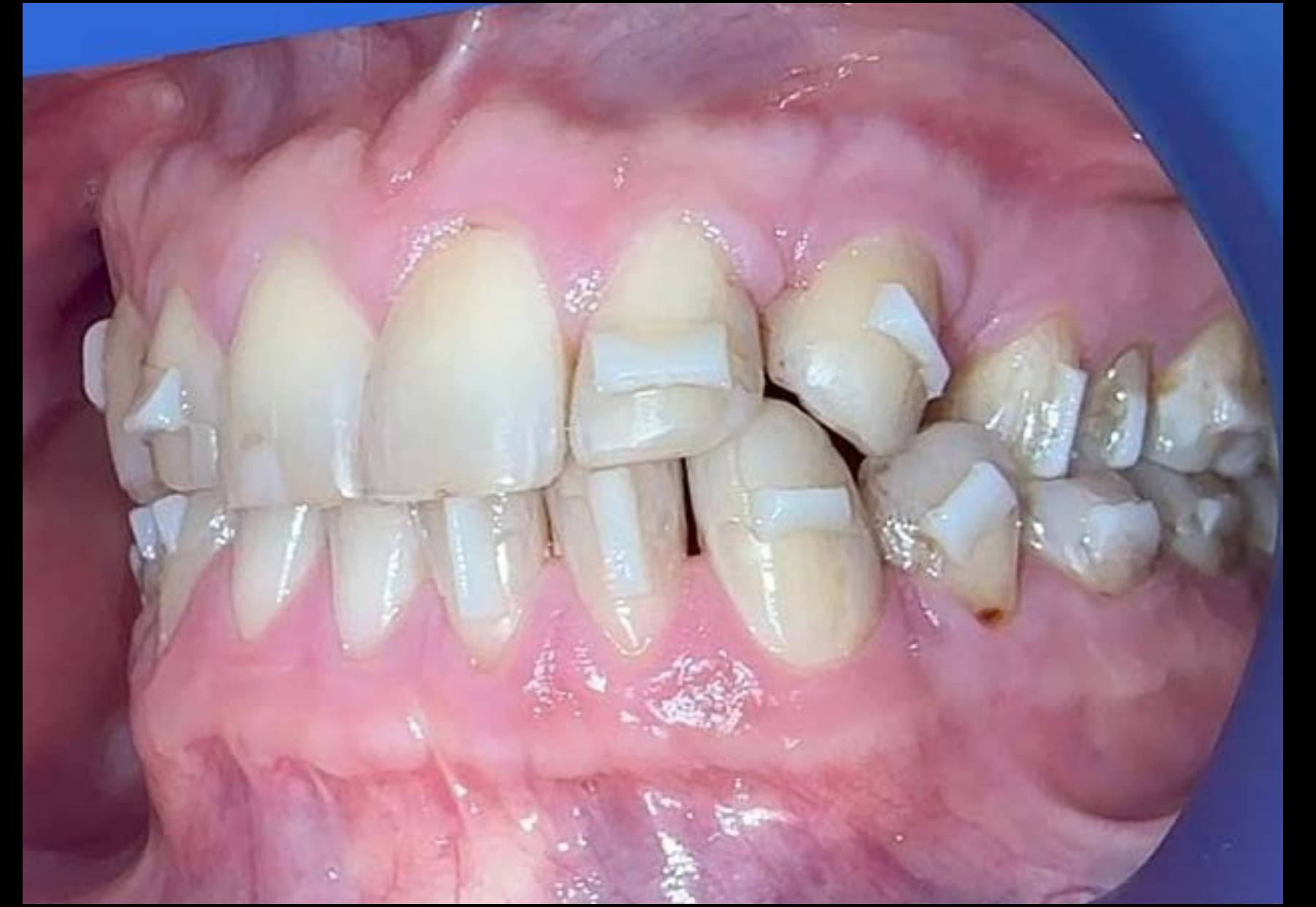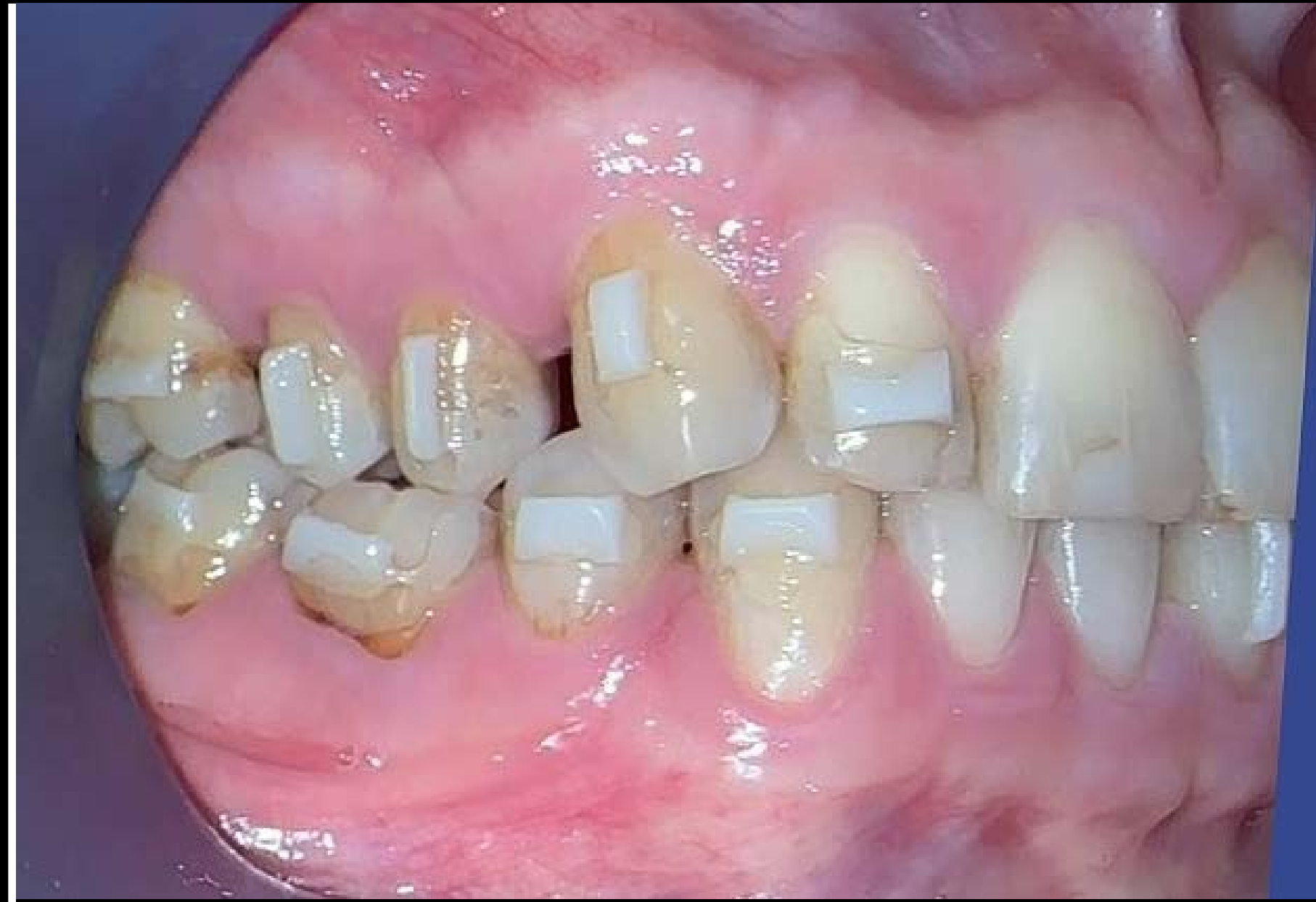**Bonded attachments**



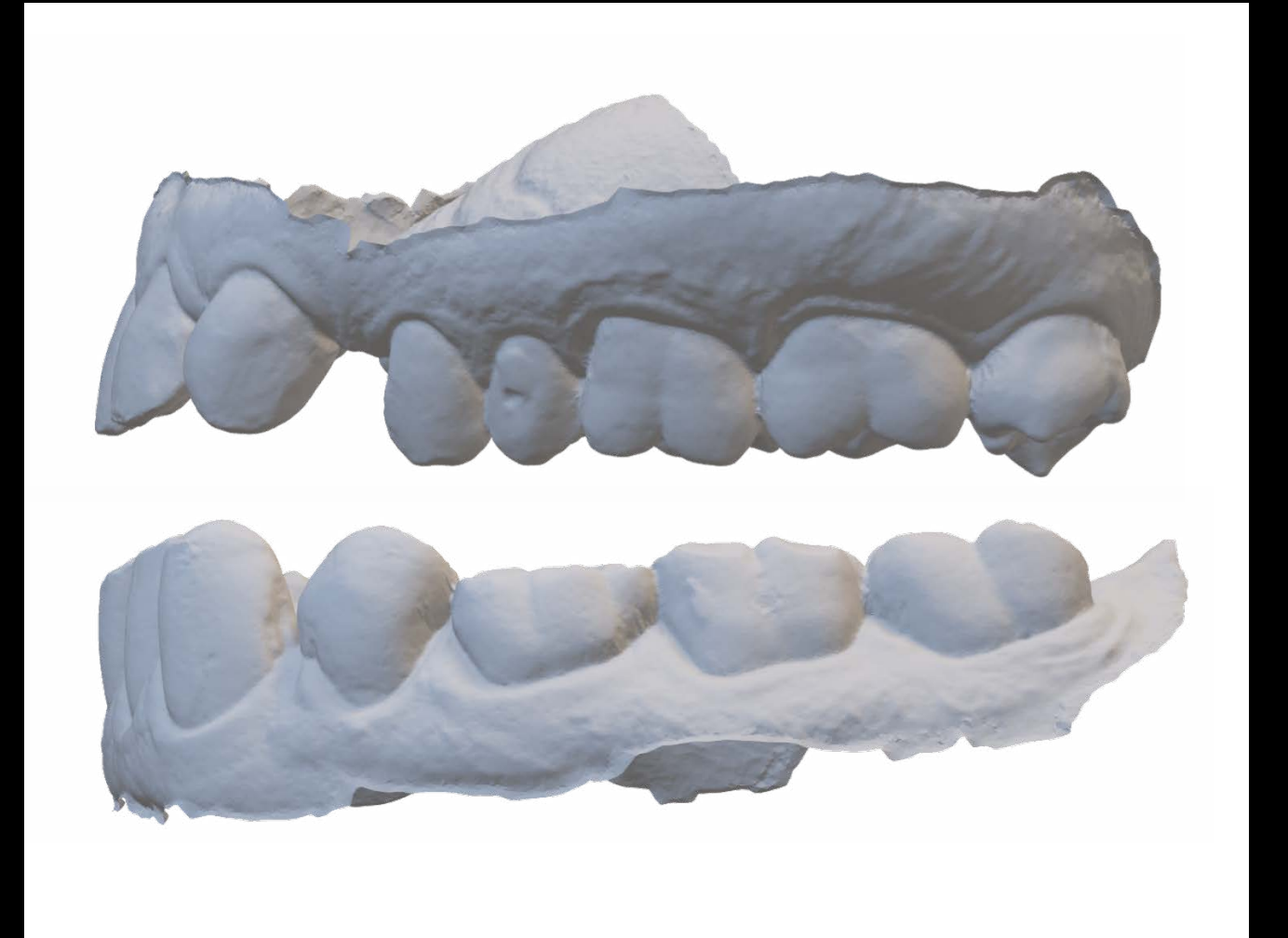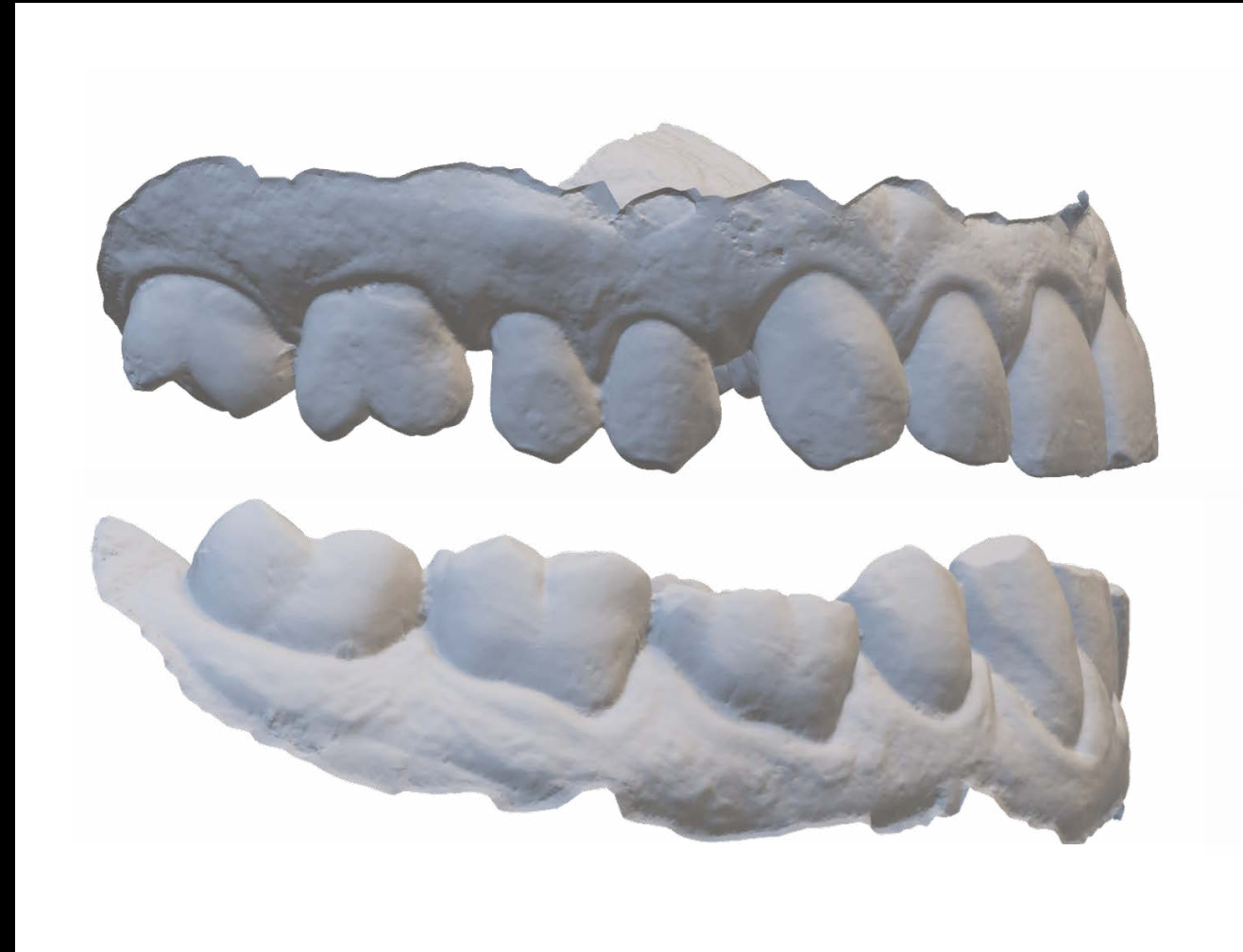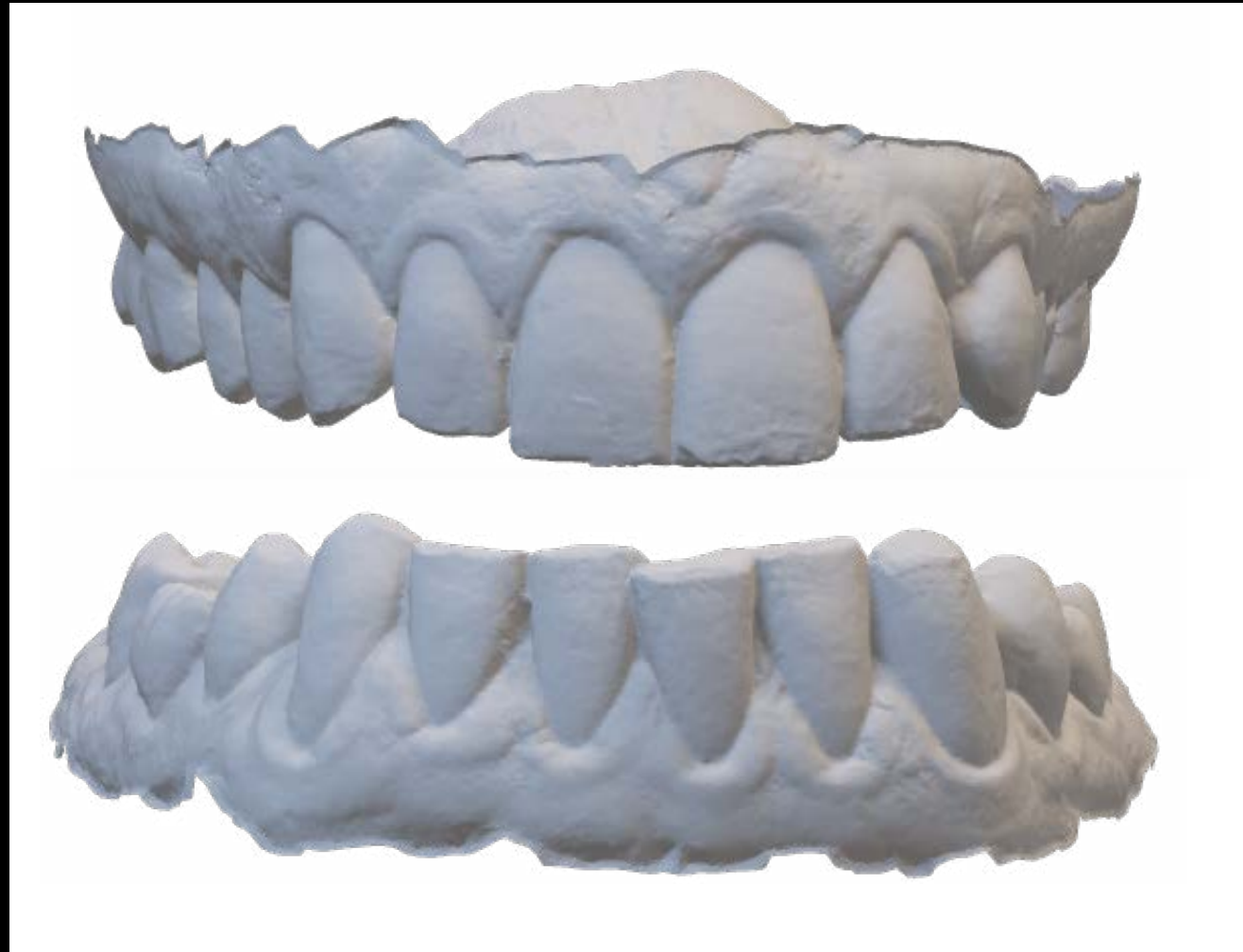**1 month post-bonding**



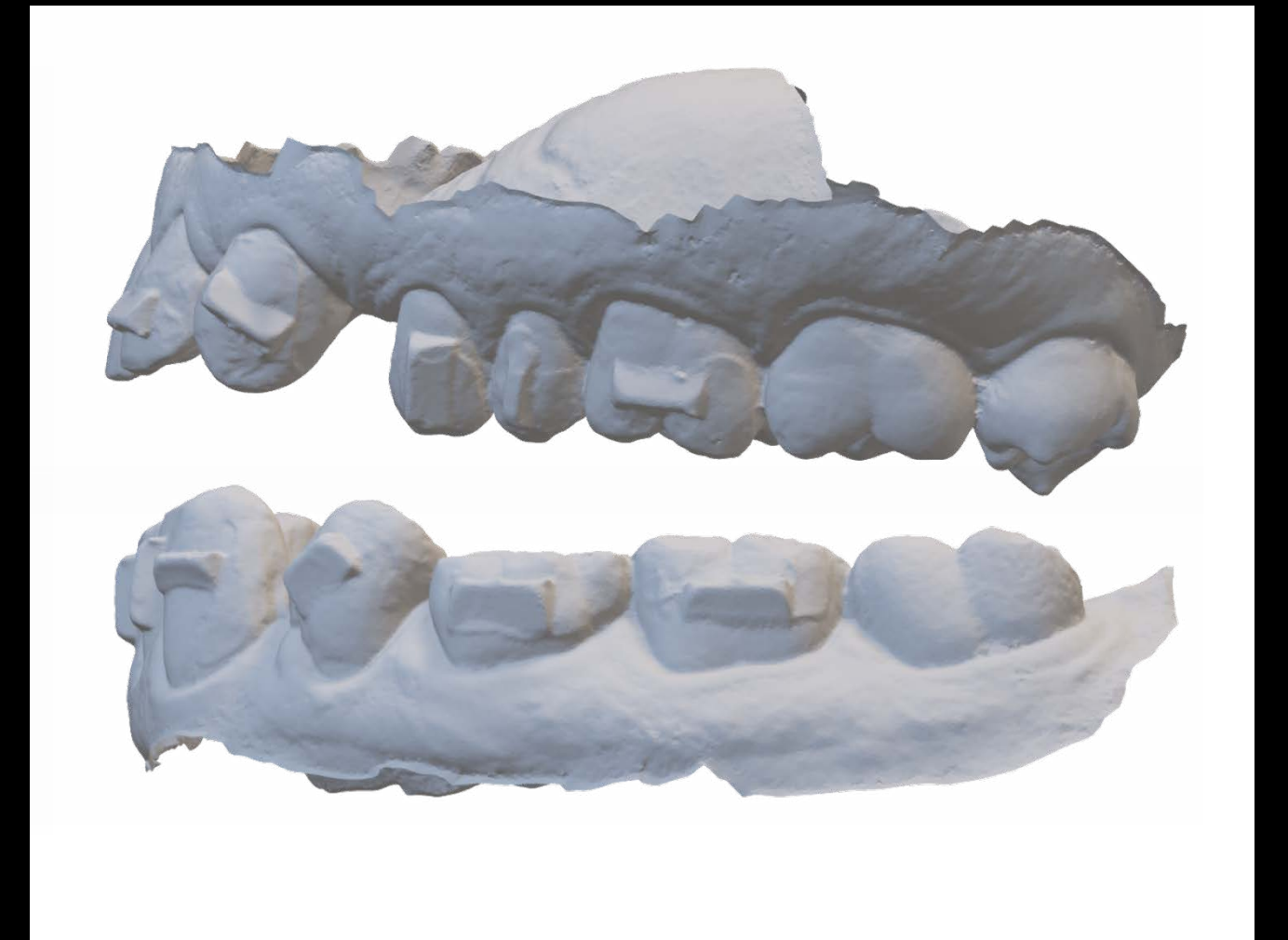
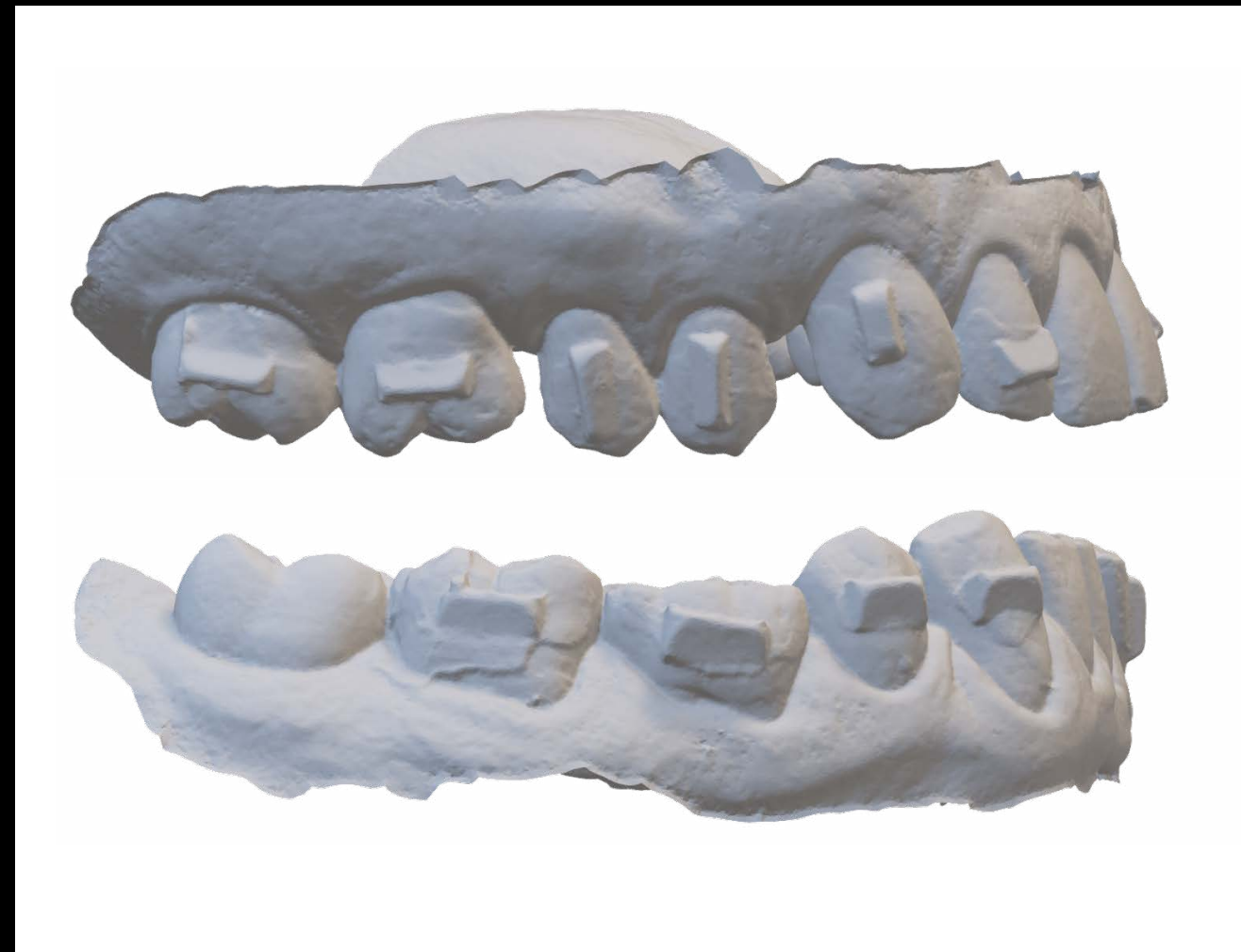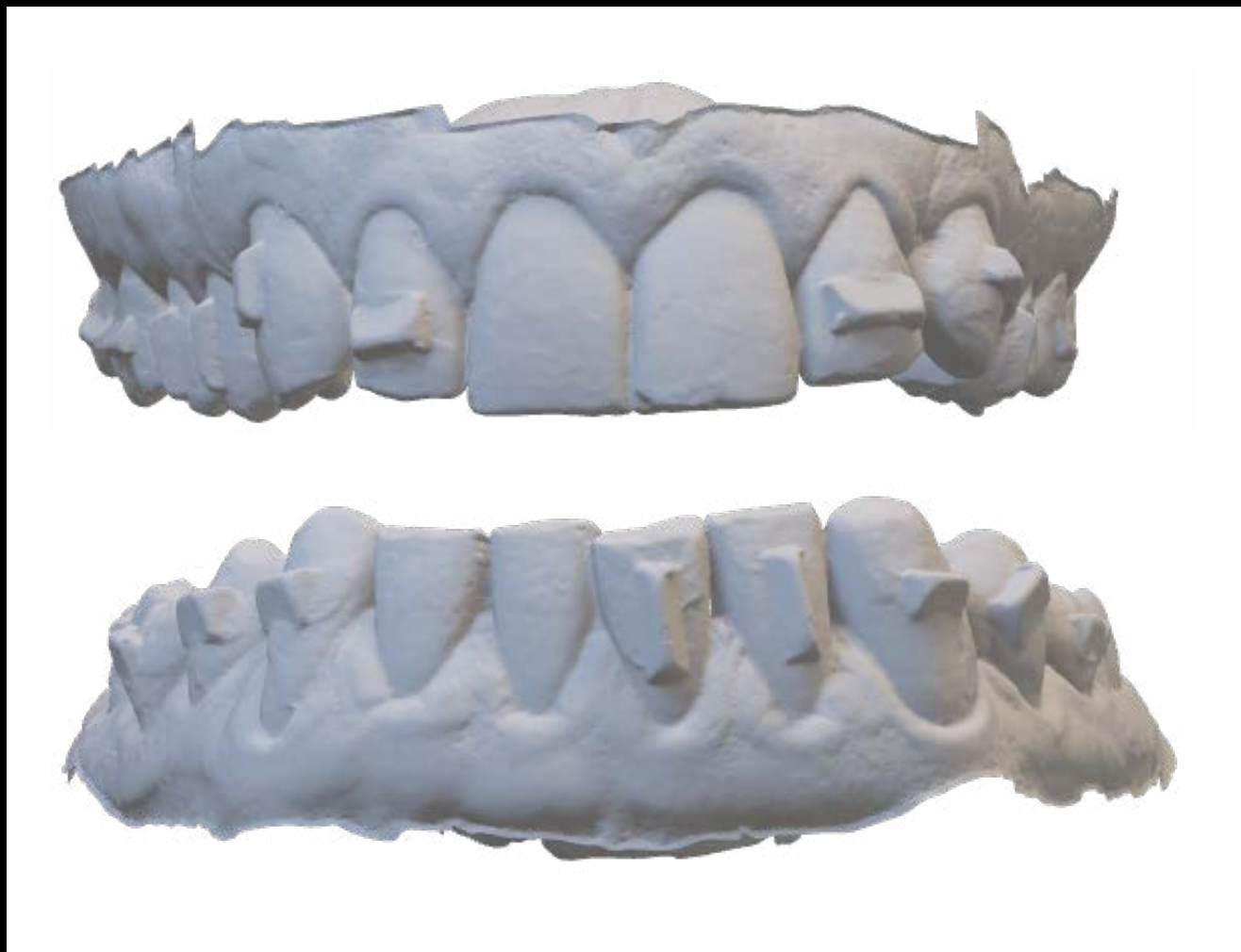1 month  
post-bonding



Pretreatment  
(scan)



Post-bonding  
(scan)





Learn more at [\*\*3M.ca/ClarityAligners\*\*](https://3M.ca/ClarityAligners)