

Case Brief:

# Bonding with 3M™ Clarity™ Precision Grip Attachments

Age: 19y 1m

Chief concern: Spacing

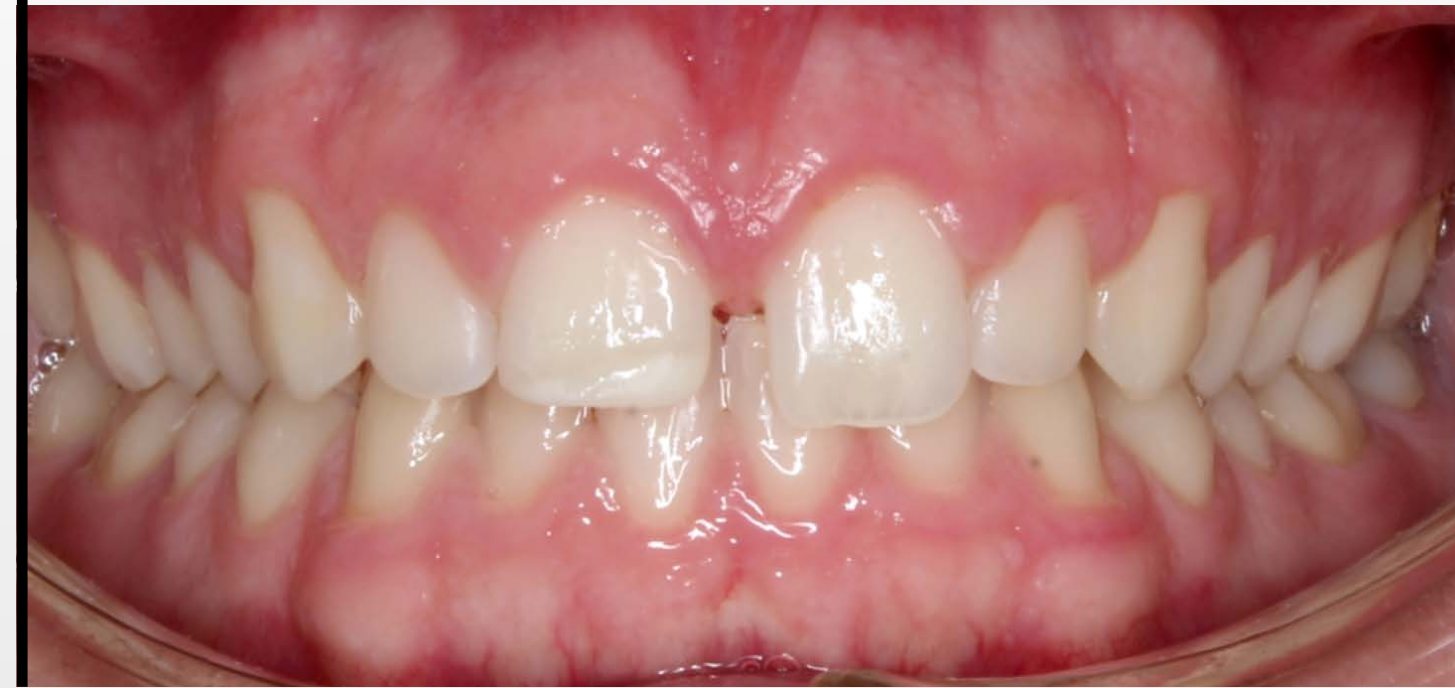**Case diagnostics:** Orthognathic maxilla/mandible;  
Class I; mild maxillary spacing; moderate mandibular  
crowding; coincident midlines, excess overjet, and  
deep bite

**Bonding Procedure:** 7 mins

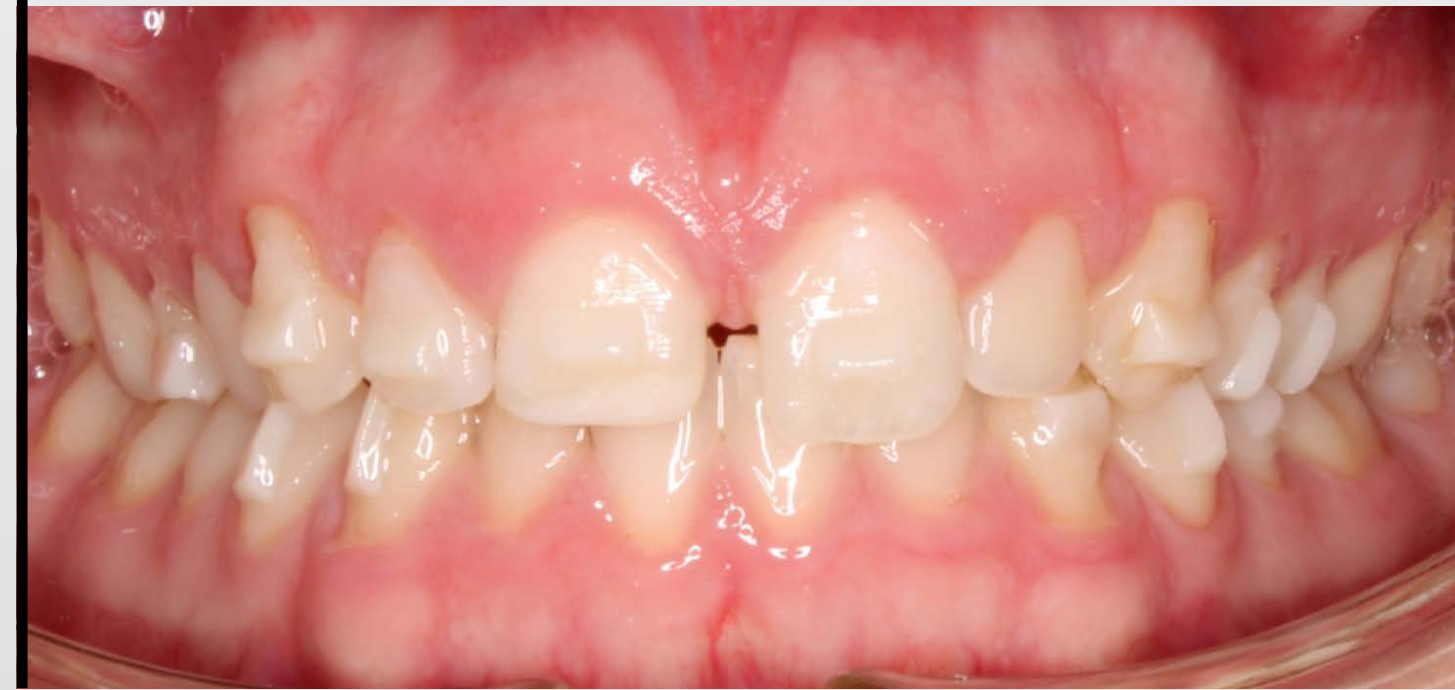**Case courtesy of:**  
Dr. Matt Dunn, Consultant for Solventum  
Arizona – US

Retracted  
anterior

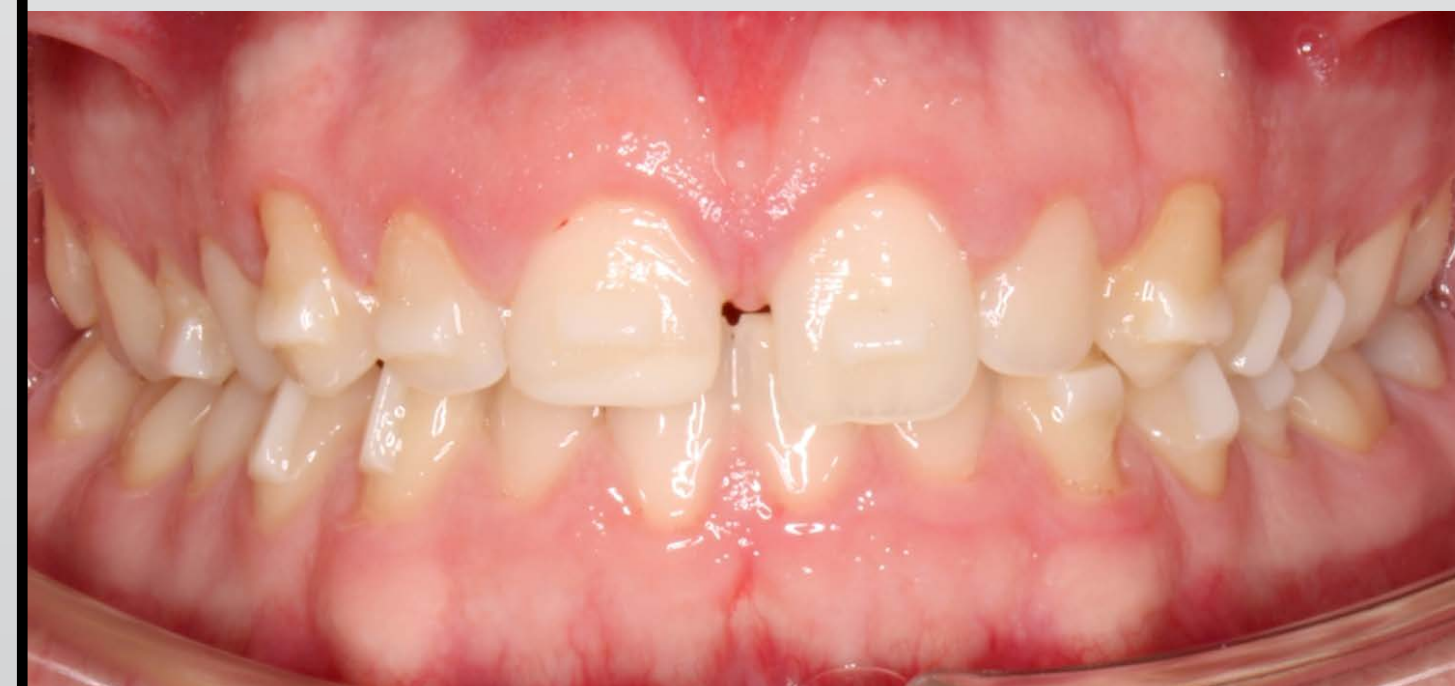Pre-bonding



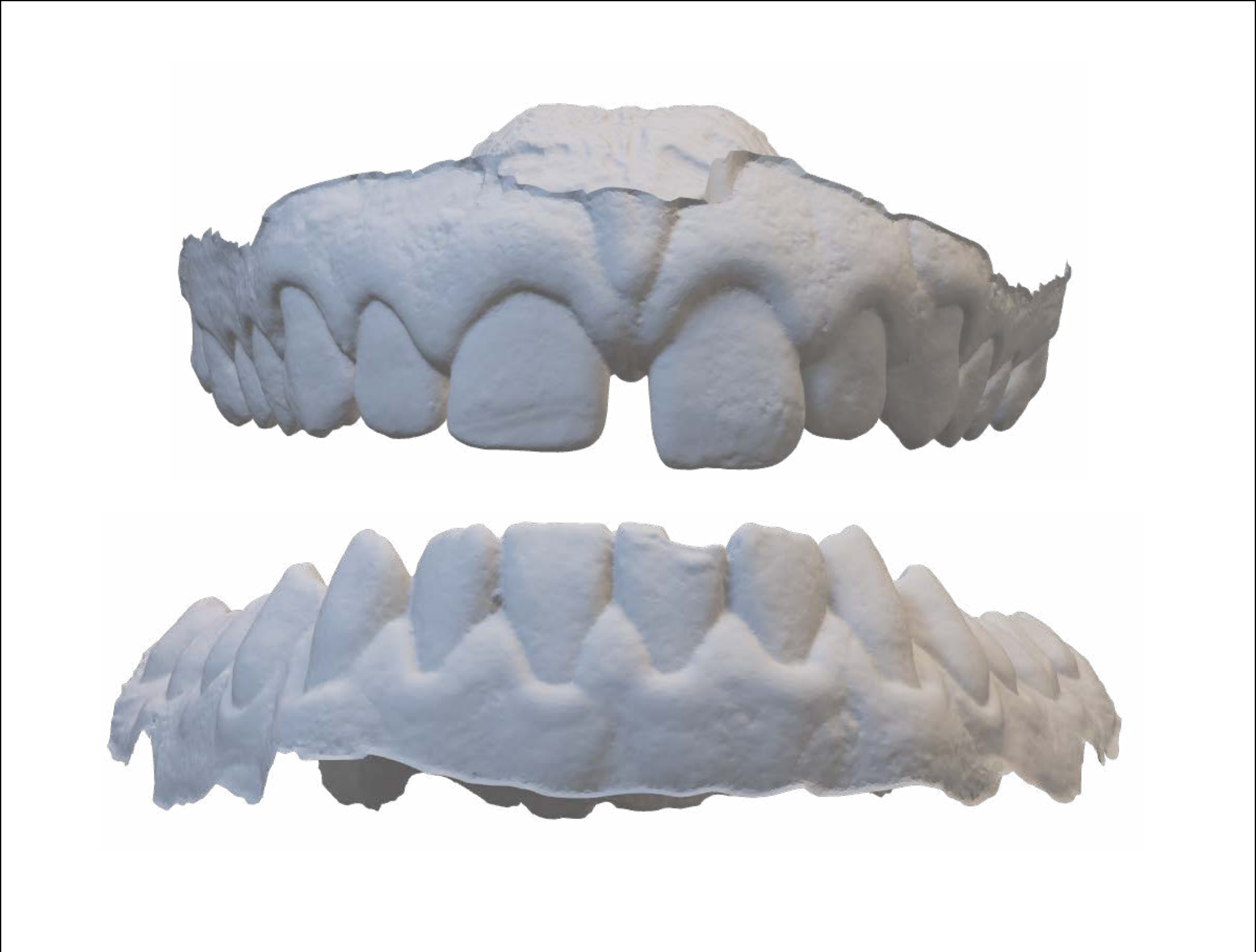Post-bonding / 11-14-2023



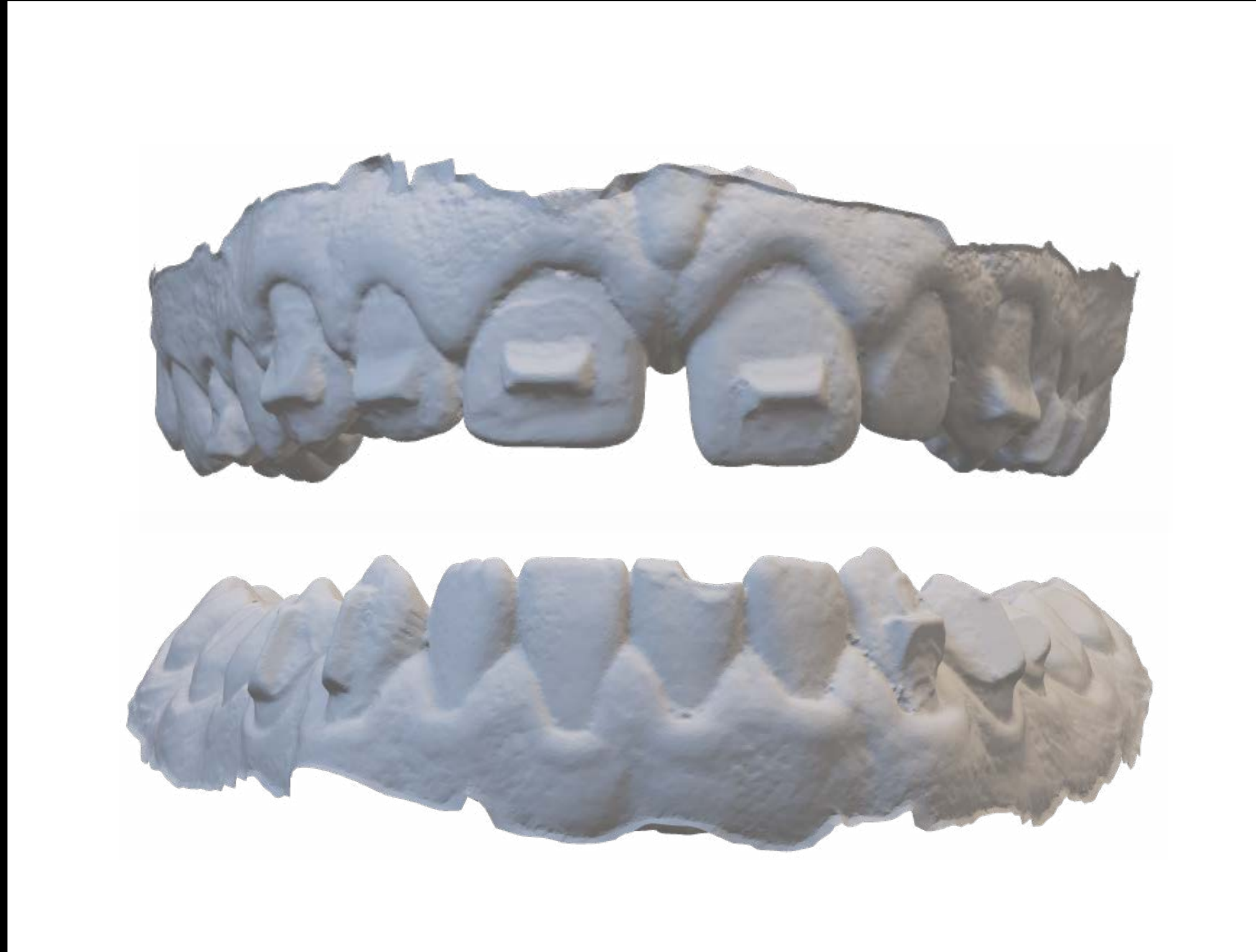
Post-bonding / 12-14-2023 / 1 month



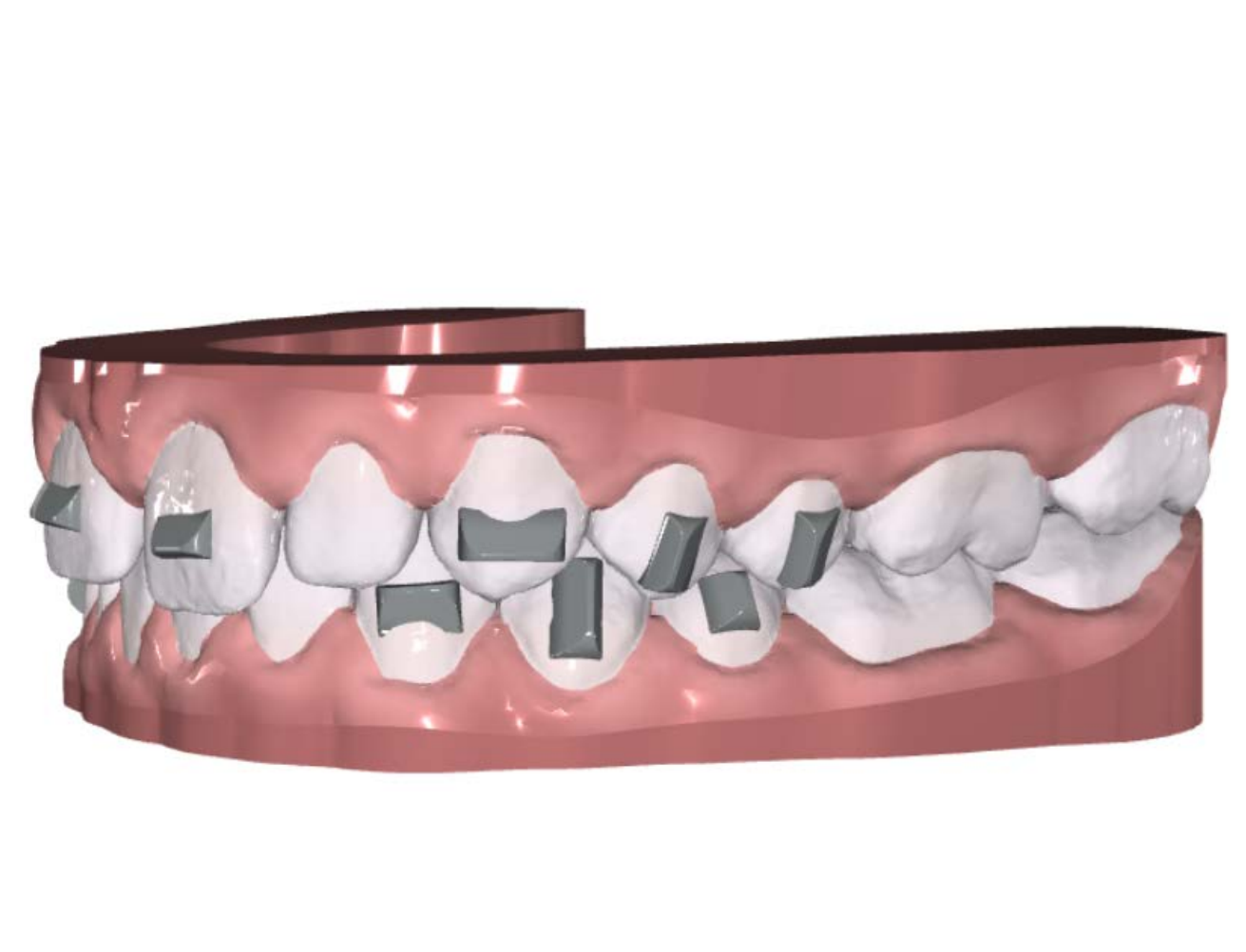
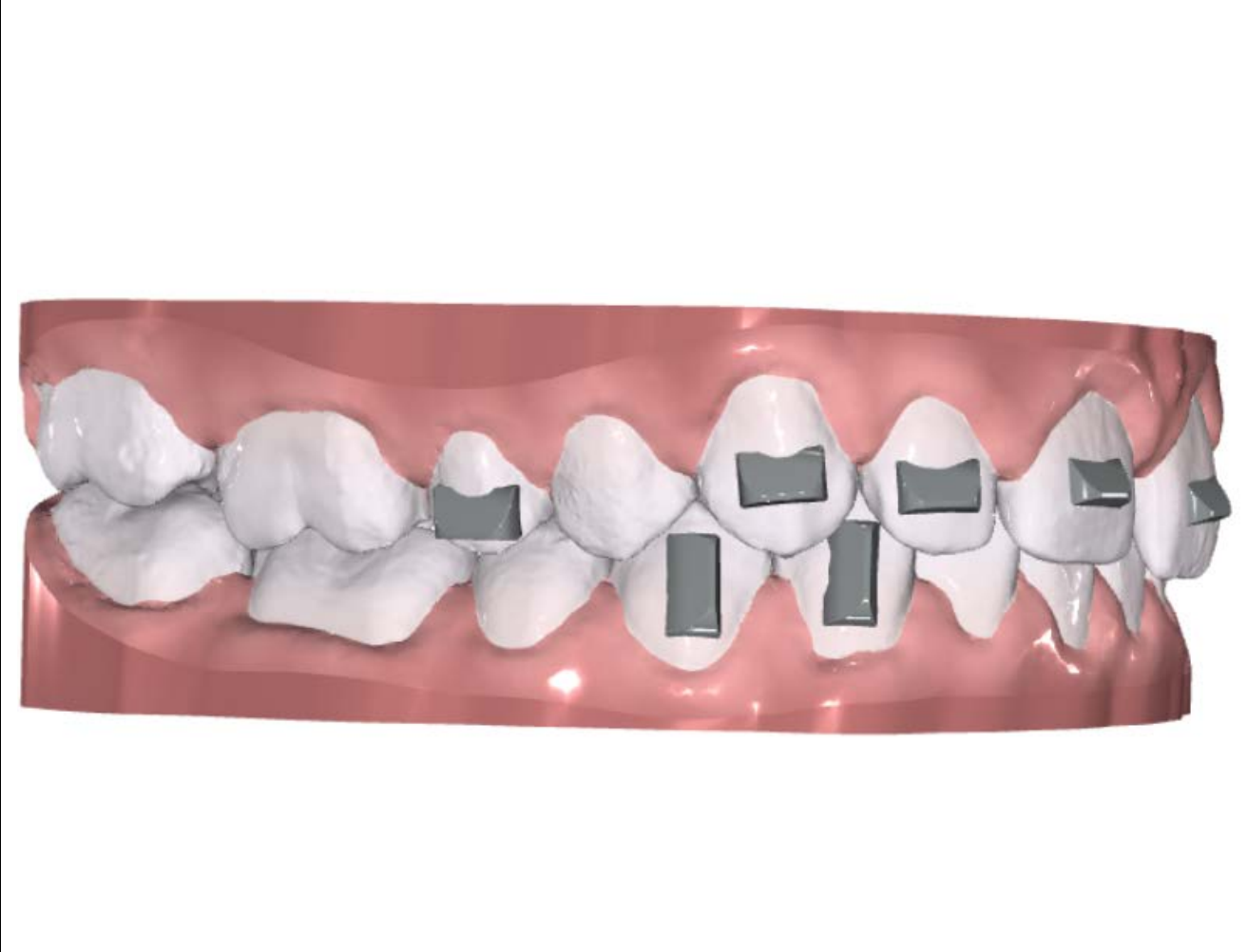
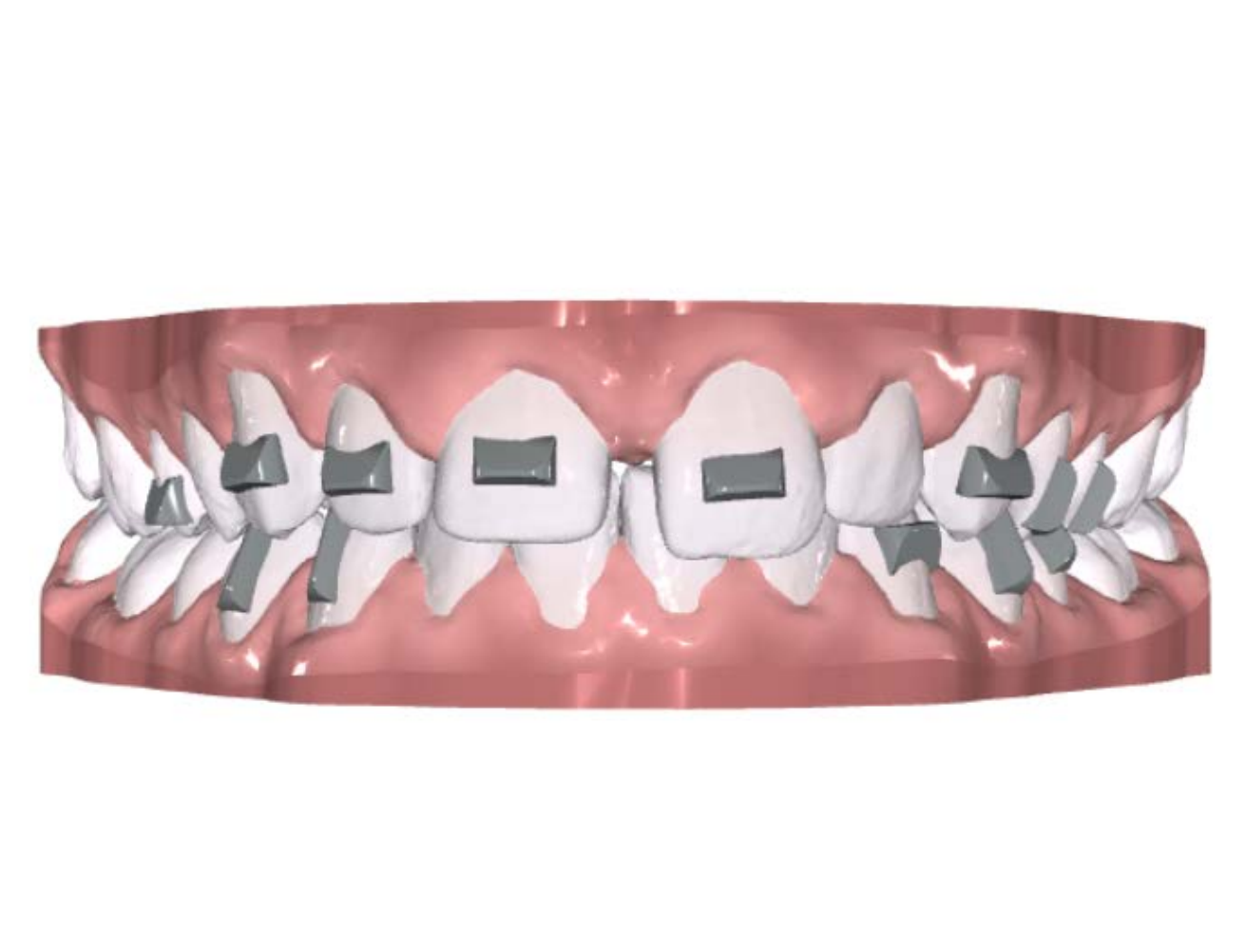Pretreatment (scan)



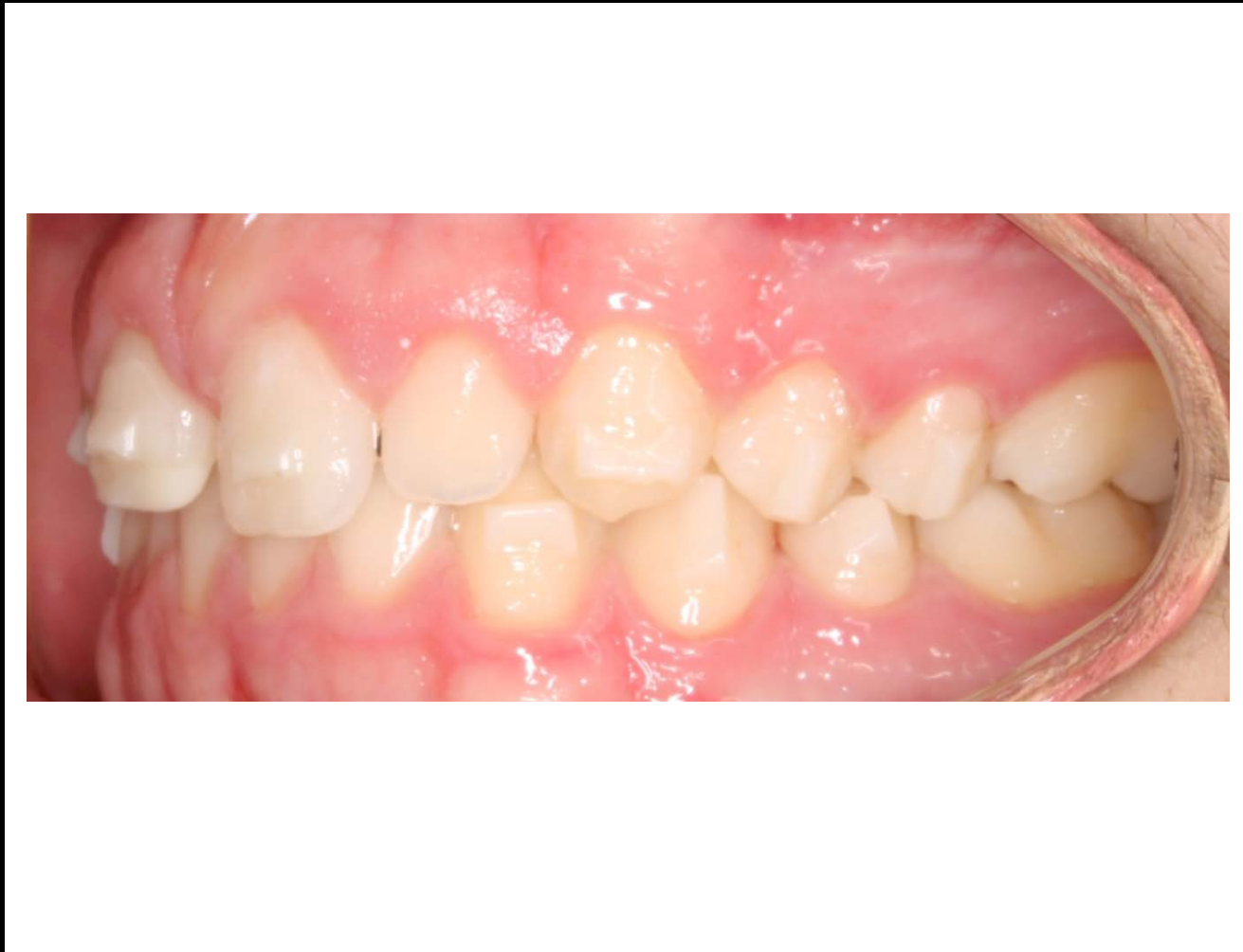
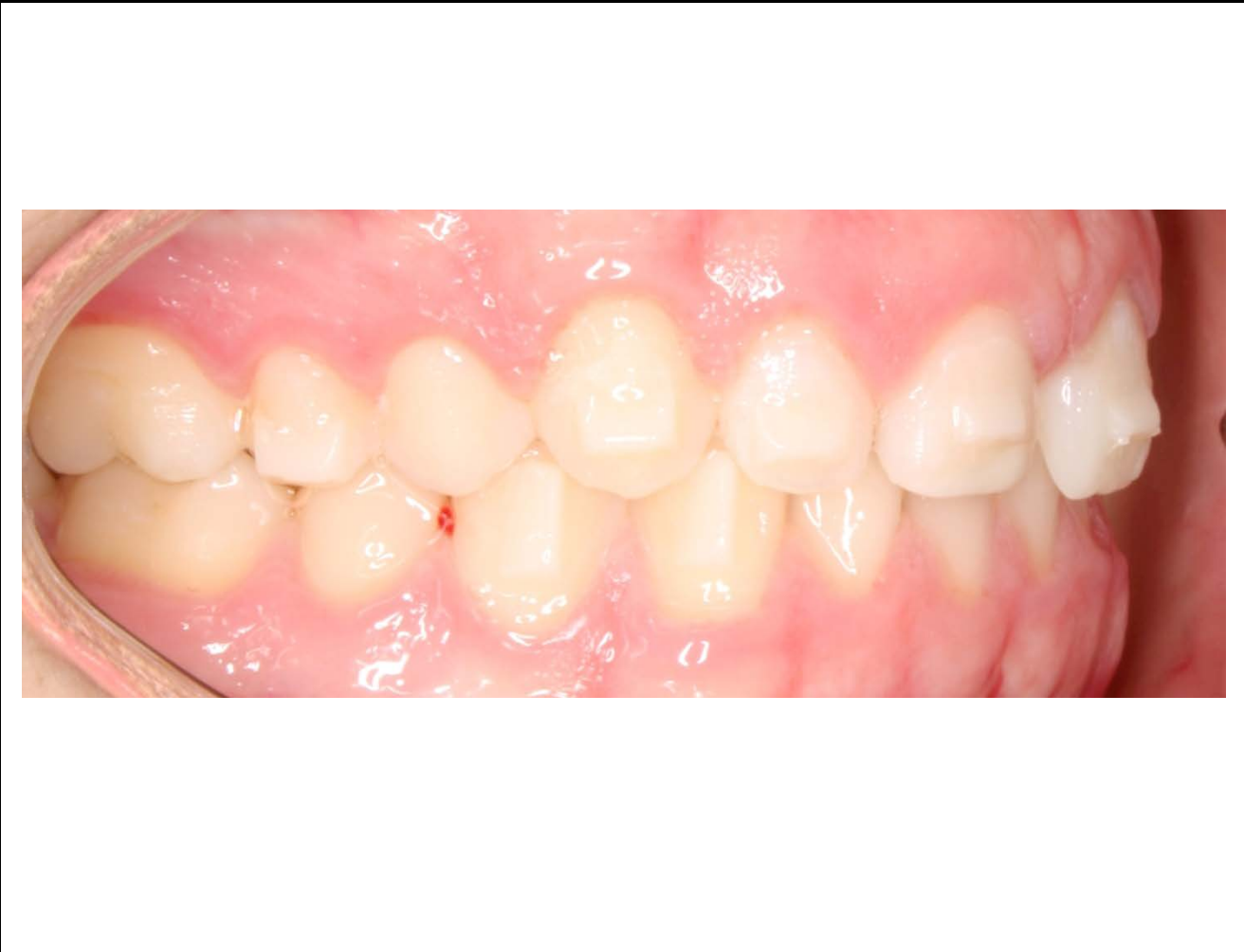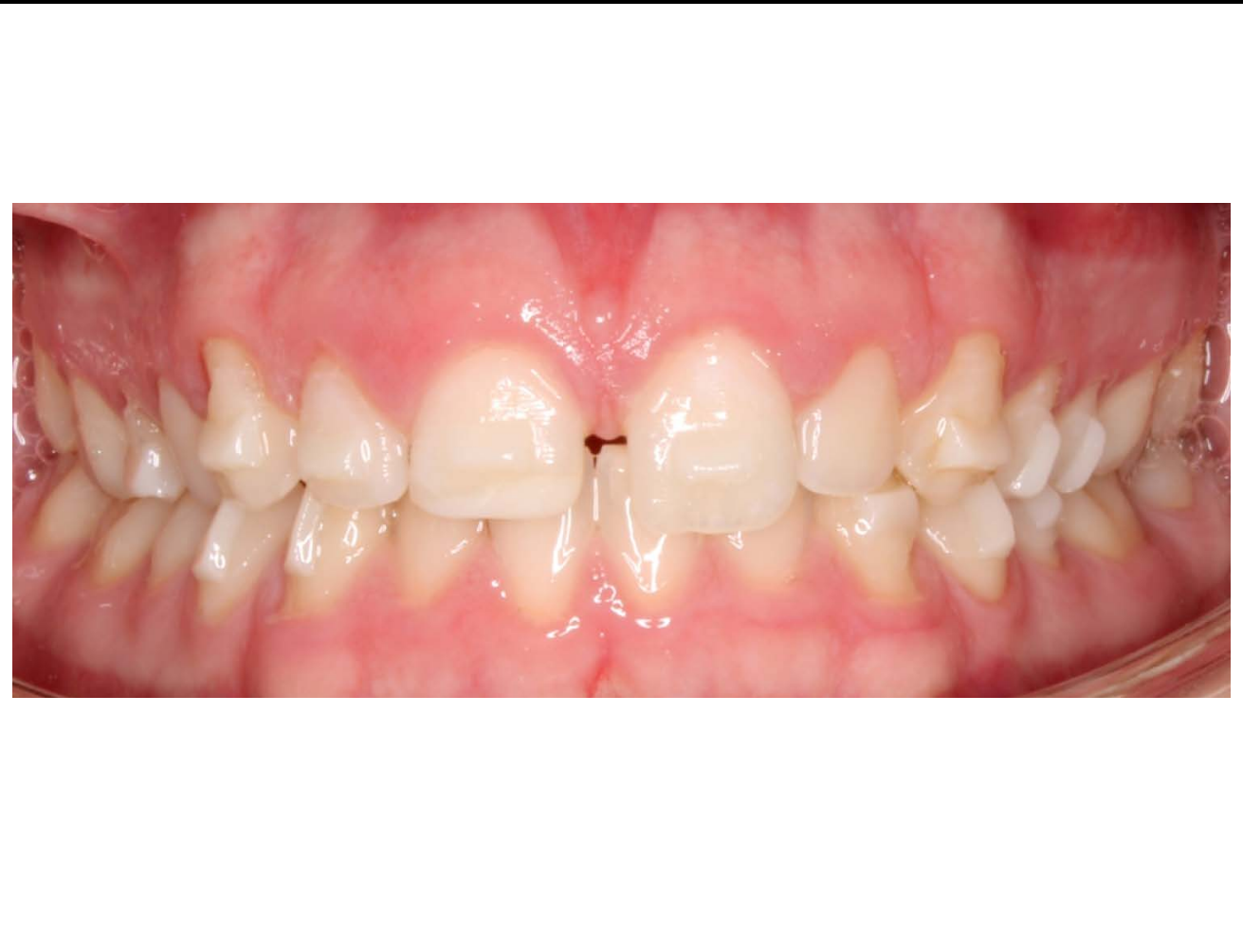Post-bonding (scan)



Tx Design



Post-bonding





Learn more at [\*\*3M.ca/ClarityAligners\*\*](https://3M.ca/ClarityAligners)