

Case Brief:

Bonding with 3M™ Clarity™ Precision Grip Attachments

Age: 53

Chief concern: “I want to straighten my teeth back out, especially the lower front teeth which got crowded after I stopped wearing my retainers a few years ago.” Patient had braces as a child, then aligners as an adult a number of years ago.

Case diagnostics: Skeletal class I, mild dental class II canine, full class II molar relationship. Previous extractions of upper first and lower left first premolars. Mild generalized buccal recession secondary to toothbrush abrasion. 5-6mm overjet, 25% deep over bite, mild upper and lower crowding.

Tx Plan: Accept/maintain class II occlusion, align and IPR upper anteriors for slight reduction in overjet.

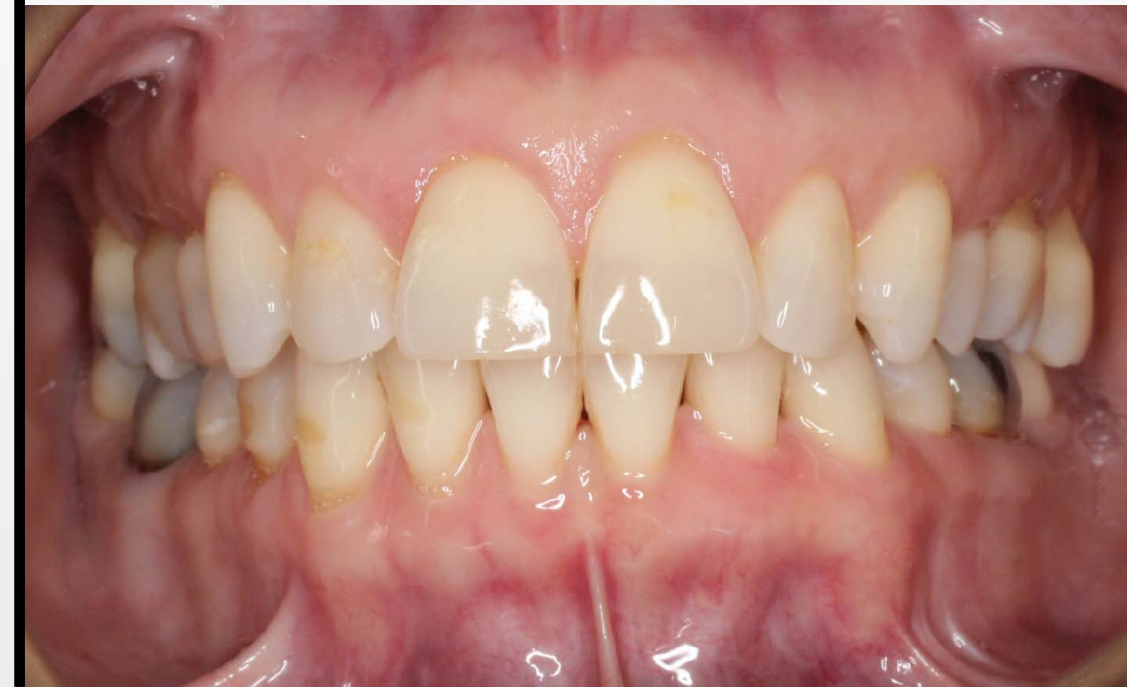Bonding Procedure: 10-15 minutes for bonding preparation and bonding procedure.

Case courtesy of:

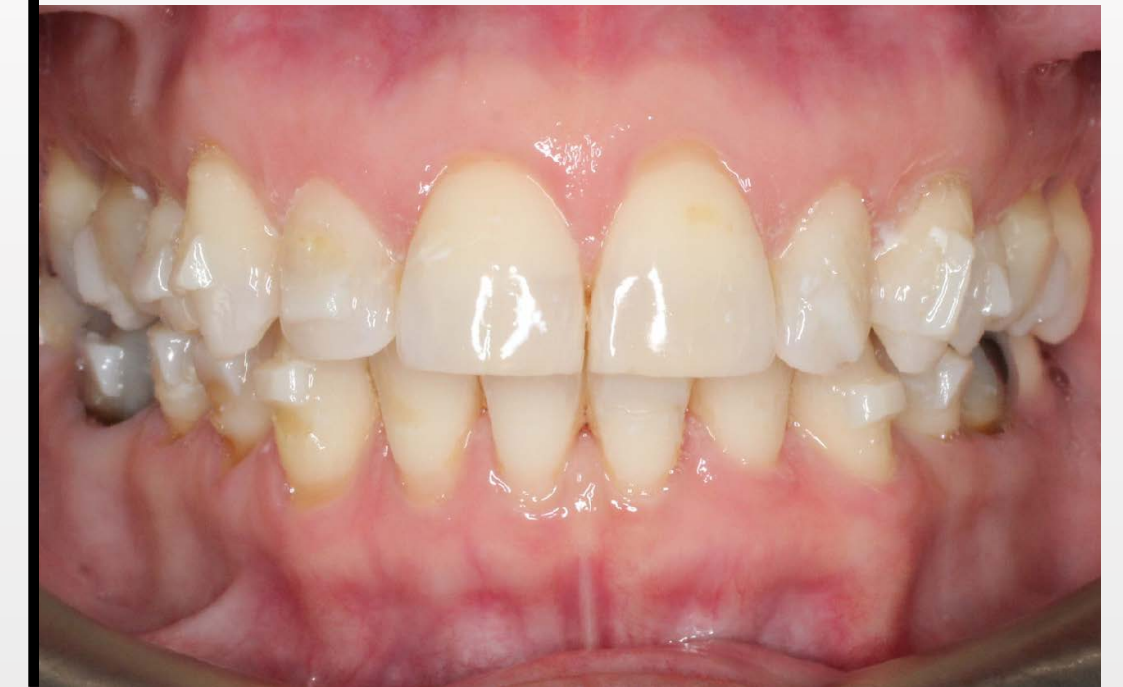Dr. Doug Palaganas, Consultant for Solventum
New York, NY – US

Retracted anterior

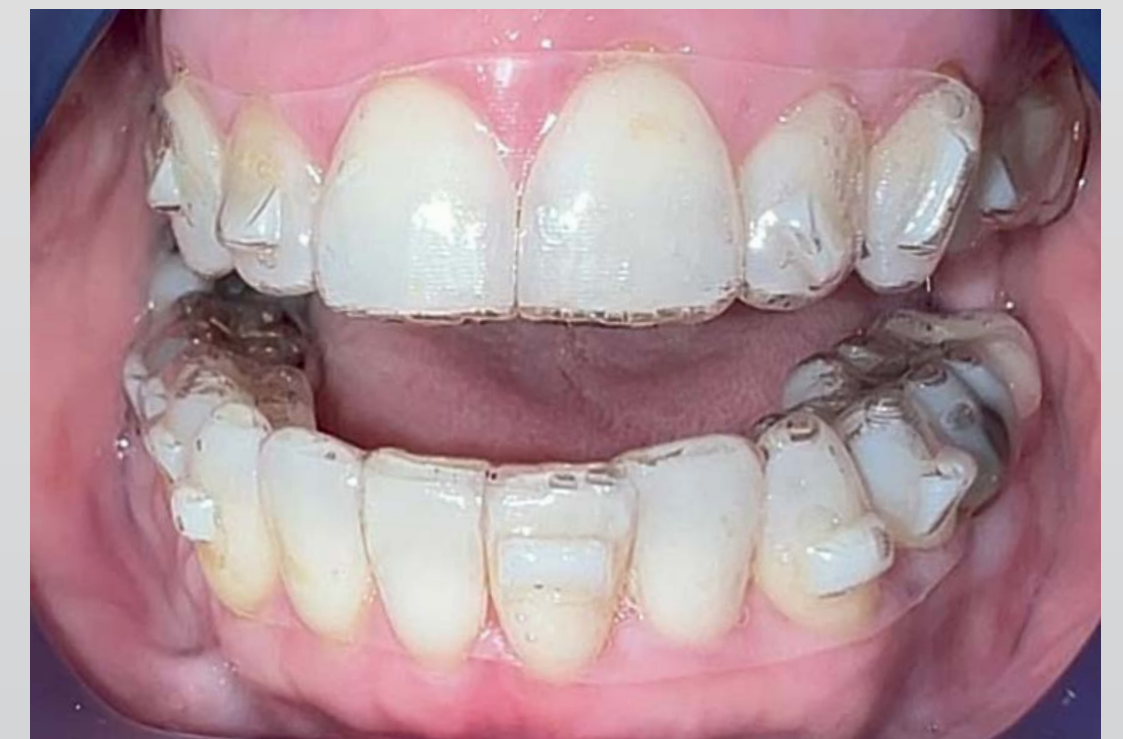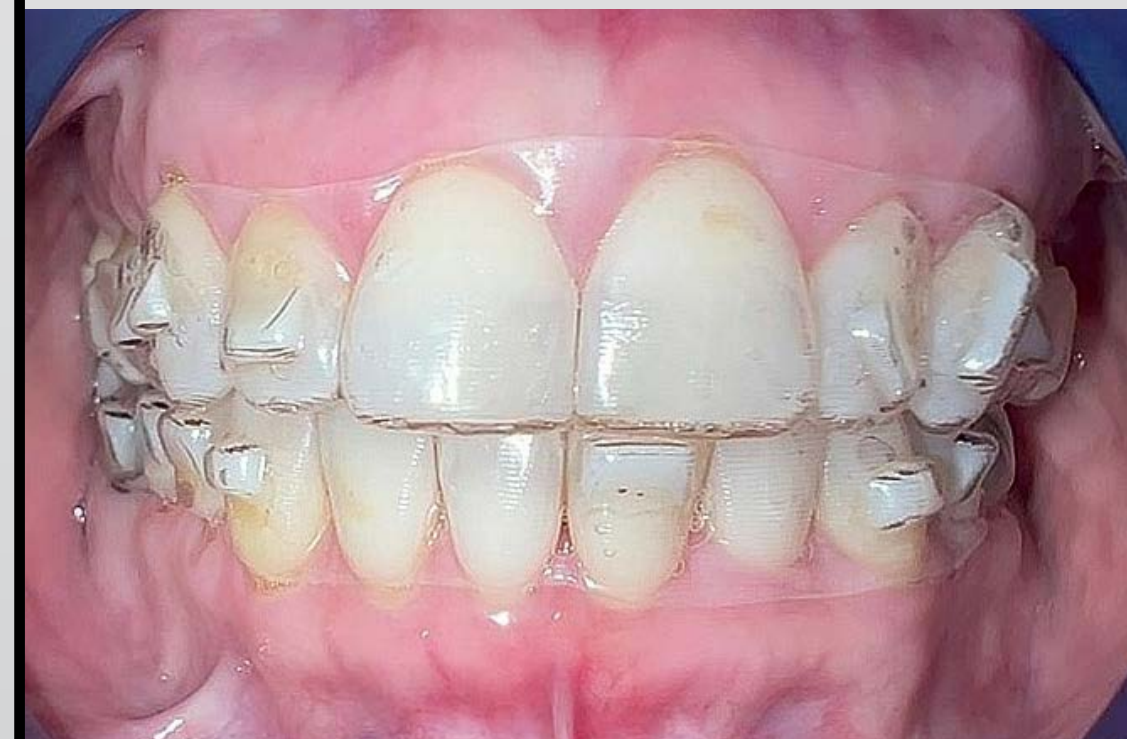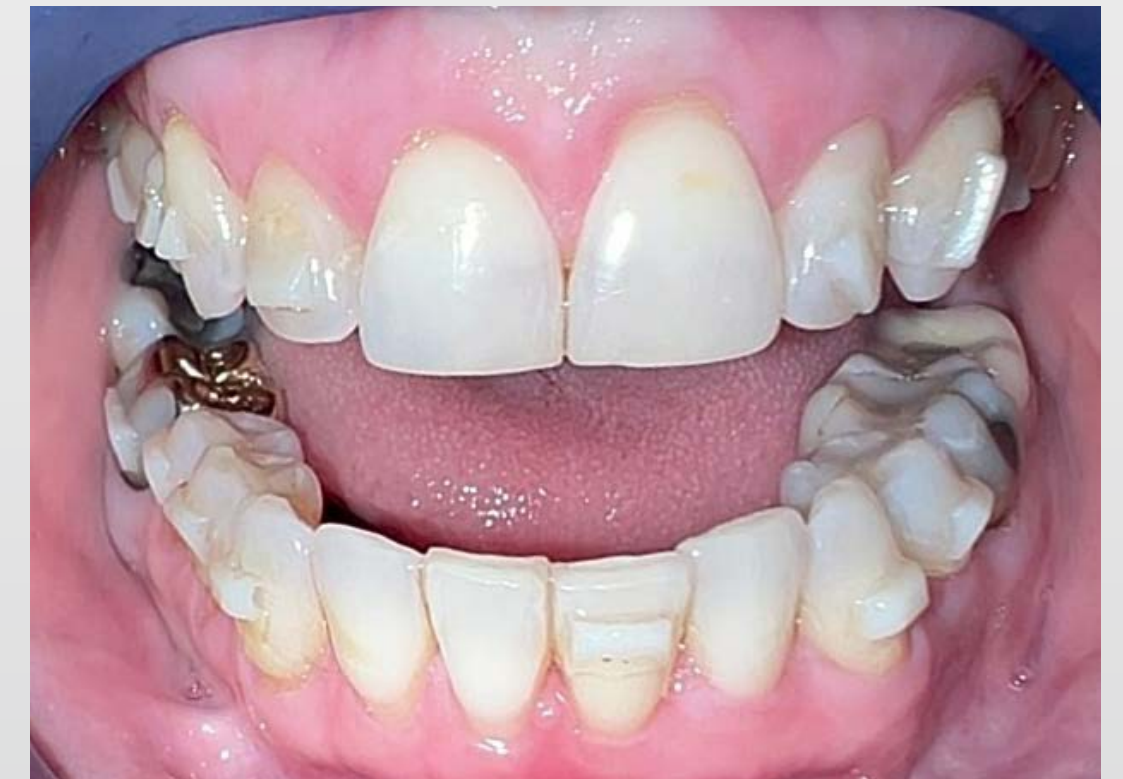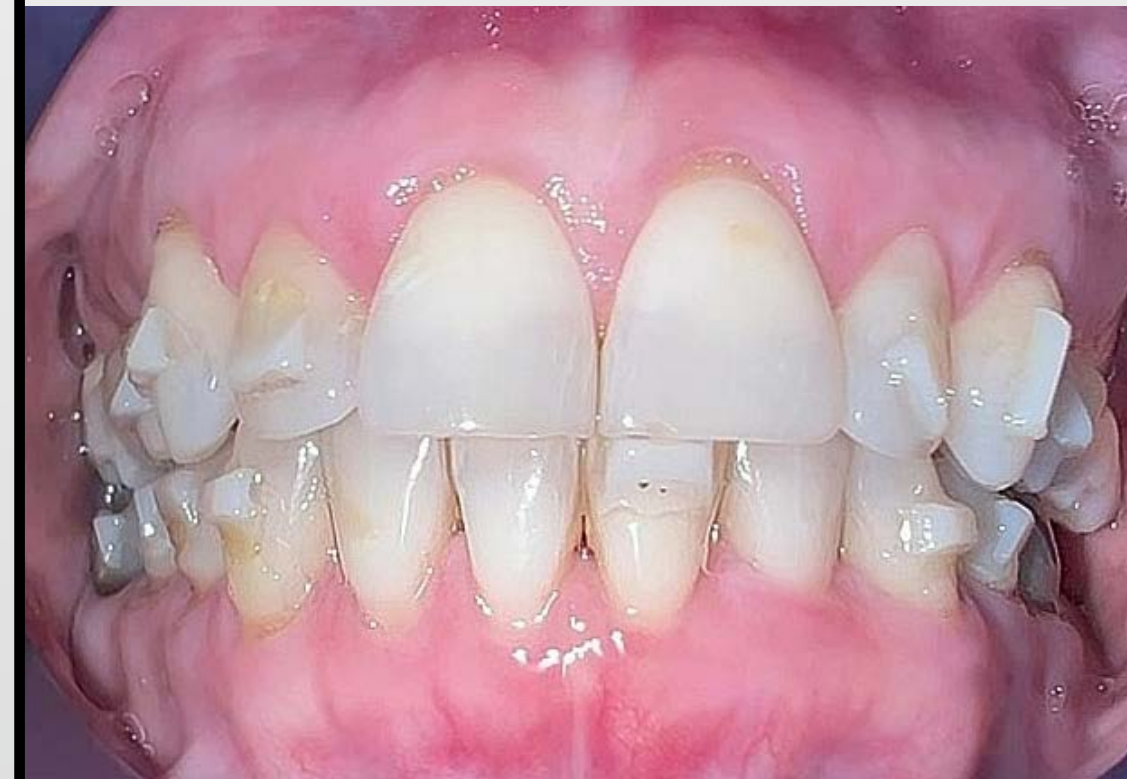Pre-bonding



Bonded attachments

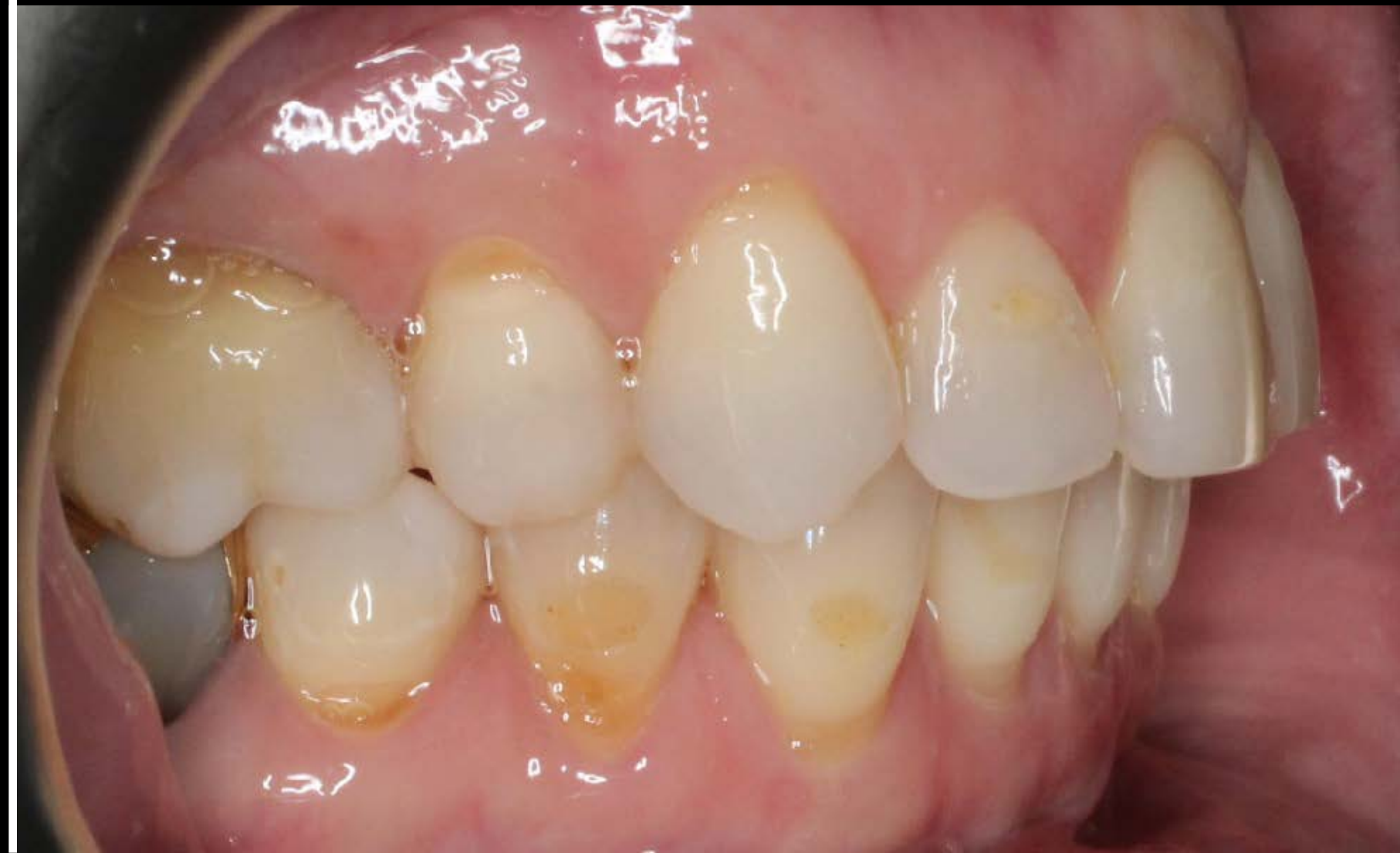

1 month post-bonding / aligner #5

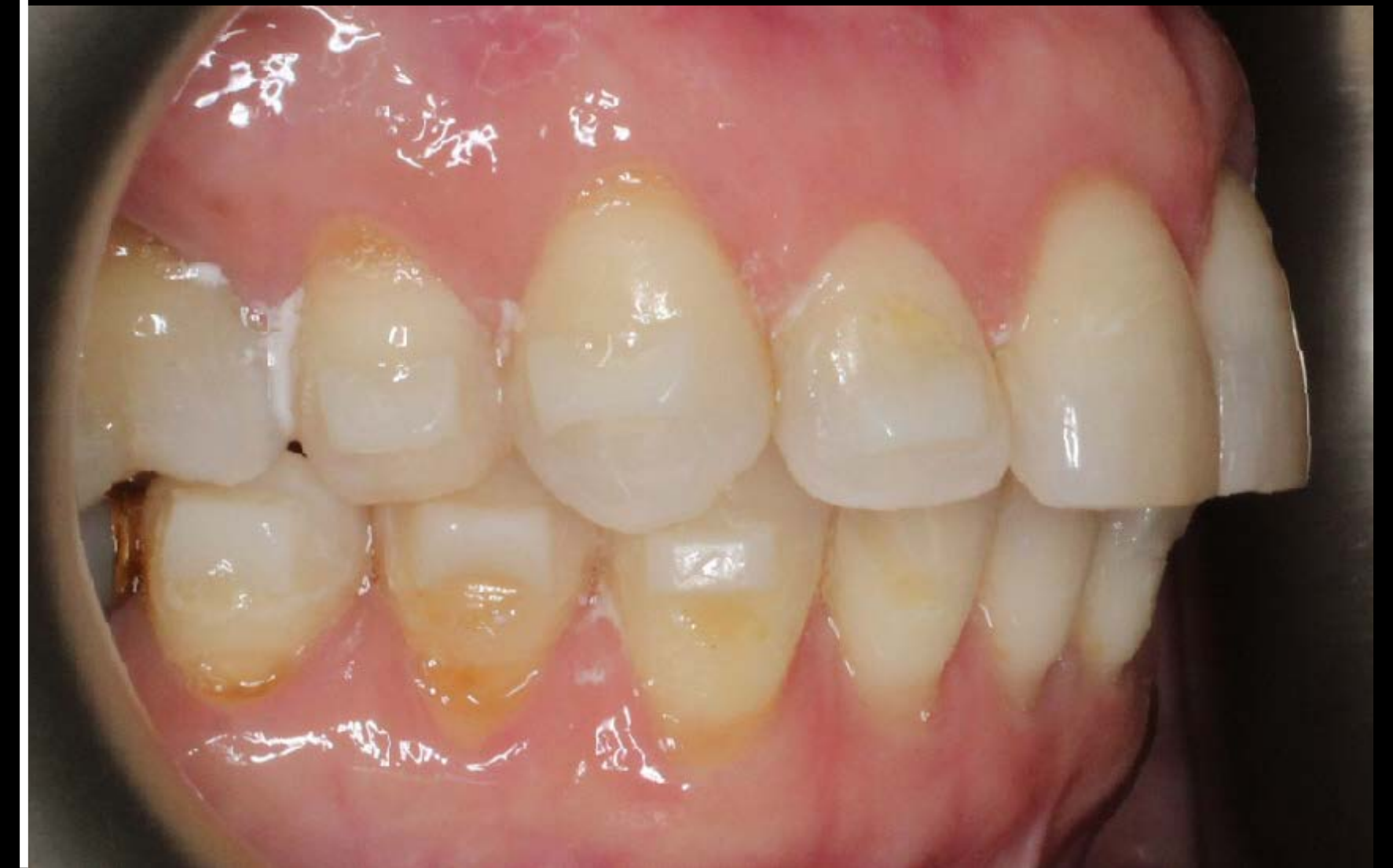

**Retracted
buccal - right**

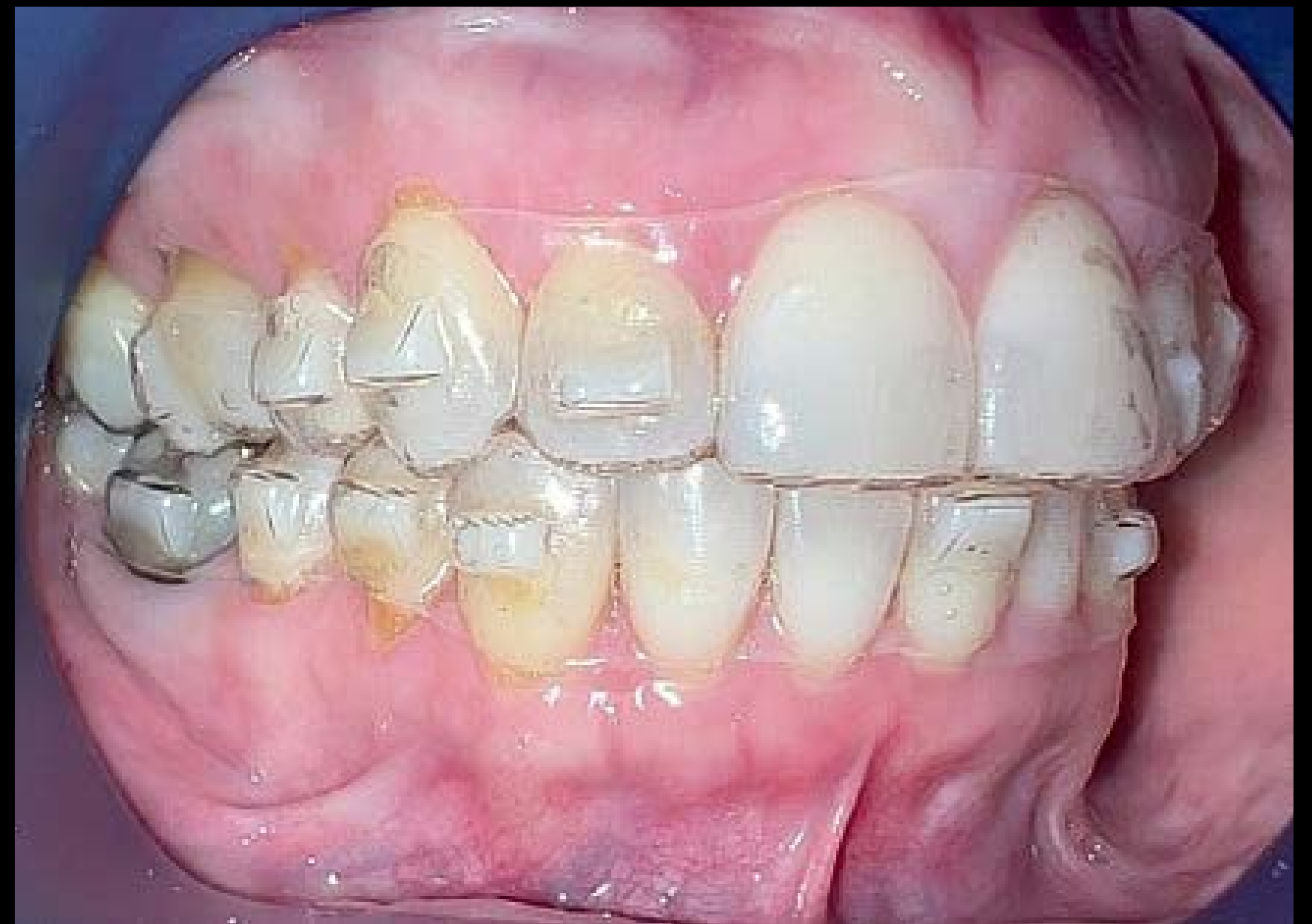
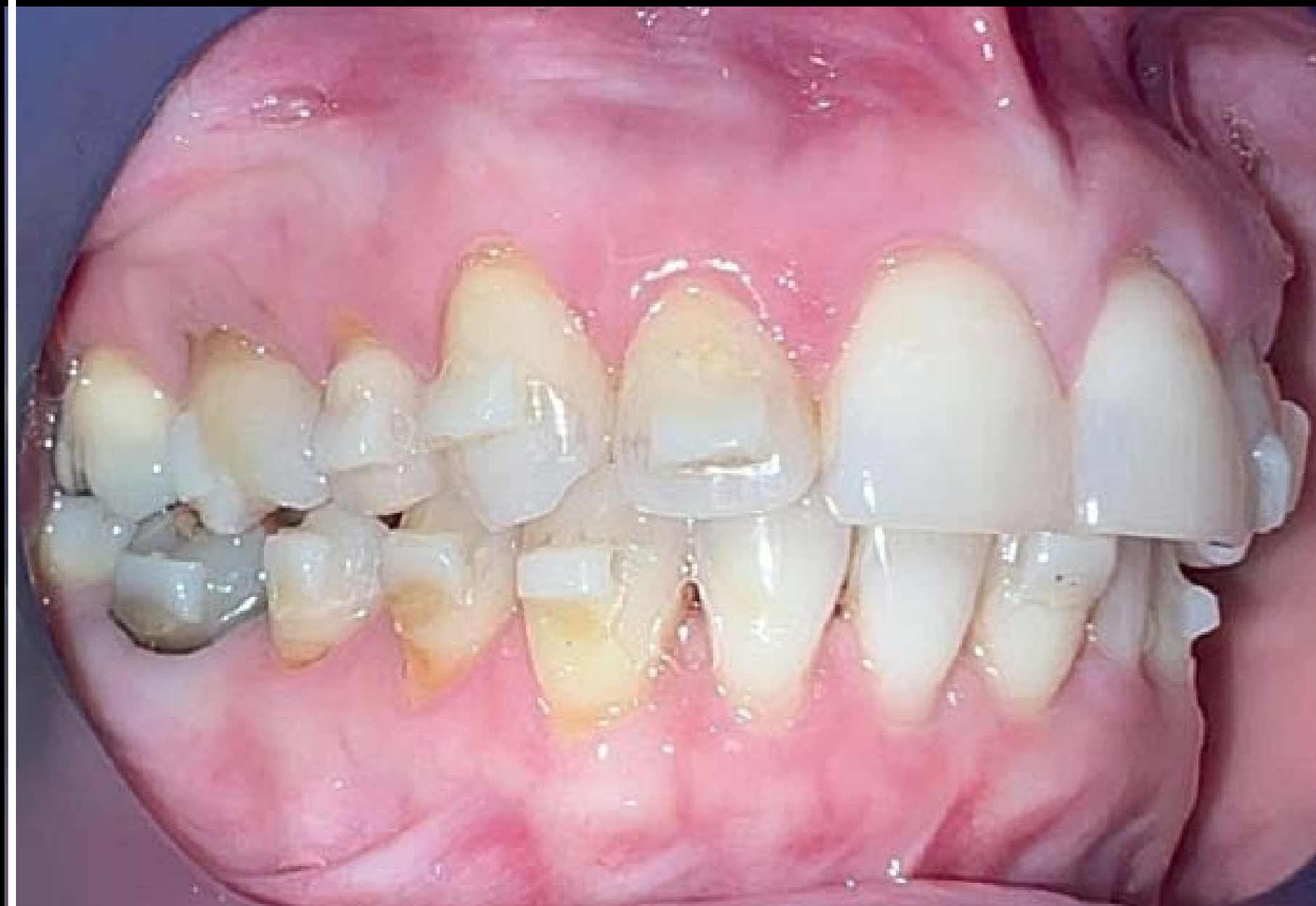Pre-bonding



Bonded attachments

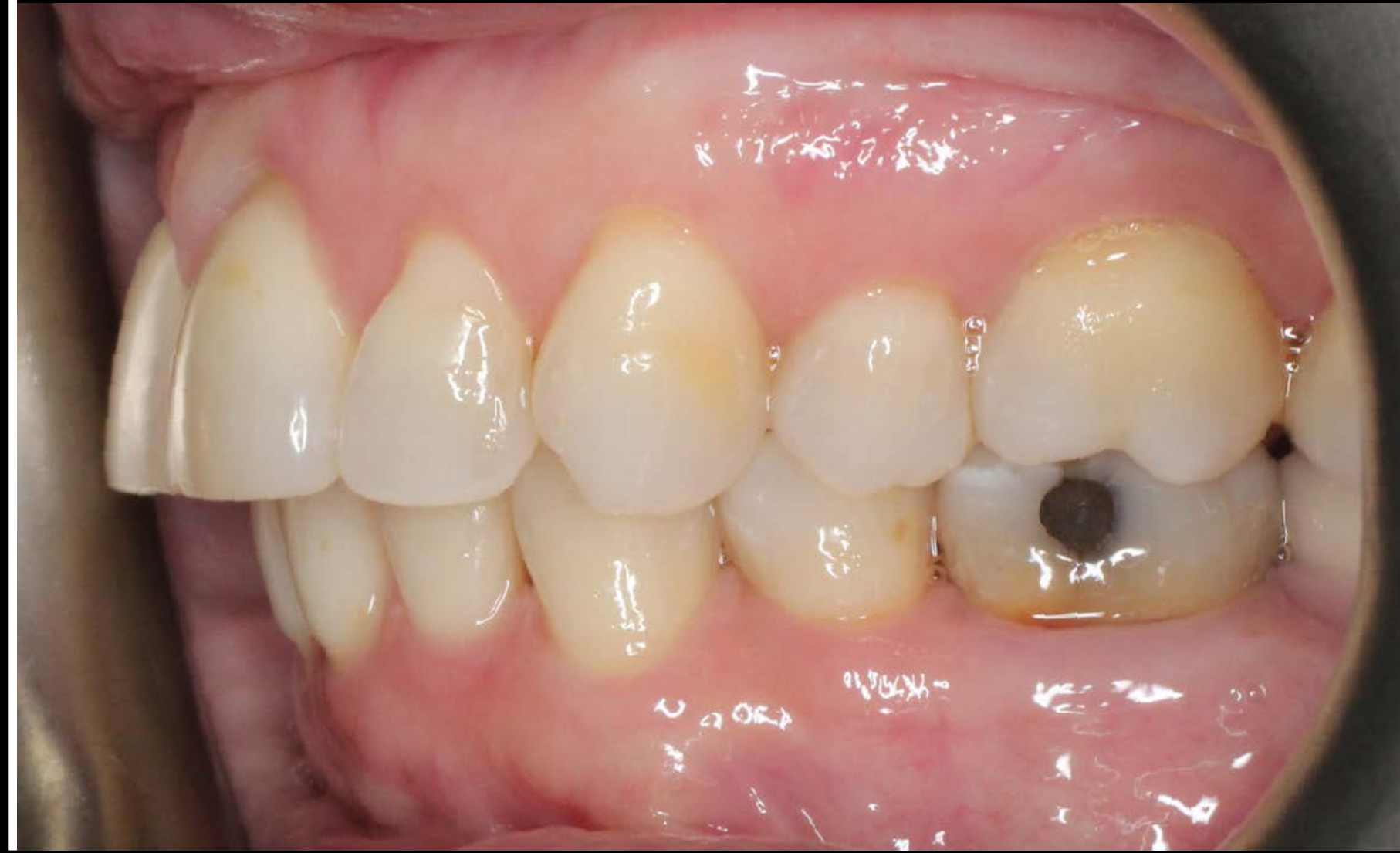

1 month post-bonding / aligner #5

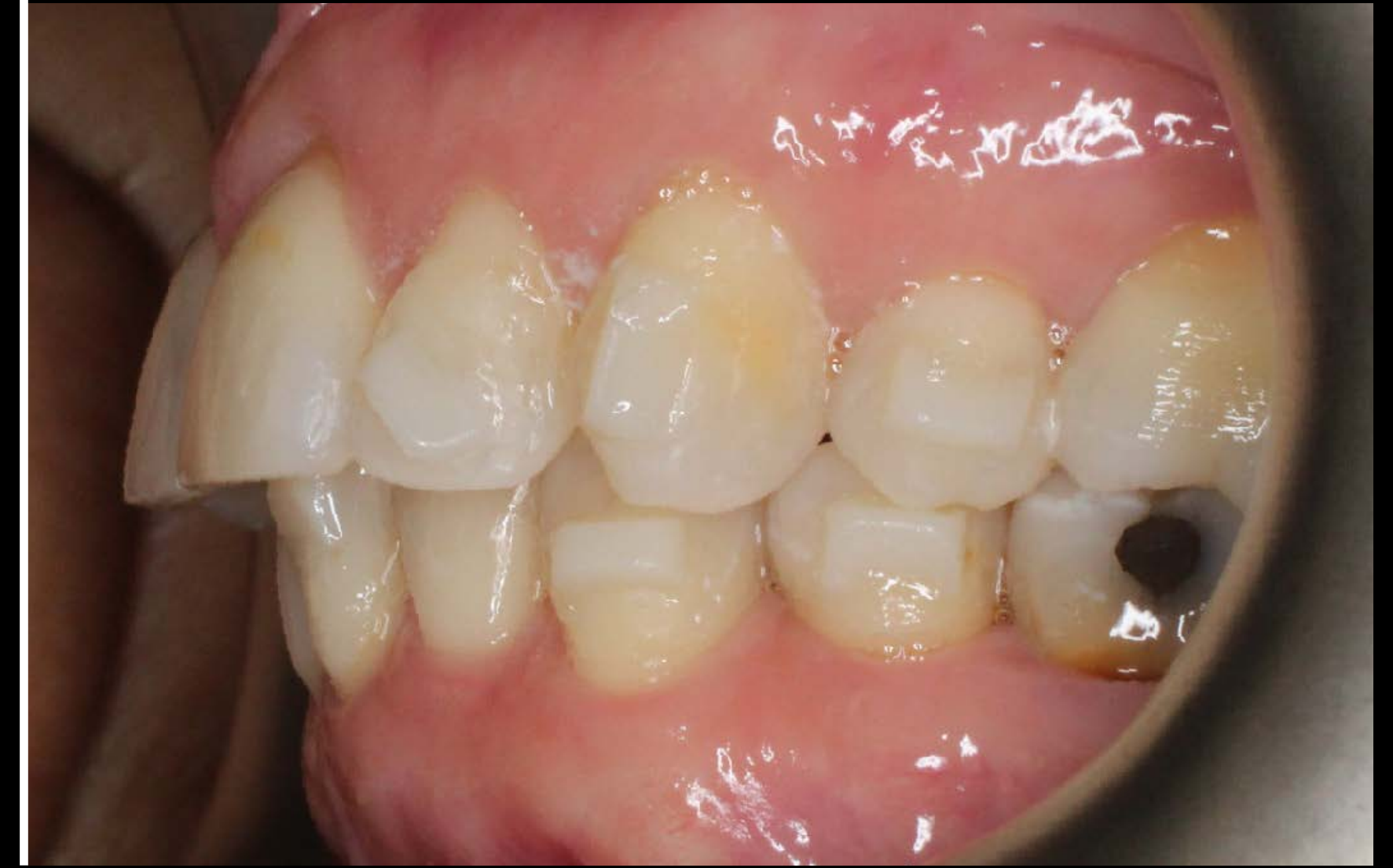

**Retracted
buccal - left**

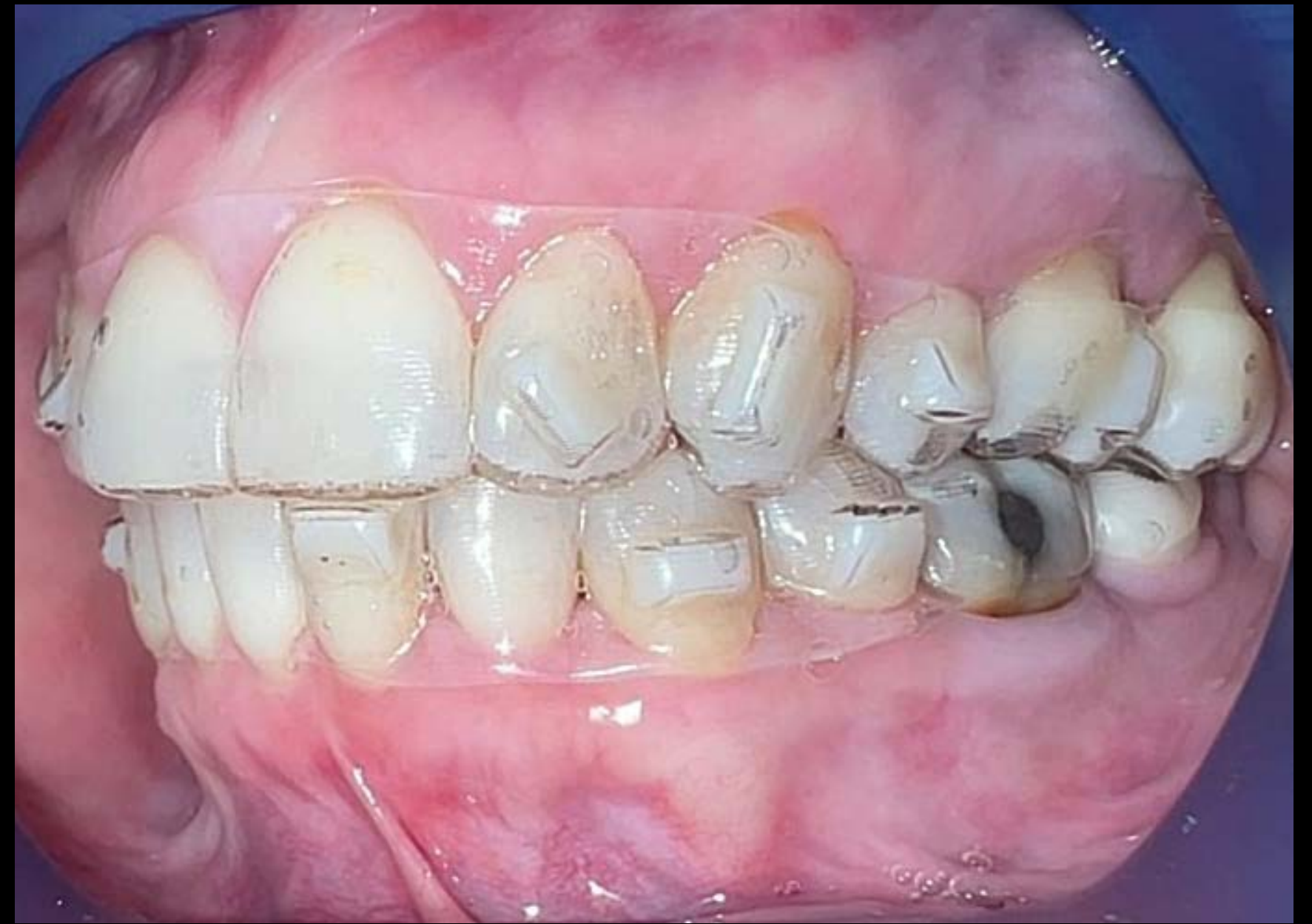
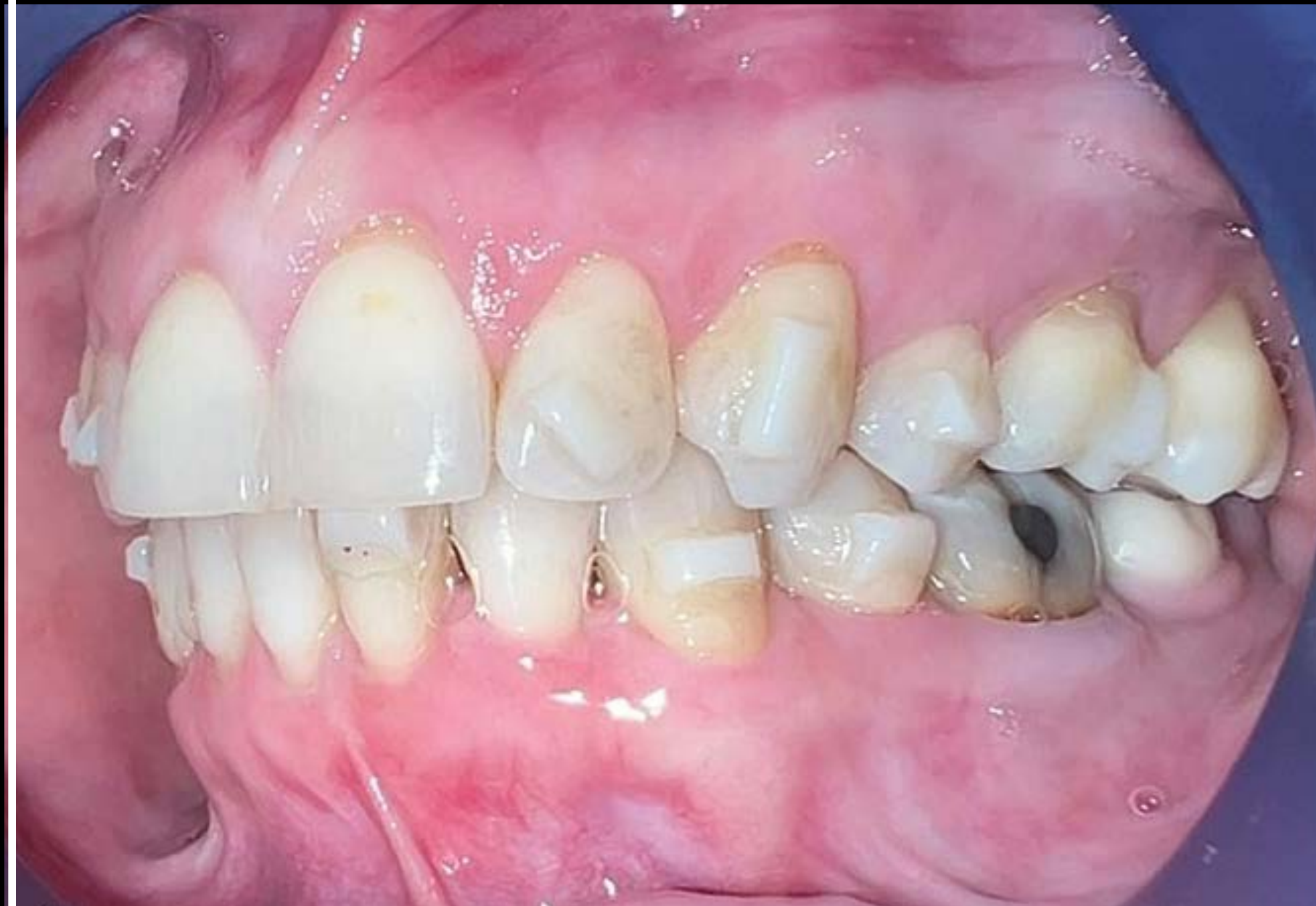Pre-bonding



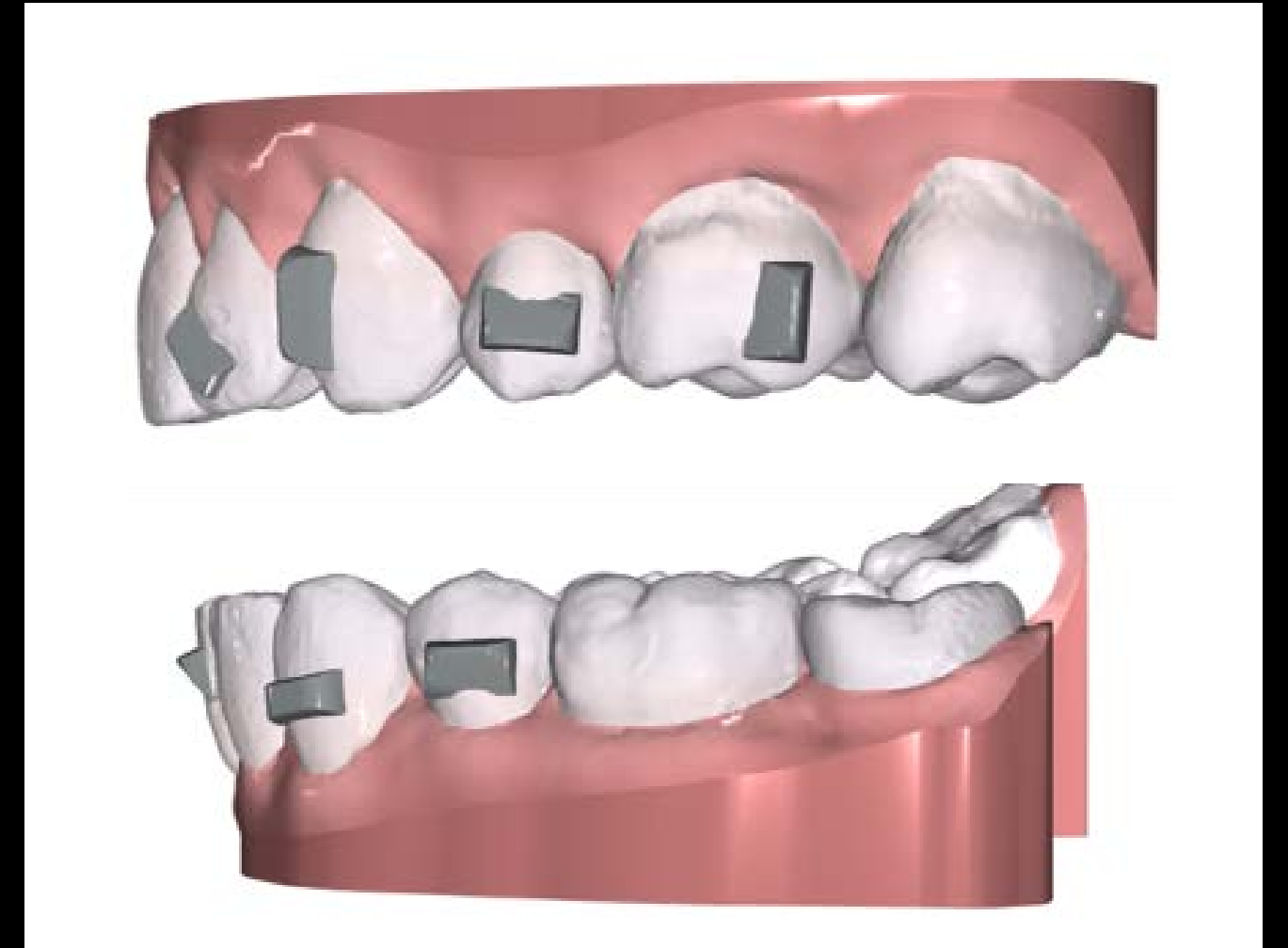
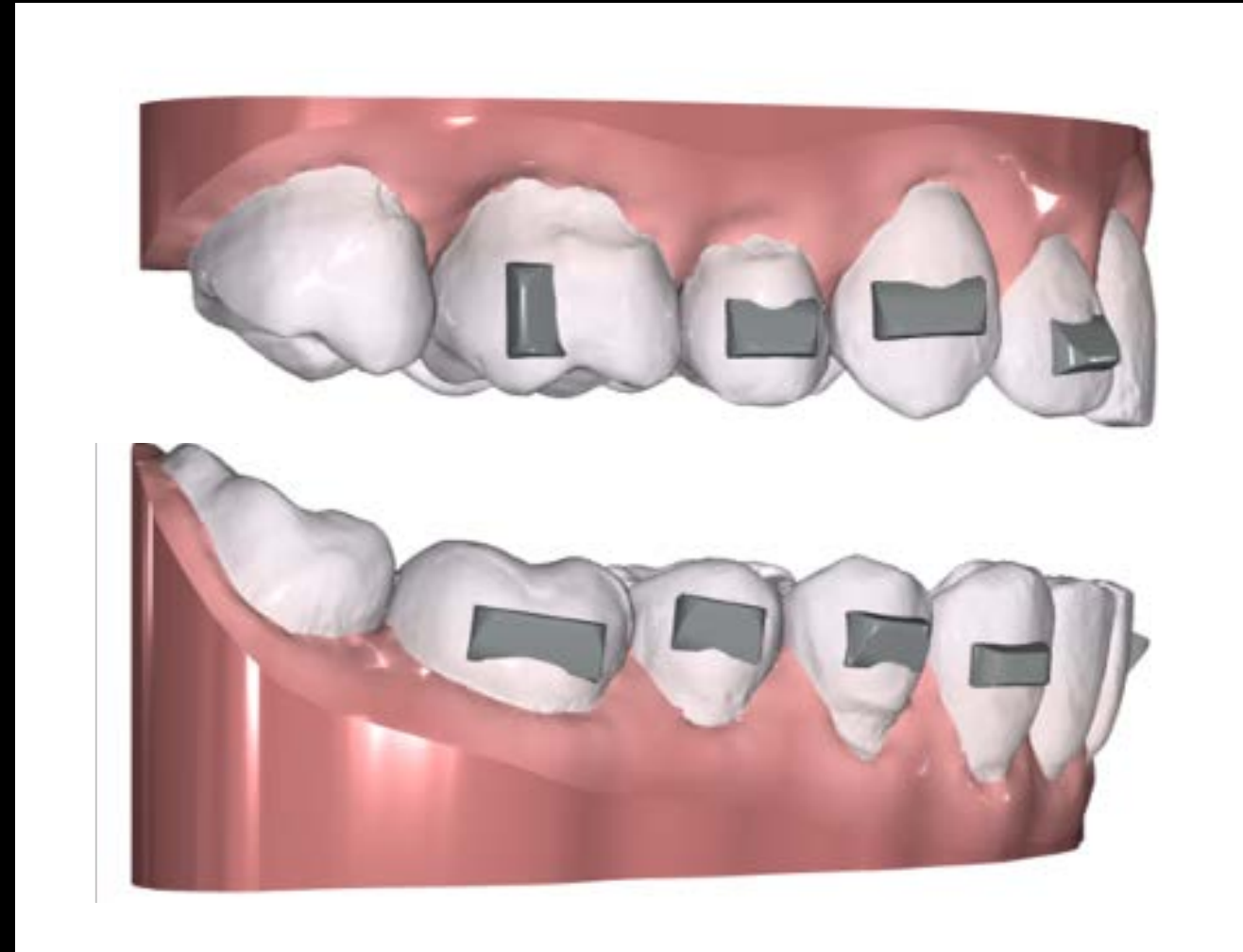
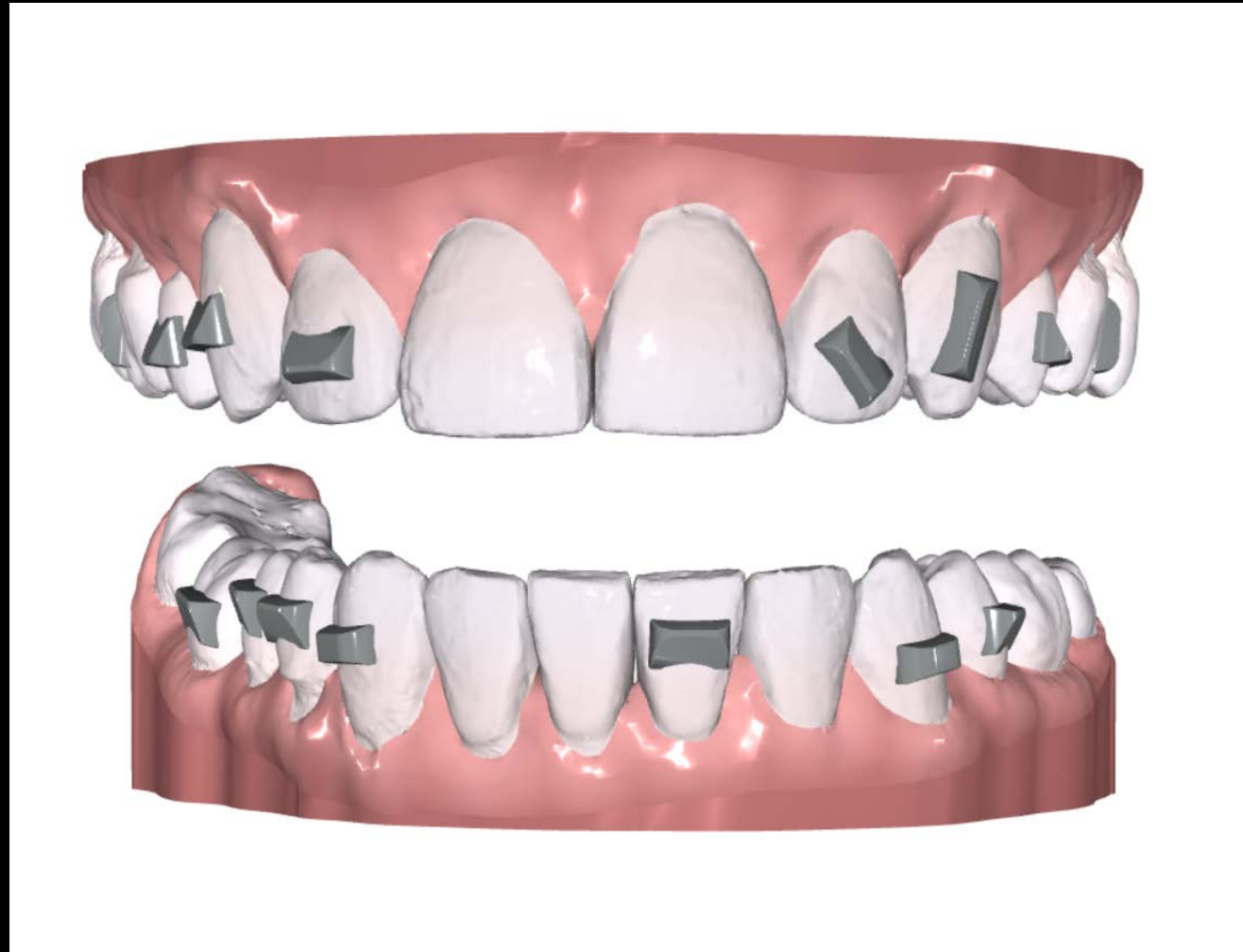Bonded attachments



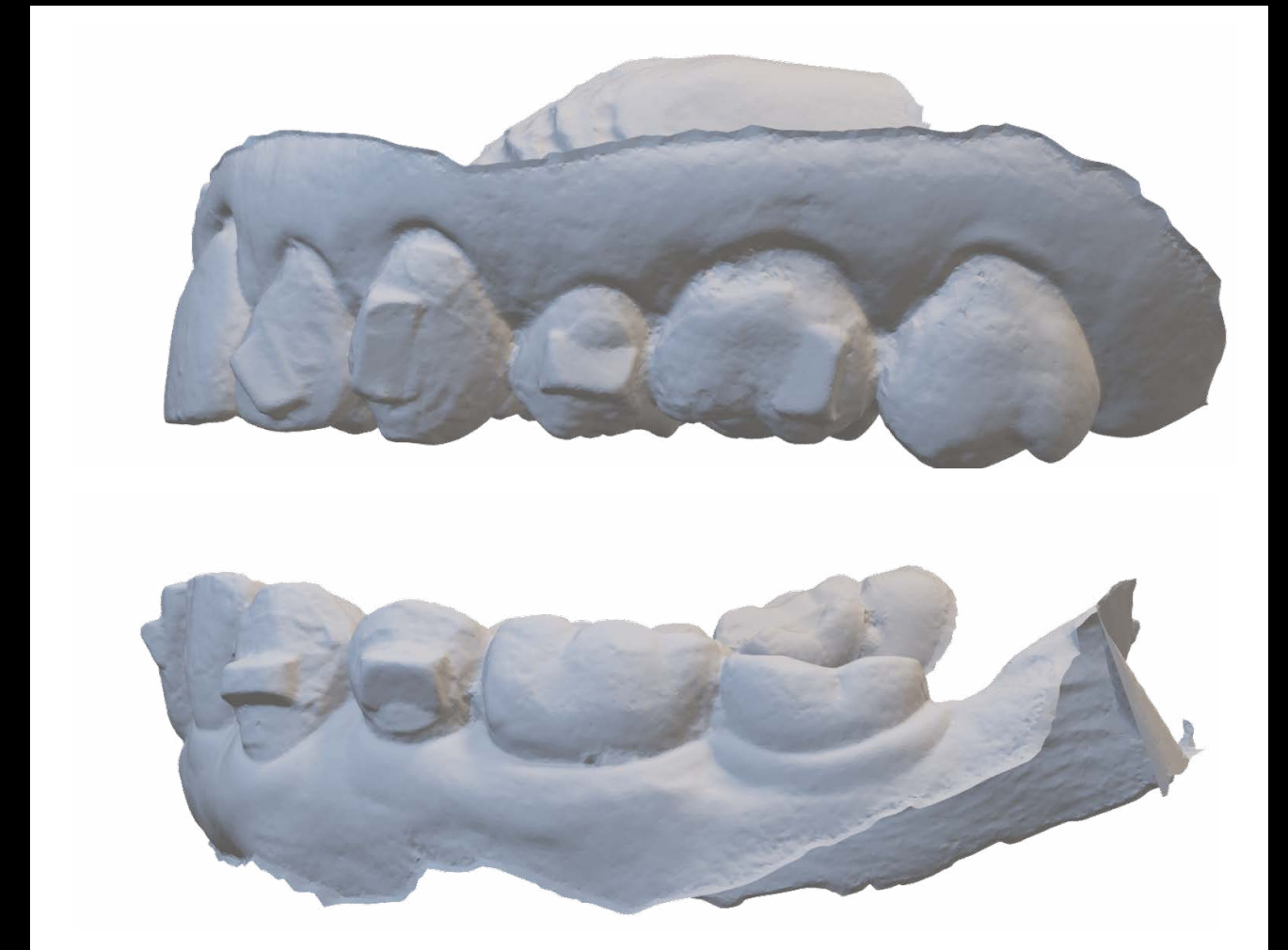
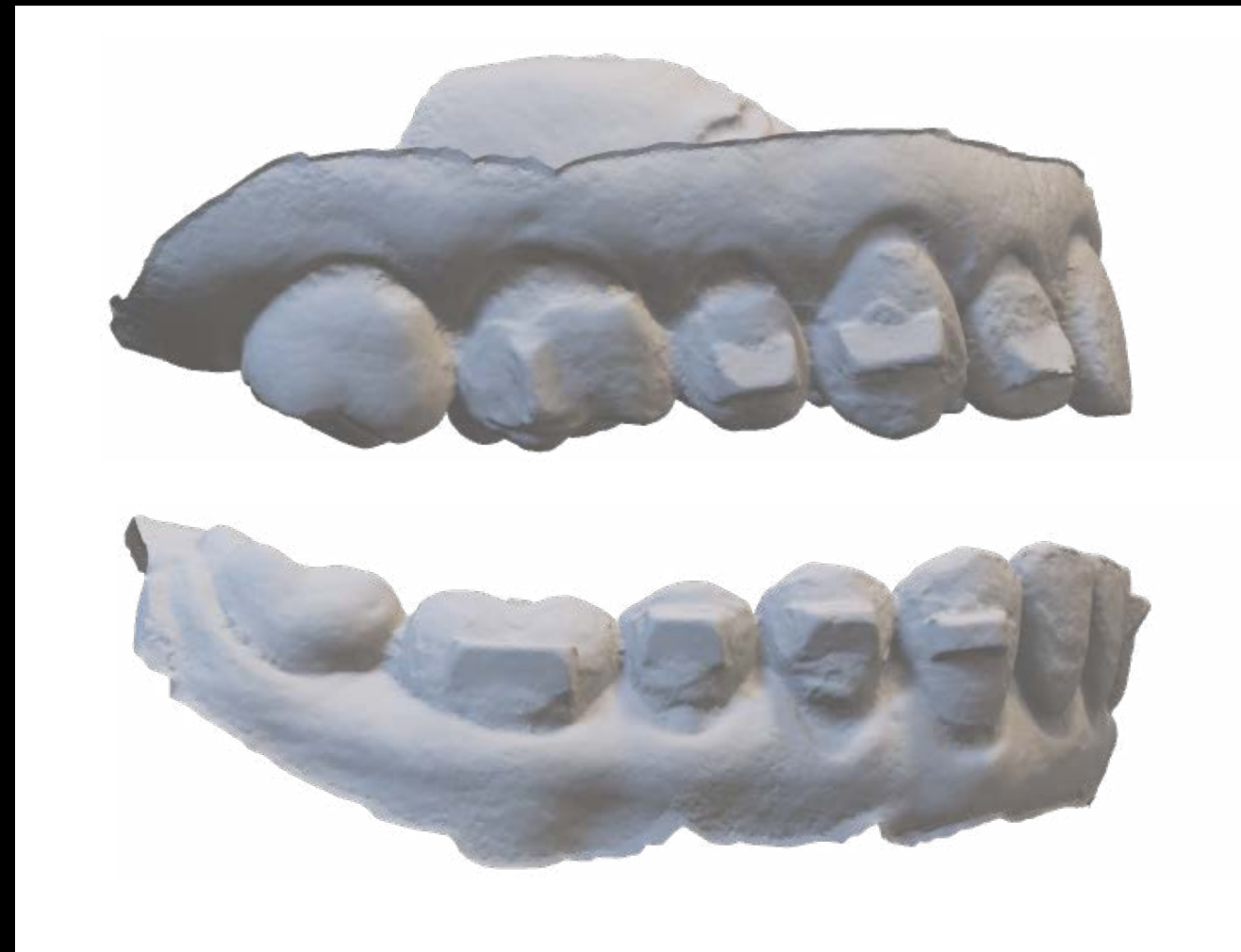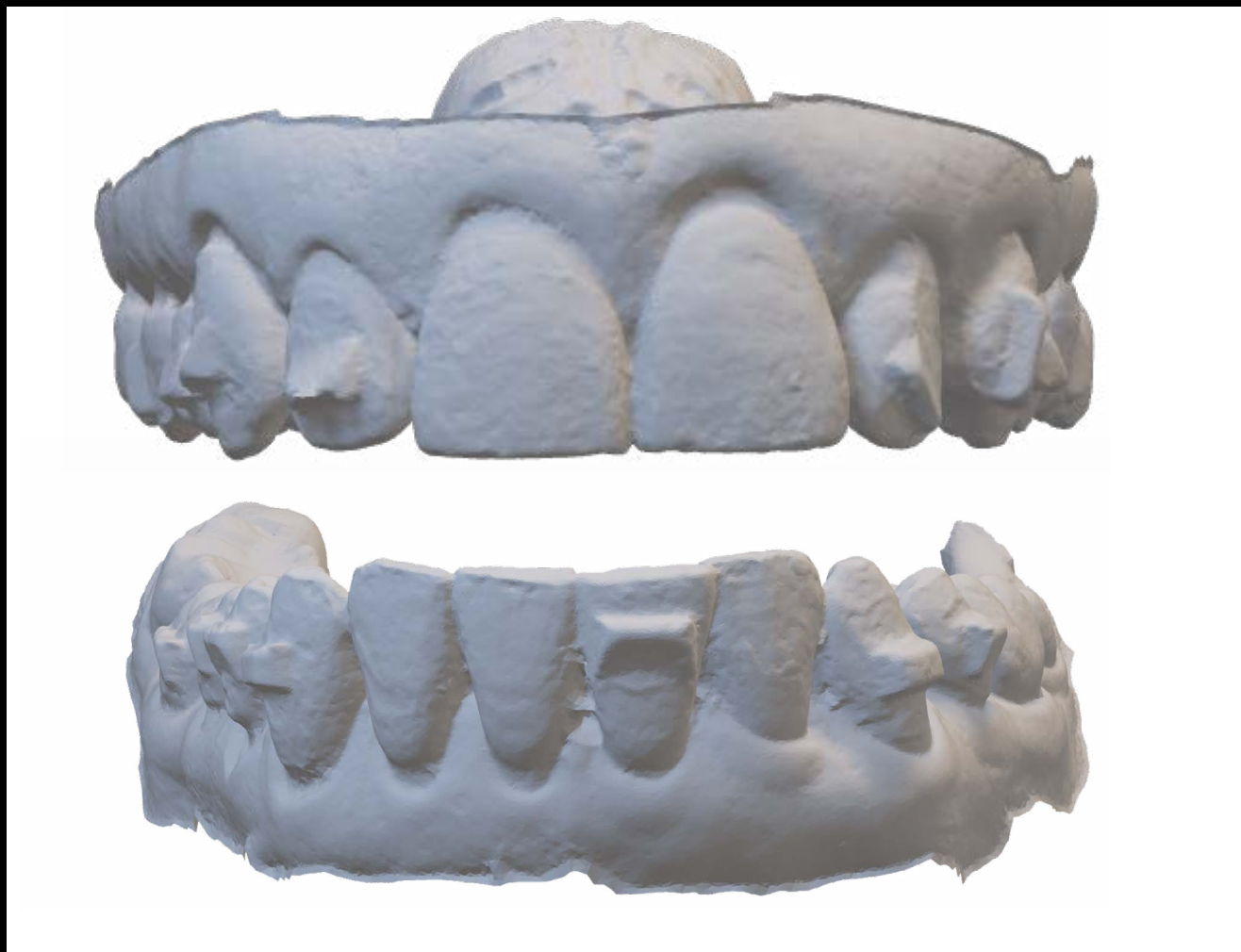1 month post-bonding / aligner #5



Tx Design



Post-bonding
(scan)





Learn more at [**3M.ca/ClarityAligners**](https://3M.ca/ClarityAligners)