

3M Science.
Applied to Life.™



The 3M™ Snap™ Therapy System Case Studies

Disposable Negative Pressure Wound Therapy (dNPWT) for use in challenging anatomies.

Introduction

This booklet includes case studies across several wound types. As with any case study, the results and outcomes should not be interpreted as a guarantee or warranty of similar results. Individual results may vary depending on the patient's condition and circumstances.

Table of Contents

3M™ Snap™ Therapy System Indications.....	4
3M™ Snap™ Therapy System Overview.....	5

Lower Extremity Cases

Post Surgical Wounds

Case Study 1	Foot Abscess	6
Case Study 4	Post-Surgical Foot Wound Following Partial First Ray Resection.....	10
Case Study 5	Wound Resulting From Dorsal Surgical Dehiscence.....	11
Case Study 6	Non-Healing Postsurgical Foot Wound	12
Case Study 7	Dehisced Foot Wound Following Total Metatarsal Amputation	14
Case Study 11	Local Flap Over A Recalcitrant Acute Wound	20
Case Study 12	Dehisced Wound	21

Trauma Wounds

Case Study 10	Trauma Wound to the Lower Extremity	18
---------------	---	----

Chronic Wounds

Case Study 2	Calcaneal Diabetic Foot Ulcer (DFU).....	7
Case Study 3	Plantar Diabetic Foot Ucler (DFU)	8
Case Study 8	Pressure Injury	16
Case Study 9	Venous Stasis Ulcer.....	17

Upper Extremity Cases

Case Study 13	Bolster A Full Thickness Skin Graft.....	22
Case Study 14	Manage a Wound Resulting from a Venomous Insect Bite.....	23
Case Study 15	Dehisced Wound Post Tenosuspension of the Pollex	24
Case Study 16	Wound Of The Upper Extremity	26
Case Study 17	Surgical Defect Open to The Deep Fascia of the Upper Extremity	27

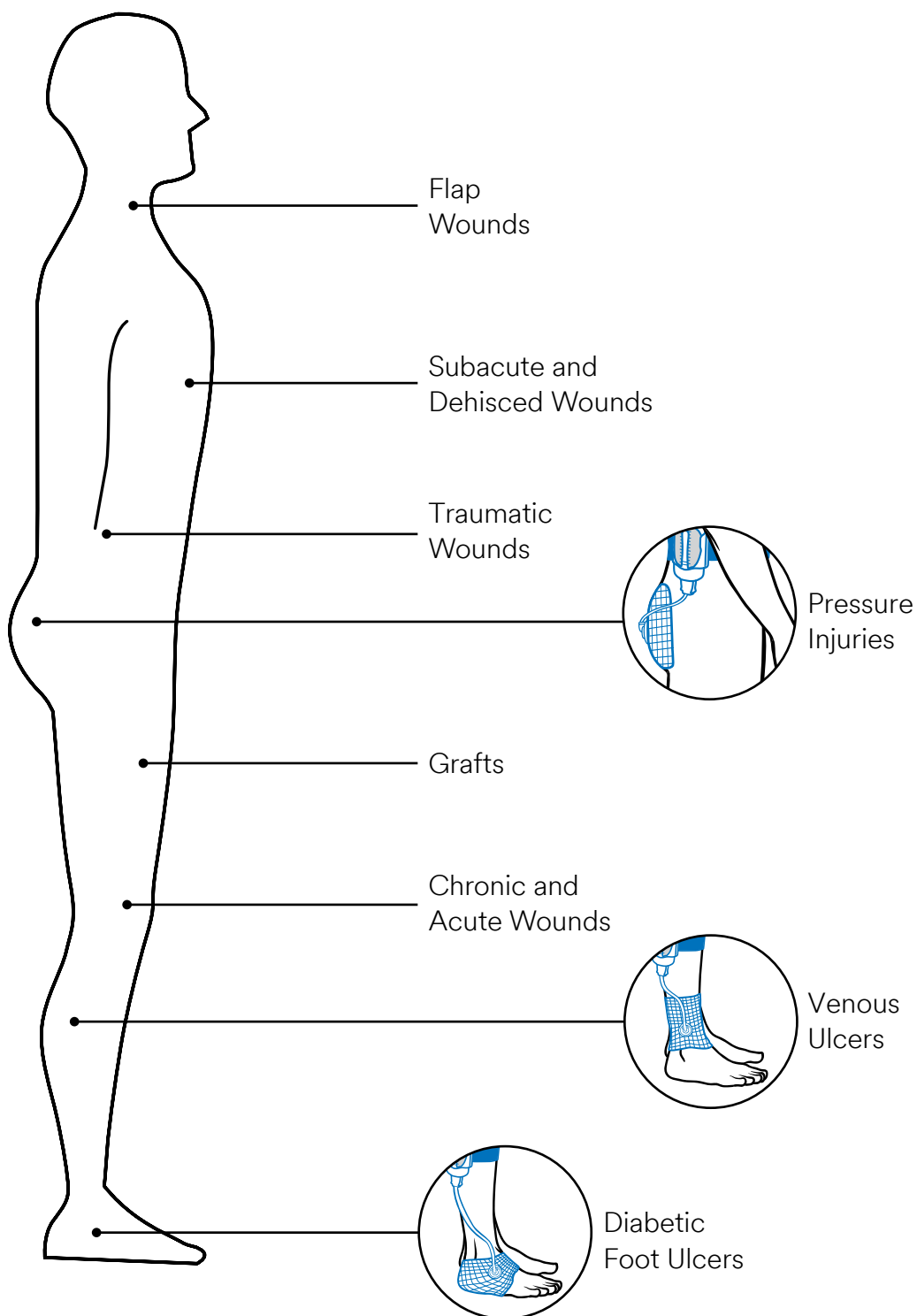
Torso Cases

Case Study 18	Wound Resulting from a Postoperative Surgical Complication	28
Case Study 19	Manage an Acute Wound (Pilonidal Cyst).....	30

3M™ Snap™ Therapy System Indications

The Snap therapy system is indicated for patients who would benefit from wound management via the application of negative pressure, particularly as the device may promote wound healing through the removal of excess exudate, infectious material, and tissue debris.

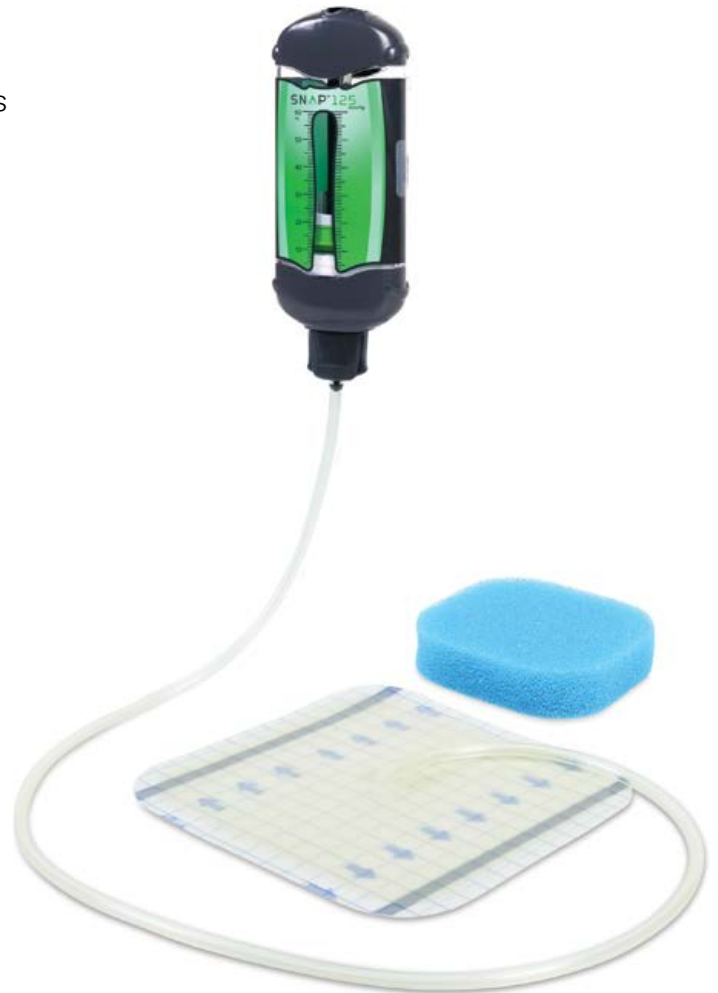The Snap therapy system is indicated for removal of small amounts of exudate from chronic, acute, traumatic, subacute and dehisced wounds, ulcers (such as diabetic, venous or pressure), surgically closed incisions, flaps and grafts.




3M™ Snap™ Therapy System at a glance

The Snap therapy system combines the simplicity of advanced wound dressings with the proven benefits of negative pressure therapy in a discreet design.¹

- Mechanically powered and portable for patient mobility
- No settings or adjustments for patient to learn
- Preserved patient quality of life (QOL)¹
- Discreet and worn under clothing
- Silent design ensures minimal sleep interruptions
- Continuous -125mmHg therapy
- Single-use, disposable NPWT
- Off-the-shelf availability



3M™ Snap™ Therapy System Strap and
3M™ Snap™ Plus Therapy Strap



3M™ Snap™ Advanced Dressing Kit
and 3M™ Snap™ Bridge Dressing Kit



3M™ Snap™ SecurRing™
Hydrocolloid Skin Barrier

Case Study 1

Use of the 3M™ Snap™ Therapy System to manage a foot abscess.

Patient:

A 50-year-old male presented to the emergency department with an abscess over the first interspace of the left foot. The patient's previous medical history included Type 2 diabetes.

Diagnosis:

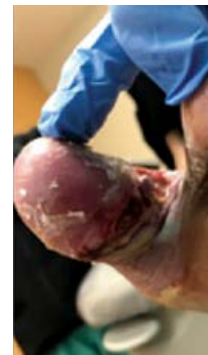The patient was taken to the operating room, and had a surgical defect following incision and drainage of an interspace foot abscess (Figure A). The wound was initially managed with daily wet-to-moist dressing changes until follow-up in the clinic. After 1 week, the surgical defect underwent debridement. A disposable negative pressure wound therapy modality was then enlisted to facilitate wound closure.

Course of Treatment/Application of the Snap Therapy System:

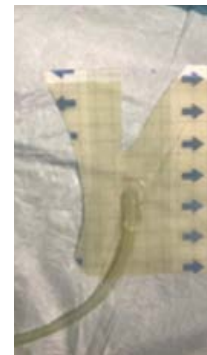Per institutional guidelines, the wound bed was prepared, the periwound area was cleansed, and skin prep was utilized prior to the application of the Snap therapy system. The irregular topography of the surgical defect presented a challenge in dressing the interspace and in attaining a steadfast seal during the application of subatmospheric pressure. The Snap therapy system foam interface was placed into the surgical defect, which coursed the plantar hallux and the interspace to the dorsal first metatarsal. The 3M™ Snap™ SecurRing™ Hydrocolloid Skin Barrier was rolled thin and placed around the wound margin. The 3M™ Snap™ Advanced Dressing was custom cut to include a "V" shape (Figure B) to better contour the irregular area between the toes. An additional set of hands was enlisted for the placement of the drape, with special attention given to stretching and adhering the individually-cut the Snap Advanced dressing from the intact periwound to stop wrinkles in the drape. The Snap therapy system was applied to the first interspace (Figure C), and dressings were changed twice weekly. Figure D shows the wound after 4 weeks of the Snap therapy system and weekly debridement. The Snap therapy system was discontinued after 9 weeks, as the wound was reduced in size and exhibited healthy tissue granulation (Figure E and F).

Discharge and Follow-up:

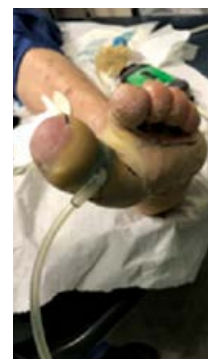During follow-up 2 weeks after the Snap therapy system was discontinued, the wound was almost completely healed (Figure G).



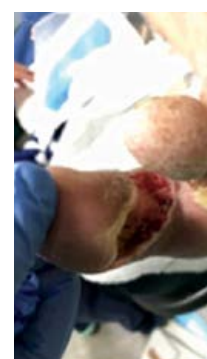A. First interspace after abscess incision and drainage.



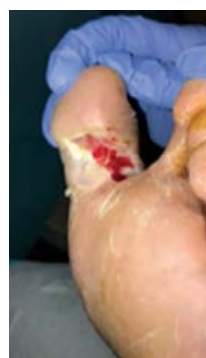B. The Snap Advanced Dressing cut to contour the first interspace.



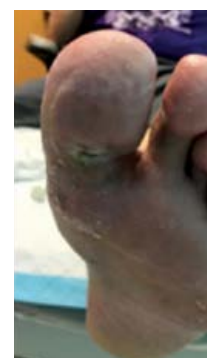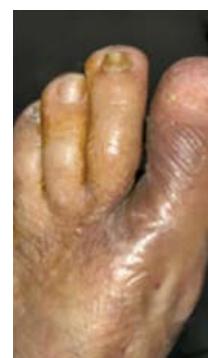C. The Snap therapy system applied to the first interspace.



D. Wound after 4 weeks of the Snap therapy system and weekly debridement.



E/F. Wound after 2 months of the Snap therapy system.



G. At 11-week follow-up, the wound was almost completely healed.

Case Study 2

Use of the 3M™ Snap™ Therapy System to manage a Calcaneal Diabetic Foot Ulcer (DFU).

Patient:

A 64-year-old male was referred to the wound clinic by an orthopedist for a calcaneal abscess (Figure A), which resulted from stepping on a foreign body. The patient's medical history included Type 2 diabetes mellitus and peripheral neuropathy.

Diagnosis:

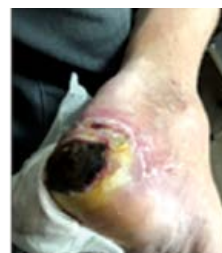The patient had a calcaneal abscess that had been worsening for 3 months, which necessitated excisional debridement of the necrotic tissue and preparation of a healthy wound bed to facilitate closure via grafting.

Course of Treatment/Application of the Snap Therapy System:

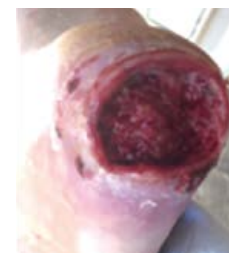Empiric antibiotics were initiated, and an MRI was ordered to image the lower extremity. Aggressive sharp excisional debridement was performed on the first day of presentation (Figure B). The 3M™ Snap™ Plus Therapy System (-125mmHg; 150ml canister) was applied immediately over the debrided wound after complete removal of necrotic tissue and thorough irrigation. On treatment Day 5, the images from the MRI were suggestive of osteomyelitis (Figure C). A swab culture of the abscess revealed *Staphylococcus aureus*, and the patient continued the prescribed oral antibiotic regimen. Offloading with a knee scooter was recommended, and wound management continued with the Snap therapy system with a smaller canister (60ml) due to an observed decrease in the amount of drainage from the ulcer. After 4 weeks, the ulcer continued to show reduction in size (Figure D). At 8 weeks, the wound was considerably smaller with healthy wound edges (Figure E), and the Snap therapy system was discontinued.

Discharge and Follow-up:

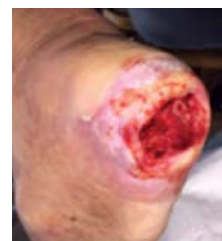The wound bed was sufficiently granulated, and a dehydrated human amnion/chorion membrane allograft (dHACM) was applied. Figure F shows the ulcer 3 days post first dHACM allograft application. The patient continued to receive oral antibiotics and to offload. There were three subsequent applications of dHACM allografts, and at 10 weeks, treatment was switched to a non-adherent silicone dressing with an absorbent foam cover. At 13 weeks, the ulcer had resolved (Figure G).



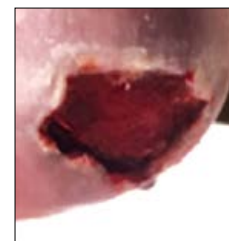
A. DFU on calcaneus at presentation.



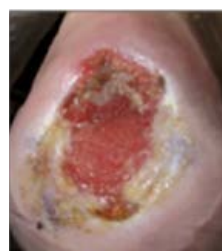B. Calcaneal ulcer after aggressive sharp excisional debridement.



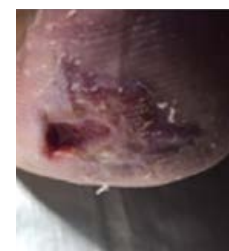
C. Wound at postoperative Day 5 after MRI diagnosis of osteomyelitis and initial treatment with the Snap therapy system.



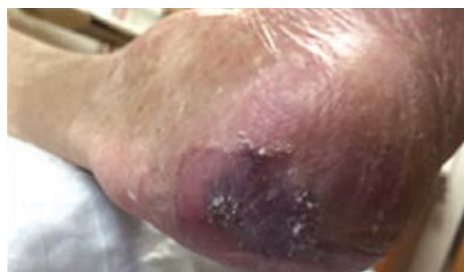D. At 4 weeks, wound dimensions were reduced, and the Snap therapy system was continued.



E. At 8 weeks, wound bed was prepared to receive dHACM allograft, and treatment with the Snap therapy system was discontinued.



F. 3 days post first dHACM allograft application.



G. At 13 weeks, the ulcer was completely resolved.

Case Study 3

Use of the 3M™ Snap™ Therapy System to manage a Plantar Diabetic Foot Ulcer (DFU).

Patient:

A 55-year-old male presented to the clinic with a diabetic foot ulcer (DFU). The patient's medical history included diabetes, peripheral neuropathy and Charcot arthropathy.

Diagnosis:

The patient had a chronic plantar midfoot ulcer concomitant with his diabetes, Charcot deformity, and loss of protective sensation. A disposable negative pressure wound therapy modality was enlisted to manage the wound, and a total contact cast (TCC) system was employed for off-loading the DFU.

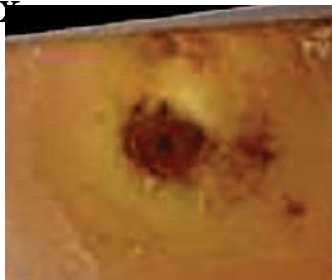
Course of Treatment/Application of the Snap Therapy System:

At initial presentation, the DFU was evaluated (Figure A). TCC was recommended to facilitate healing of the DFU, which would distribute the patient's weight more evenly along the plantar aspect, and reduce shearing forces. However, the patient was initially reluctant, and he declined the recommendation to receive a TCC to off-load. At a follow-up appointment 42 days from initial presentation, the DFU was reevaluated. (Figure B). As healthy cellular growth within the wound bed was preempted by a resistance to off-load, the patient reconsidered the recommendation to receive a TCC. Following the initial TCC application, TCC was used five more times for off-loading. After the sixth TCC removal, the DFU was again reassessed. Although the DFU demonstrated significant progress in size reduction and appearance of the wound bed (Figure C), there had been no change from the fifth and sixth castings. X-ray imaging of the impacted foot following the sixth TCC treatment (Figure D) gauged whether a bony exostosis was responsible for creating a focal point of high pressure that was restricting complete wound closure. Peripheral arterial studies as determined by the ankle-brachial index (ABI) test and pulse volume recordings (PVR) revealed that there was no significant arterial occlusive disease in the bilateral lower extremities that would delay healing. Nevertheless, given the stalled wound progression, it was inferred that the wound was likely occupied by bacterial biofilm and inflammatory proteases, which would require a plurality of modalities to disrupt the colonization and to nullify the constitutive activity. DFU management transitioned to a multimodal approach that entailed wound debridement (Figure E), the application of collagen and the coupling of a TCC with the Snap therapy system. An extra portion of hydrocolloid from the 3M™ Snap™ Bridge Dressing was cut to size and placed as a protective layer around the periwound of the DFU. The 3M™ Snap™ SecurRing™ Hydrocolloid Skin Barrier was flattened and placed around the wound margin to assist in maintaining a seal (Figure F). The Snap therapy system foam interface was applied over the wound, and the Snap Bridge dressing was applied over the foam interface to establish a seal (Figure G). The Snap therapy system was applied under the TCC (Figures H and I). The 3M™ Snap™ Therapy Cartridge administered -125mmHg of continuous subatmospheric pressure.

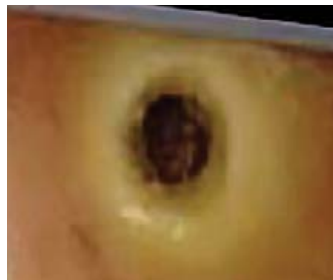Discharge and Follow-up:

In 18 days, 4 applications of a TCC for off-loading and 3 applications of the Snap therapy system resulted in complete resolution of the chronic plantar midfoot ulcer (Figure J).

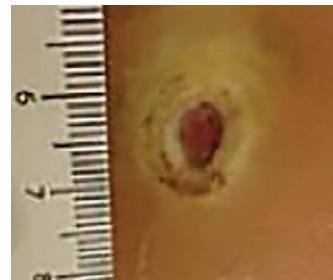
Use of the 3M™ Snap™ Therapy System to manage a Plantar Diabetic Foot Ulcer (DFU). (cont.)



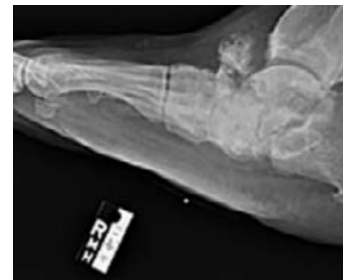A. DFU at initial presentation.



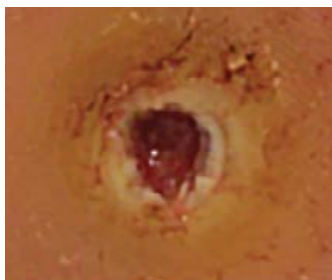B. DFU prior to first application of a TCC.



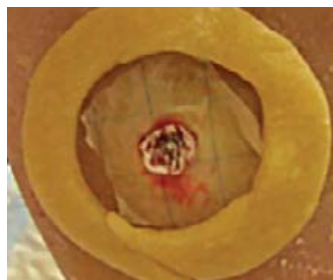C. DFU after sixth application of a TCC.



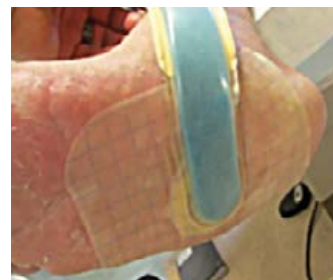D. Radiograph of right foot 71 days after initial presentation.



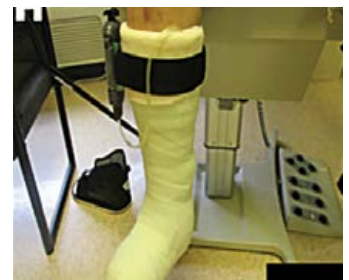E. DFU following debridement.



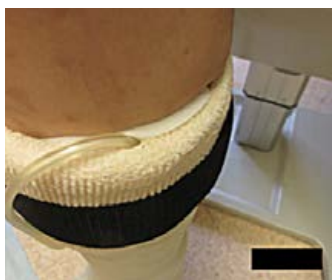F. DFU with the placement of the 3M™ Snap™ SecurRing™ Hydrocolloid Skin Barrier around the wound margin.



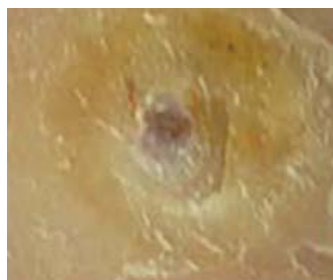G. Placement of the 3M™ Snap™ Bridge Dressing over the wound.



H. The Snap therapy system applied under the TCC.



I. The Snap therapy system applied under the TCC.



J. Complete resolution of the chronic plantar midfoot ulcer.

Case Study 4

Use of the 3M™ Snap™ Therapy System to manage a post-surgical foot wound following partial first ray resection.

Patient:

A 54-year-old male presented to the clinic with an ulcer on the dorsum of the hallux with concomitant osteomyelitis to the osseous tissue of the first phalanx and the first metatarsal head. The patient's medical history included diabetes mellitus and peripheral vascular disease.

Diagnosis:

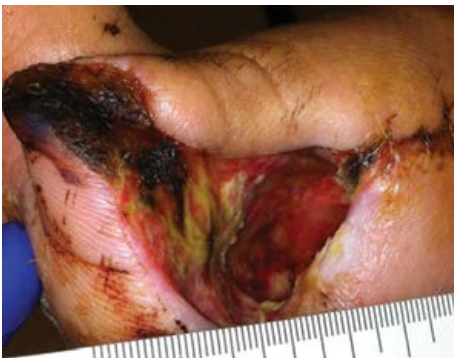The patient underwent a partial first ray resection. The patient was not a candidate for further surgical revision in the operating theatre. The patient had a postsurgical foot wound (Figure A), which necessitated the application of a disposable negative pressure wound therapy modality to facilitate wound healing.

Course of Treatment/Application of the Snap Therapy System:

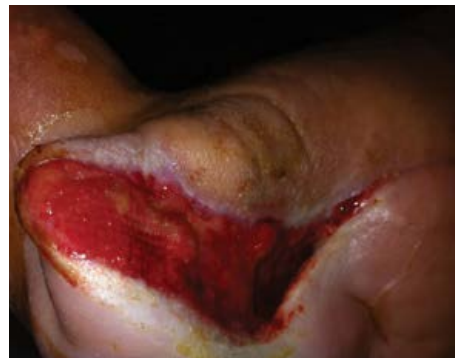After the completion of the partial first ray resection, the surgical defect was swabbed to detect any wound-resident pathogens. Microbiological assays determined that the wound was negative for any pathogenic bacterial species. The Snap therapy system was applied 10 days post-surgery as a bolster over an amniotic membrane graft, which was initially placed over the ulcer. A non-adherent layer was placed over the graft for protection, followed by application of the 3M™ Snap™ Advanced Dressing to establish a seal. The 3M™ Snap™ Therapy Cartridge administered -125mmHg of subatmospheric pressure. The Snap therapy system was administered for 4 weeks (Figure B). As the wound completely filled-in, the Snap therapy system was discontinued after 4 weeks.

Discharge and Follow-up:

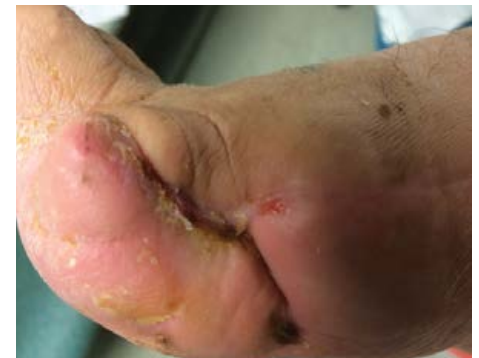The wound was evaluated after the Snap therapy system was discontinued. Use of the Snap therapy system resulted in reduction of wound volume. Wound resolution of the lower extremity was achieved with 4 additional weeks of amniotic membrane grafting to complete wound closure (Figure C).



A. Postsurgical foot wound at initial presentation.



B. Wound after 4 weeks of Snap therapy system.



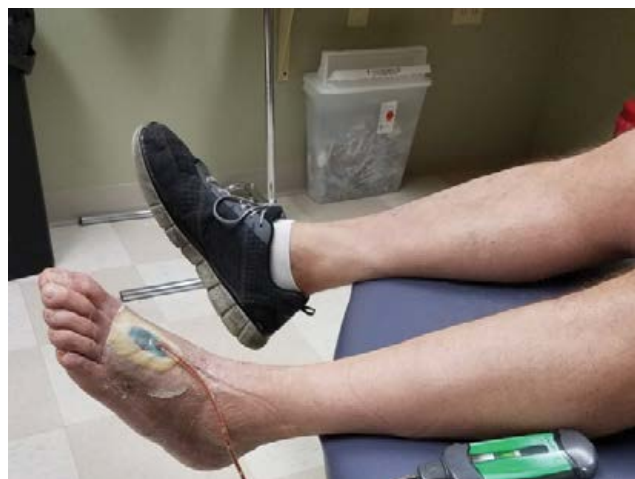C. Complete resolution of the wound following additional grafting.

Case Study 5

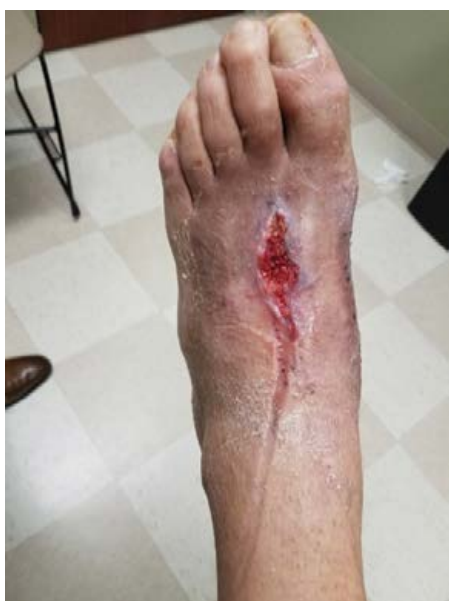Use of the 3M™ Snap™ Therapy System for management of a wound resulting from dorsal surgical dehiscence.

A 47-year-old male with a history of idiopathic neuropathy and neurotrophic arthritis (Charcot osteoarthropathy) underwent staged bilateral gastrocnemius recession surgery to offload forefoot ulcers of the left foot. Serial debridements of the plantar wound were performed, and the wounds were managed with advanced dressings and offloading. The forefoot ulcers ultimately healed, and the patient required orthopedic midfoot reconstruction due to further midfoot collapse. After the surgery, the patient later returned to the clinic with a dorsal dehiscence involving the central incision.

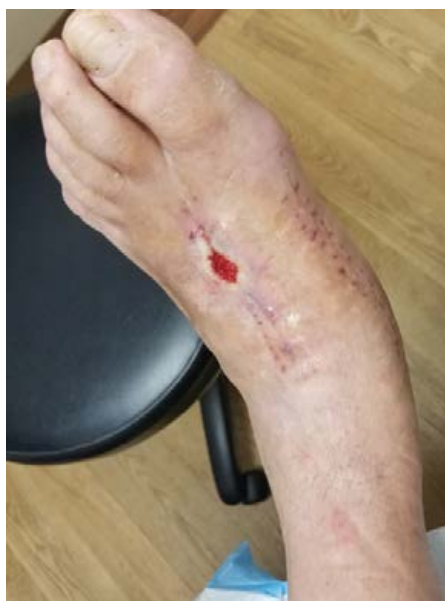Application of the Snap therapy system was initiated (Figure A), with dressing changes and maintenance debridements performed every 2-3 days (Figures B-C). This wound care plan was continued for 3 weeks, and then care transitioned to coverage with conventional dressings. Upon follow-up at 6 weeks after discontinuing use of the Snap therapy system, the incision remained closed (Figure D).



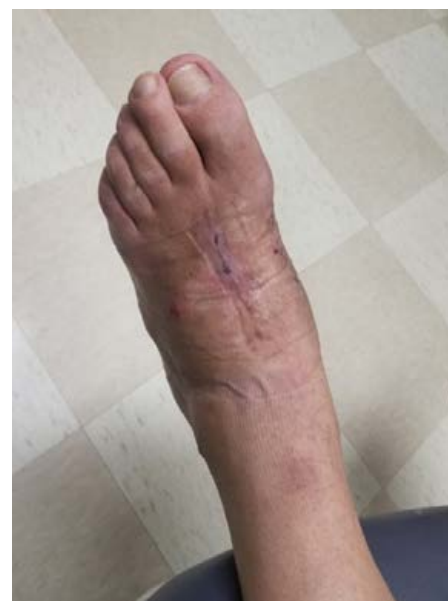A. Wound with the Snap therapy system applied.



B. Wound appearance at initial dressing change of the Snap therapy system.



C. Wound appearance after 2 weeks use of the Snap therapy system.



D. Wound appearance after 3 weeks use of the Snap therapy system and 6 weeks of coverage with conventional dressings.

Case Study 6

Use of the 3M™ Snap™ Therapy System to manage a non-healing postsurgical foot wound.

Patient:

A 57-year-old male presented to the clinic with a non-healing wound of the foot following a single-digit transmetatarsal amputation (TMA) procedure (Figure A). The patient's medical history included diabetes mellitus, end stage renal disease managed with dialysis, hypertension, and hypothyroidism. Prior to the TMA, the patient had a prior diagnosis of gangrene to the left hallux. Angioplasty was performed, and the patient underwent subsequent hallux amputation. Post TMA, the acute wound failed to heal. The wound underwent wound care for three months and demonstrated minimal granulation tissue, was fibrotic, and had a sinus measuring 1.4cm. The patient underwent an evaluation by the podiatrist to determine the course of treatment.

Diagnosis:

The patient had a non-healing postsurgical foot wound, which necessitated the application of a disposable negative pressure wound therapy modality to facilitate wound healing.

Course of Treatment/Application of the Snap Therapy System:

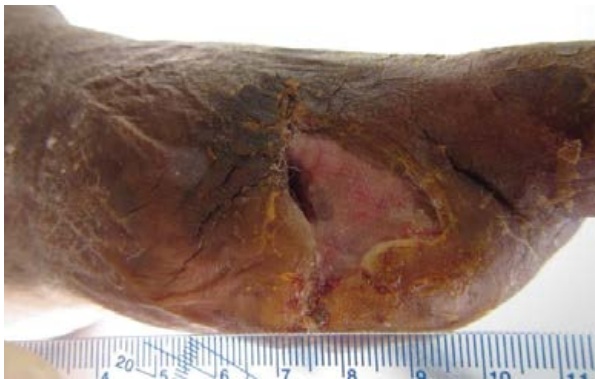The non-healing surgical defect was subject to debridement. The Snap therapy system was initiated to manage the wound. Upon completion of the debridement, the Snap therapy system foam interface dressing was applied over the surgical defect. Then, the 3M™ Snap™ Bridge Dressing was applied over the foam interface to establish a seal. The 3M™ Snap™ Therapy Cartridge administered -125mmHg of subatmospheric pressure (Figure B). The Snap therapy system was applied twice weekly. After two weeks, the sinus closed, and the wound demonstrated healthy granulation tissue (Figure C). The wound was evaluated and determined to be prepared for skin grafting. At Day 32, a split-thickness skin graft (STSG) was applied.

The 3M™ Snap™ SecurRing™ Hydrocolloid Skin Barrier was fashioned around the periphery of the wound margin to help achieve a seal in this challenging anatomical location (Figure D). A paraffin gauze dressing (JELONET; Smith & Nephew plc, London, UK) was applied over the graft to protect the STSG. The Snap therapy system was used as a bolster over the STSG for 7 days. The graft exhibited excellent take at 6 weeks (Figure E). After 7 weeks, the Snap therapy system was discontinued (Figure F).

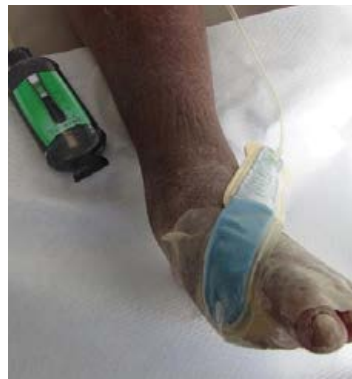Discharge and Follow-up:

At 11 weeks, the wound completely healed (Figure G). Wound resolution of the non-healing TMA was achieved within 1 weeks with the Snap therapy system and STSG.

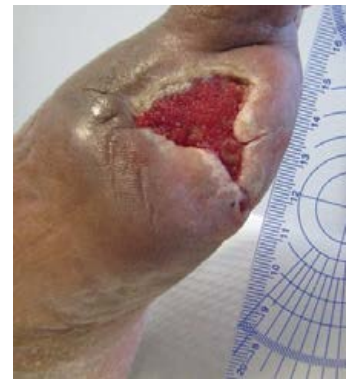Use of the 3M™ Snap™ Therapy System to manage a non-healing postsurgical foot wound. (cont.)



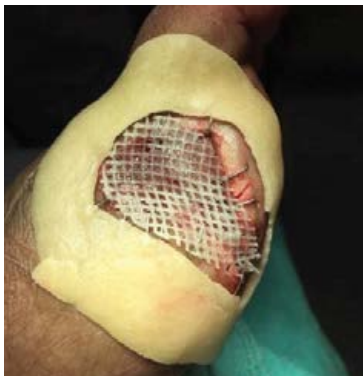A. Non-healing postsurgical TMA wound at initial presentation.



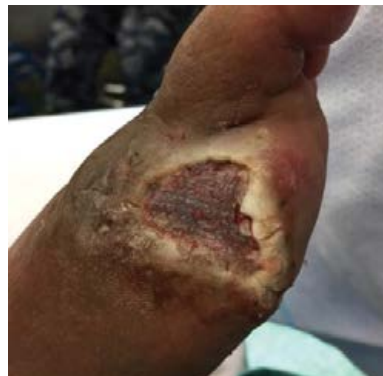B. 3M Snap™ Bridge Dressing applied to the wound.



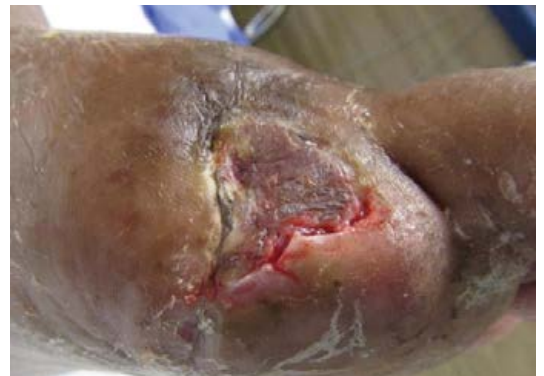C. Wound after 2 weeks use of the Snap therapy system.



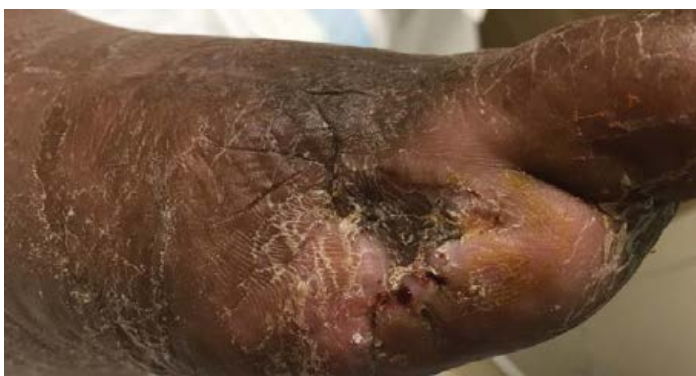D. Wound at Day 32 with 3M Snap™ SecurRing™ Hydrocolloid Skin Barrier positioned around the wound margin and the placement of a STSG.



E. Wound at 6 weeks.



F. Wound at 7 weeks.



G. Healed wound 3-months after graft placement.

Case Study 7

Use of the 3M™ Snap™ Therapy System to manage a dehisced foot wound following total metatarsal amputation.

Patient:

A 67-year-old male presented to the clinic with a dehisced wound of the foot (Figure A). Three weeks prior, the patient underwent a total metatarsal amputation (TMA) procedure. The patient's medical history included neuropathy in the absence of diabetes mellitus.

Diagnosis:

The dehisced neuropathic foot wound yielded palpable pulses. The patient had a postsurgical foot wound, which necessitated the application of a disposable negative pressure wound therapy modality to facilitate wound healing.

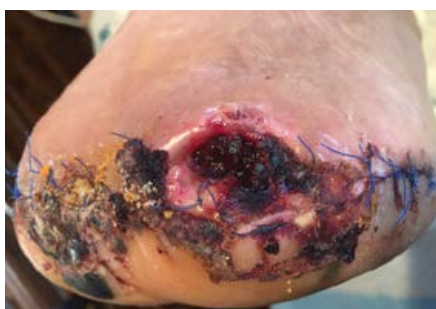Course of Treatment/Application of the Snap Therapy System:

Upon completion of the TMA, the surgical defect was subject to sharp excisional debridement (Figure B). The patient then received an amniotic mesh graft, which was placed over the dehisced wound (Figure C) and the Snap therapy system was used to bolster the graft. Initially, a non-adherent layer was placed over the amniotic membrane graft to protect the graft. The foam interface dressing was placed over the protected graft. The 3M™ Snap™ SecurRing™ Hydrocolloid Skin Barrier was fashioned around the periphery of the wound margin (Figure D). The 3M™ Snap™ Advanced Dressing was applied over the foam interface and hydrocolloid ring to establish a seal (Figures E and F). The 3M™ Snap™ Therapy Cartridge administered -125mmHg of subatmospheric pressure. After two weeks, the wound demonstrated a 30% decrease in volume, and the wound underwent a second round of debridement (Figures G and H). The Snap therapy system was continued (Figure I). After 3 weeks of treatment with the Snap therapy system, the wound demonstrated a 92% decrease in wound volume (Figure J). As the wound closed at week 4, the Snap therapy system was discontinued.

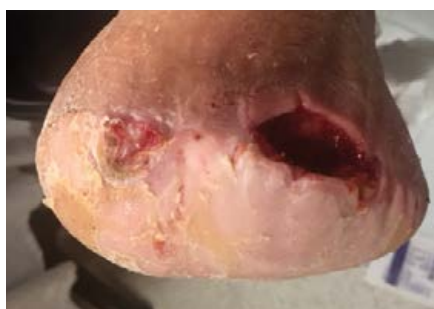Discharge and Follow-up:

Wound resolution of the lower extremity was achieved within 4 weeks with amniotic grafting and the Snap therapy system.

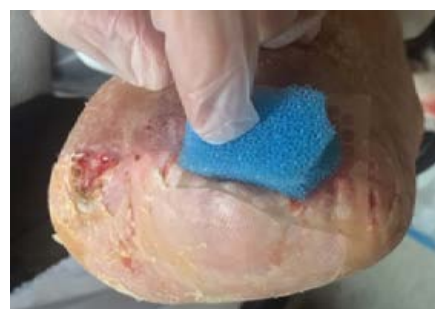Use of the 3M™ Snap™ Therapy System to manage a dehisced foot wound following total metatarsal amputation. (cont.)



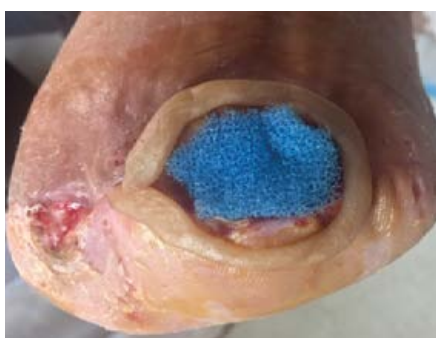A. Dehisced postsurgical foot wound at initial presentation.



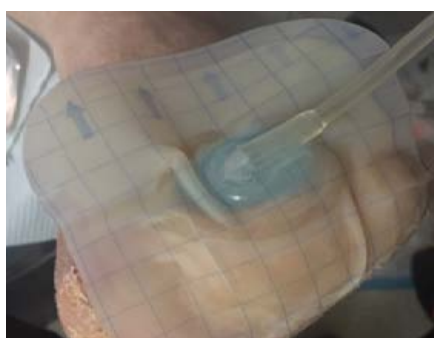B. Wound after debridement.



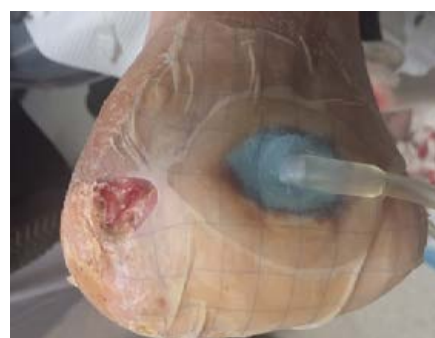C. The placement of amniotic mesh graft over the wound and the application of the Snap therapy system foam interface to bolster the graft.



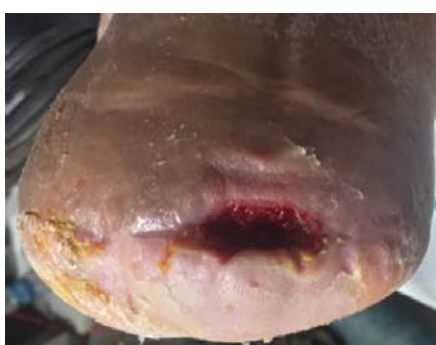D. 3M™ Snap™ SecurRing™ Hydrocolloid Skin Barrier positioned around the wound margin.



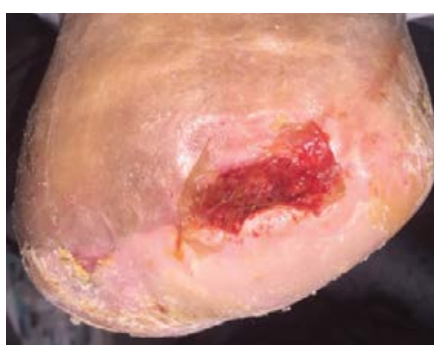
E. Placement of the 3M™ Snap™ Advanced Dressing over the foam interface and 3M™ Snap™ SecurRing™ Hydrocolloid Skin Barrier.



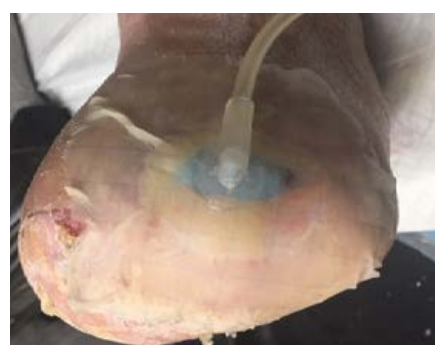F. The Snap Advanced dressing cut and contoured to the foot wound to establish a seal.



G. Foot wound after 2 weeks use of the Snap therapy system demonstrates a 30% reduction in wound volume.



H. Wound after second round of debridement.



I. Subsequent application of the Snap therapy system.

Case Study 8

Use of the 3M™ Snap™ Therapy System to manage a pressure injury.

Patient:

An 85-year-old female presented to the clinic with a calcaneal pressure injury. The patient's medical history included peripheral vascular disease, hypertension, hyperthyroidism, neuropathy, chronic kidney disease, cataracts, cardiomyopathy, and ischemic polymyalgia rheumatica.

Diagnosis:

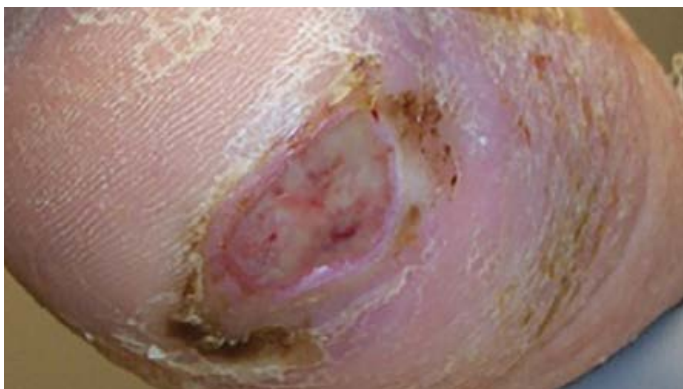
The patient had a 30-day-old stage 3 pressure injury on the right heel (Figure A). Resolution of the pressure injury called for a multimodal approach including a disposable negative pressure wound therapy system to facilitate closure of the pressure injury.

Course of Treatment/Application of the Snap Therapy System:

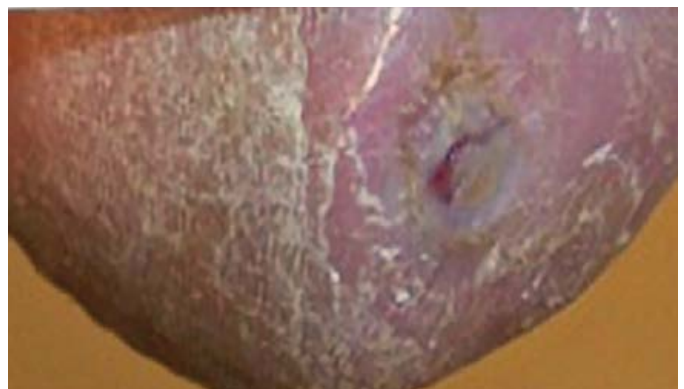The calcaneal pressure injury would be a recipient site for an epidermal graft. To prepare the donor site for epidermal harvesting, the patient's thighs underwent depilation, and were washed with isopropyl alcohol. The vacuum head of the 3M™ Cellutome™ Epidermal Harvesting System was attached to the donor site to apply subatmospheric pressure (-400mmHg to -500mmHg) and warmth (37°C to 41°C) to generate epidermal microdomes for harvest. Following epidermal grafting, the Snap therapy system was enlisted to bolster the graft. To protect the epidermal graft, a non-adherent silicone dressing (3M™ Adaptic™ Touch Non-Adhering Silicone Dressing) was applied. The Snap therapy system, foam interface dressing was applied over the protected epidermal graft, and the 3M™ Snap™ Advanced Dressing was applied over the foam interface to establish a seal. The 3M™ Snap™ Therapy Cartridge administered -125mmHg of subatmospheric pressure.

Discharge and Follow-up:

The pressure wound was evaluated after the Snap therapy system was discontinued. The pressure wound then underwent a round of sharp excisional debridement, and treatment transitioned to oxidized regenerated cellulose (ORC)/collagen/silver-ORC dressing (3M™ Promogran Prisma™ Matrix) and compression therapy with an Unna boot. The donor site healed without complications by 2 weeks post epidermal graft harvesting. The pressure wound was fully closed without complications at the 2-month follow-up visit (Figure B).



A. Wound at presentation.



B. Wound fully closed at 2-month follow-up visit.

Case Study 9

Use of the 3M™ Snap™ Therapy System to manage a venous stasis ulcer.

Patient:

An 80-year-old female presented to the clinic with a chronic venous stasis ulcer of the lower extremity, which resulted from blunt trauma with the corner of a table (Figure A). The patient's medical history included venous insufficiency and chronic lower extremity edema.

Diagnosis:

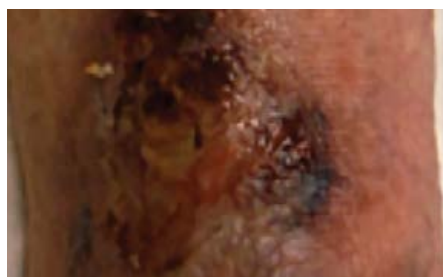The patient had a chronic venous stasis ulcer, which necessitated excisional debridement of the necrotic tissue from the lower extremity, and a multimodal approach to facilitate wound healing.

Course of Treatment/Application of the Snap Therapy System:

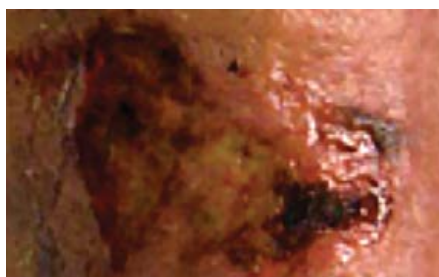
The venous stasis ulcer initially underwent sharp debridement and soaking with a stabilized hypochlorous acid solution, followed by coverage with an alginate and a foam dressing. A 2-layer compression kit was subsequently applied over the dressed wound. The wound was debrided weekly between dressing changes, and the patient was administered a prophylactic regimen of antibiotics. At post-treatment Day 17, the wound underwent further debridement, and the Snap therapy system was initiated (Figure B). The Snap therapy system dressings were changed twice per week. At post-treatment Day 73, the Snap therapy system was discontinued; however, topical therapy with compression continued (Figure C).

Discharge and Follow-up:

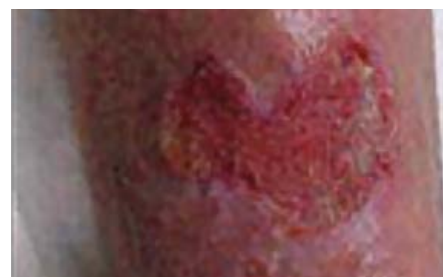At post-treatment Day 133, wound was near full reepithelialization after topical therapy and compression (Figure D). Placental allograft was used to facilitate wound closure. By post-treatment Day 196, the wound had completely reepithelialized (Figure E).



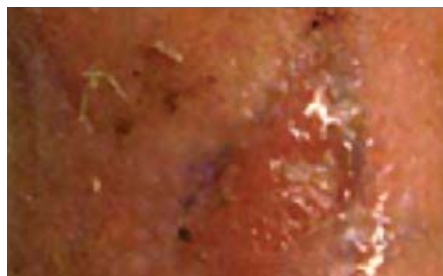
A. Chronic venous stasis ulcer at presentation.



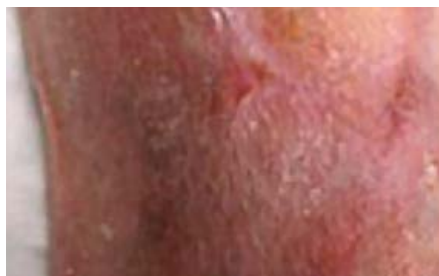B. Wound at post-treatment Day 17 and prior to the initiation of the Snap therapy system.



C. Wound after discontinuance of the Snap therapy system at post-treatment Day 73.



D. Wound at post-treatment Day 133 after topical therapy with compression.



E. Wound closure on post-treatment Day 196.

Case Study 10

Use of the 3M™ Snap™ Therapy System to manage a trauma wound to the lower extremity.

Patient:

An 83-year-old, healthy female presented to the clinic with a wound to the left lower extremity (LLE). The wound had its provenance from the patient falling from a ladder, and had resulted in subcutaneous hematoma, an extensive cavity and a necrotic flap of the anterior left leg (Figure A). The patient had been placed on cephalexin by the Emergency Department.

Diagnosis:

The patient had a traumatic wound to the LLE that measured 7 x 5 x 3cm³ with 10cm tunneling and extension to fascia/muscle. To address the traumatic wound, surgical debridement was performed to evacuate the residual hematoma and excise portions of the necrotic flap. The resultant defect was initially treated with a daily, wet-dry, antimicrobial packing using hypochlorous acid solution (Vashe® Urgo Medical North America, Fort Worth, TX) until the tunnel was resolved (3 weeks). Then the wound was managed via the application of a disposable negative pressure wound therapy modality to facilitate wound healing.

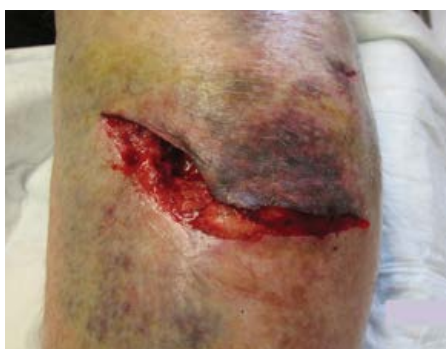Course of Treatment/Application of the Snap Therapy System:

By Day 22, the wound dimensions measured 6 x 2.5 x 1.5cm³ (Figure B), and wound management transitioned to treatment using the Snap therapy system. The Snap therapy system foam interface dressing was applied over the wound, the 3M™ Snap™ Advanced Dressing was applied to establish a seal (Figure C). The 3M™ Snap™ Therapy Cartridge administered -125mmHg of subatmospheric pressure. The Snap therapy system was applied twice weekly. After 3 days (Day 25) of Snap therapy system use, the wound was evaluated and much of the undermining had resolved (Figure D). For the second Snap therapy system application (Day 25), the wound received porcine small intestinal submucosa (SIS) matrix (Oasis® Wound Matrix; Smith & Nephew plc, London, UK) to facilitate native tissue growth (Figure E). The Snap therapy system was reapplied to the wound as a bolster using a 3M™ Snap™ Bridge Dressing over the foam wound interface (Figure F). After 7 days (Day 32), the wound measured 4 x 2.2 x 0.3cm³ and use of the Snap therapy system was discontinued (Figure G).

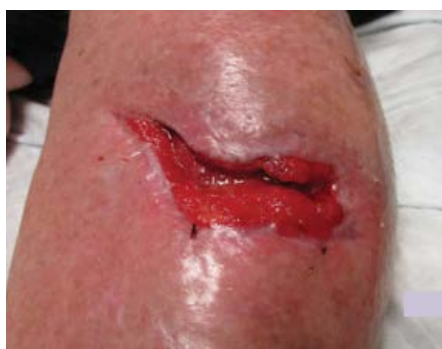Discharge and Follow-up:

After only 10 total days, the wound bed was prepared for grafting. To promote wound closure, the patient received epidermal grafts harvested using the 3M™ Cellutome™ Epidermal Harvesting System. After 62 days of wound management that enlisted debridement, wet-dry antimicrobial packing, use of the Snap therapy system, the application of SIS matrix, and epidermal grafting, the wound was completely healed (Figure H).

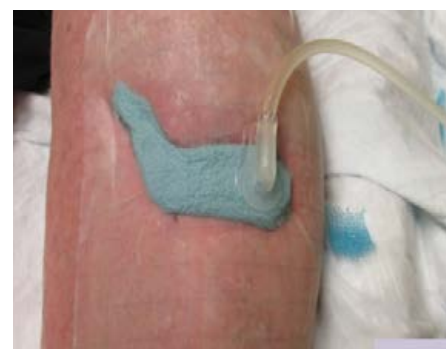Use of the 3M™ Snap™ Therapy System to manage a trauma wound to the lower extremity. (cont.)



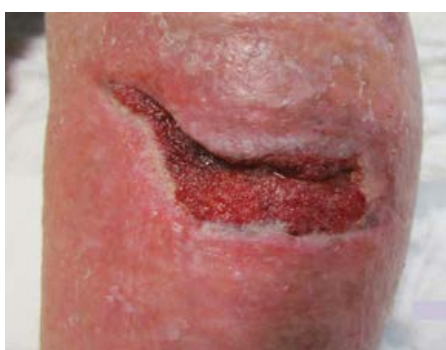A. Traumatic wound to the LLE at initial presentation.



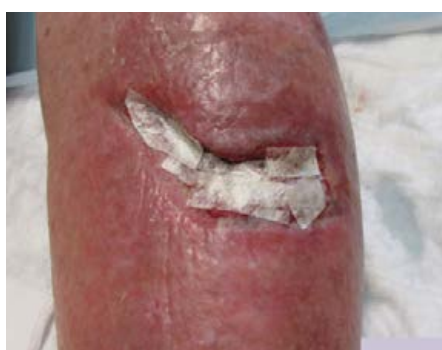B. Traumatic wound (post debridement and wet-dry packing) at Day 22.



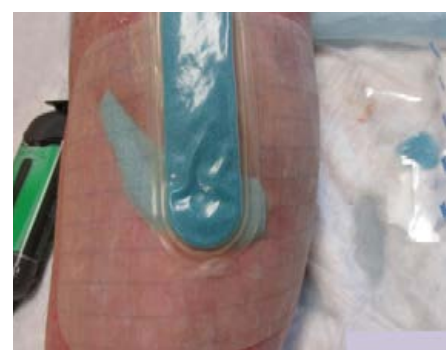C. Traumatic wound (post debridement and wet-dry packing) at Day 22 with Snap therapy system applied over Snap therapy system foam wound interface.



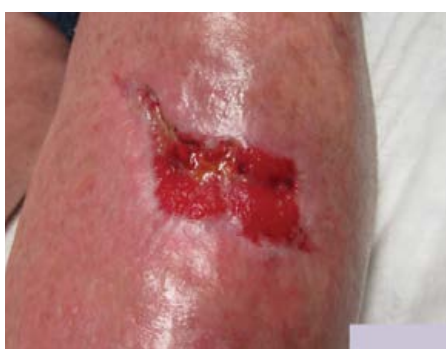D. Wound after 3 days use of the Snap therapy system.



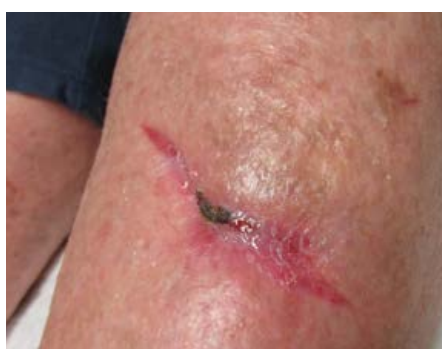E. Porcine small intestinal submucosa matrix grafting applied to wound bed.



F. Snap therapy system reapplied to wound using 3M™ Snap™ Bridge Dressing over the Snap therapy system foam interface as a bolster over the graft.



G. Wound after 10 days use of the Snap therapy system.



H. Healed traumatic wound 4-weeks post epidermal grafting at Day 62.

Case Study 11

Use of the 3M™ Snap™ Therapy System to manage a local flap over a recalcitrant acute wound.

Patient:

A 36-year-old male presented to the clinic with a recalcitrant acute wound. The patient had previously undergone a surgical procedure for the removal of a neuroma to the left ankle.

Diagnosis:

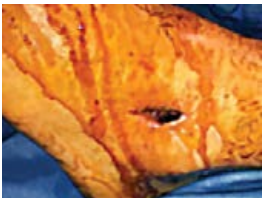The patient had a non-healing surgical wound stemming from a neuroma excision from the left ankle. The surgical defect was negative for pathogenic cultures. Resolution of the integumentary defect involved usage of a disposable negative pressure wound therapy system to facilitate wound closure via local flap.

Course of Treatment/Application of the Snap Therapy System:

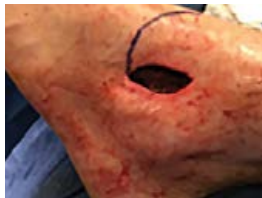The patient underwent reconstructive surgery (Figures A and B), and received a local flap to close the non-healing surgical defect on the foot (Figure C). After receiving the local flap, a hydrocolloid ring was placed around the periphery of the flap, and a protective dressing was applied over the flap. The Snap therapy system foam interface dressing was applied over the protected local flap, and the 3M™ Snap™ Advanced Dressing was applied over the foam interface to establish a seal (Figure D). The 3M™ Snap™ Therapy Cartridge administered -125mmHg of subatmospheric pressure. The Snap therapy system was applied for 7 days. The dressing was removed, and the local flap was evaluated (Figure E). No adjunctive therapies or debridements were necessary, and the Snap therapy system was discontinued after a single 7-day application.

Discharge and Follow-up:

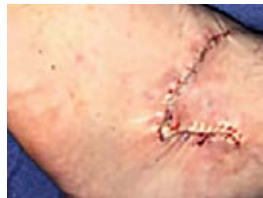Having established that there was 100% take of the local flap and definitive closure, the patient was discharged. There were no postoperative complications or any need for surgical revision.



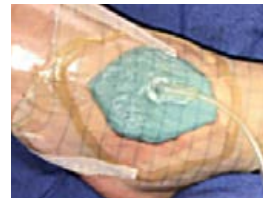
A. Non-healing surgical wound of the ankle before reconstruction (Day 1).



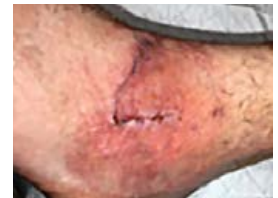B. Wound during reconstruction procedure on Day 1.



C. Ankle following reconstruction and closure via local flap on Day 1.



D. Placement of the 3M™ Snap™ Dressing over local flap on Day 1.



E. Local flap site upon removal of the Snap therapy system on Day 7.

Case Study 12

Use of the 3M™ Snap™ Therapy System to manage a dehisced wound.

Patient:

A 66-year old male underwent an open reduction internal fixation (ORIF) procedure of the left ankle

Diagnosis:

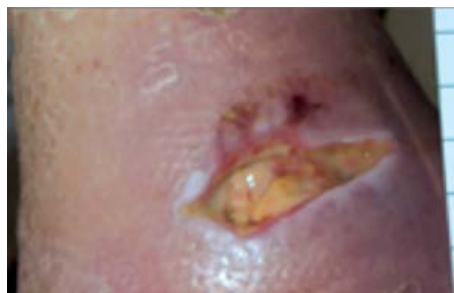Twenty-one days post ORIF, the patient presented with a dehisced ankle wound (Figure A).

Course of Treatment/Application of the Snap Therapy System:

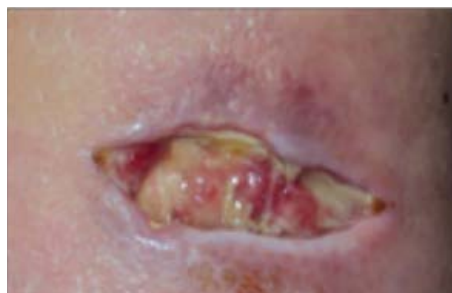
A peripherally inserted central catheter was placed, and a culture-specific antibiotic regimen (vancomycin) was administered for 14 days. The dehisced wound also received excisional debridement. The Snap therapy system was applied over the wound. The foam interface dressing was applied within the wound, and the 3M™ Snap™ Advanced Dressing was applied over the foam interface to establish a seal. The 3M™ Snap™ Therapy Cartridge administered -125mmHg of subatmospheric pressure, and dressing changes occurred twice weekly. After 2 weeks of the Snap therapy system, the wound was debrided to reduce slough (Figure B). After 4 weeks, the Snap therapy system was discontinued. At week 5, wound management transitioned to the application of an oxidized regenerated cellulose (ORC)/collagen/silver-ORC dressing (3M™ Promogran Prisma™ Matrix) to the granulated wound bed to facilitate closure (Figure C).

Discharge and Follow-up:

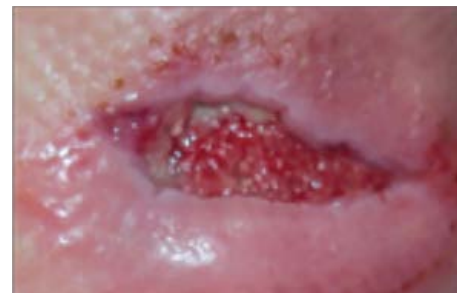At 7 weeks, the wound exhibited reepithelialization (Figure D). At the follow-up appointment, the wound demonstrated an uneventful resolution via secondary closure at 14 weeks (Figure E).



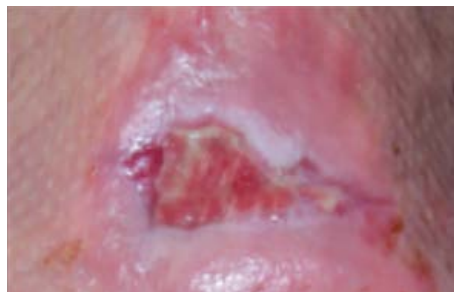A. Dehisced ankle wound at presentation post ORIF.



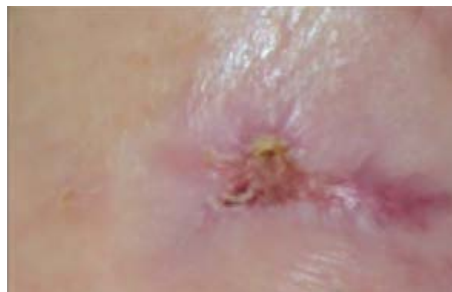B. Slough was reduced after debridement and 2 weeks of the Snap therapy system.



C. The Snap therapy system was discontinued at 4 weeks: Promogran Prisma matrix at 5 weeks and wound remained granulated.



D. Epithelializing wound at 7 weeks.



E. Wound was healed at 14 weeks.

Case Study 13

Use of the 3M™ Snap™ Therapy System to bolster a full thickness skin graft.

Patient:

An 87-year-old male presented to the clinic with a malignancy (squamous cell carcinoma) of the integumentary system localized to the dorsal forearm (Figure A). The patient had no significant prior medical history.

Diagnosis:

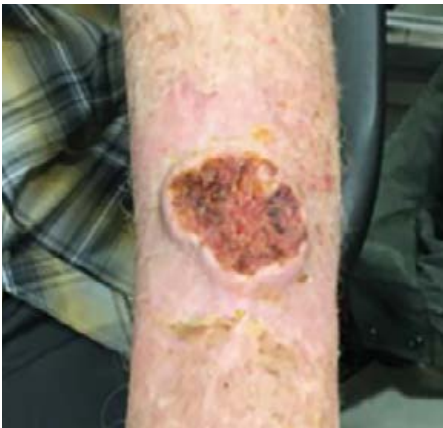The patient had a surgical defect resultant of a wide local excision of a malignant lesion, which necessitated the application of a full-thickness skin graft (FTSG) for closure of the wound. Wound margins were free and clear of malignancy prior to placement.

Course of Treatment/Application of the Snap Therapy System:

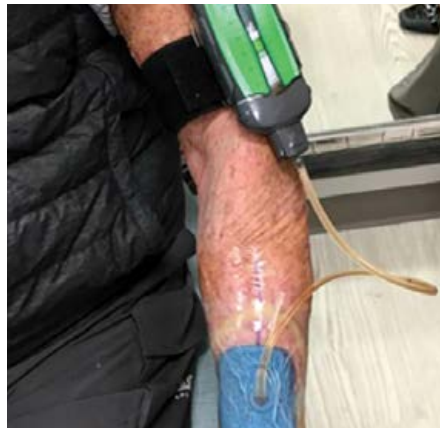Upon completion of the dermal excision procedure, the patient received a FTSG to close the surgical defect on the dorsal forearm. To protect the FTSG, a non-adherent dressing was placed over the graft. The Snap therapy system was applied over the FTSG as a bolster (Figure B). The foam interface dressing was applied over the protected graft, and the 3M™ Snap™ Advanced Dressing was applied over the foam interface to establish a seal. The 3M™ Snap™ Therapy Cartridge administered -125mmHg of subatmospheric pressure. The Snap Advanced dressing was removed on postoperative Day 5, and the graft was evaluated at 1 week postoperatively.

Discharge and Follow-up:

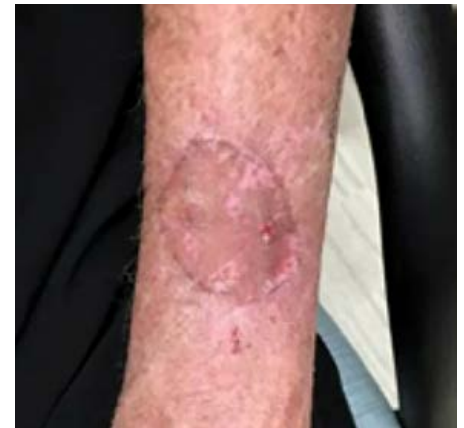The patient was discharged, and the graft was evaluated at 4, 8, and 12 weeks. By postoperative week 8, there was 100% graft take without postoperative complications or any need for surgical revision (Figure C).



A. Preoperative left dorsal forearm prior to FTSG application.



B. Postoperative placement of the Snap therapy system.



C. Postoperative follow-up at 8 weeks.

Case Study 14

Use of the 3M™ Snap™ Therapy System to manage a wound resulting from a venomous insect bite.

Patient:

A 58-year-old male presented with an apparent insect bite on the left forearm. He initially noted a red pimple forming on the skin, which rapidly enlarged over 2 weeks with increasing pain and swelling of the arm.

Diagnosis:

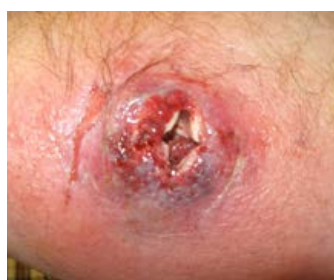The patient had an integumentary defect stemming from drainage of a venomous insect bite. A multimodal approach, which included a disposable negative pressure wound therapy system, was enlisted to facilitate wound healing.

Course of Treatment/Application of the Snap Therapy System

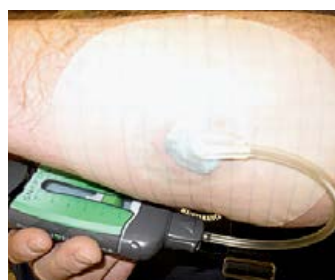Upon presentation, the patient was referred immediately for hyperbaric oxygen therapy (HBOT), which was started the next day. Irrigation and drainage was completed 48 hours after his initial presentation, and revealed a large, crater-like defect extending to the muscle with minimal exudate or purulence (Figure A). After 2 days of wound packing with silver alginate and continued HBOT, the peri-wound inflammation had subsided, and the wound bed color had improved. The Snap therapy system foam interface dressing was applied over the wound, and the 3M™ Snap™ Advanced Dressing was applied over the foam interface to establish a seal. The 3M™ Snap™ Therapy Cartridge administered -125mmHg of continuous subatmospheric pressure. After two dressing applications, the wound volume was completely reduced (Figure C).

Discharge and Follow-up:

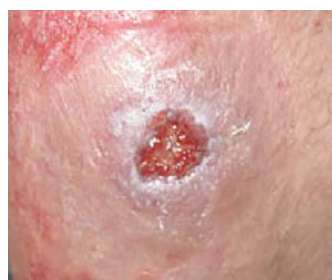The patient was able to continue working while utilizing negative pressure and did not require disability. He went on to complete closure, only requiring 17 HBOT treatments and 6 weeks of care (Figure D).



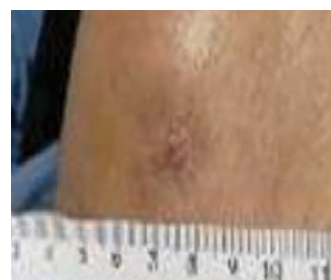A. Wound appearance after irrigation and drainage; 48 hours after presentation.



B. Application of the Snap therapy system, 2 days post irrigation and drainage.



C. Reduced wound volume after two dressing applications.



D. Wound closure after 6 weeks.

Case Study 15

Use of the 3M™ Snap™ Therapy System to manage a trauma wound to the lower extremity.

Patient:

A 70-year-old male presented to the clinic with a wound to the right upper extremity (Figure A). The patient underwent an evaluation by the clinician to determine the course of treatment. The medical history of the patient included hypertension, chronic obstructive pulmonary disease, tobacco use (2 packages of cigarettes per day), atrial fibrillation, and hyperlipidemia. The patient was noted as taking an anti-coagulant (warfarin) to manage their cardiovascular disease. The patient's only form of transportation was a motorcycle.

Diagnosis:

The patient had a surgical wound to the dorsal aspect of the right hand resultant of intravenous (IV) infiltration and a burn from a heat pack. The defect would be managed via the application of a disposable negative pressure wound therapy modality to facilitate wound healing.

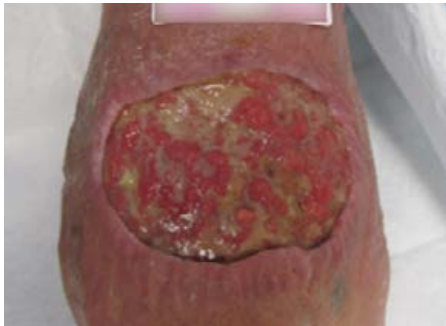Course of Treatment/Application of the Snap Therapy System:

The surgical defect was occupied with slough and underwent ultrasound debridement (Figure B) to excise the damaged and burned tissue. The Snap therapy system was enlisted to promote wound healing following the excision of damaged tissue and for exudate management. Prior to the application of the Snap therapy system, the 3M™ Snap™ SecurRing™ Hydrocolloid Skin Barrier was proximally placed superior to the wound and a non-adherent contact layer dressing was then placed over the wound bed (Figure C). The Snap therapy system foam interface was cut to size and applied over the defect; the 3M™ Snap™ Advanced Dressing was applied over the foam interface to establish a seal (Figure D). The 3M™ Snap™ Therapy Cartridge administered -125mmHg of subatmospheric pressure (Figure E). The Snap therapy system was applied twice weekly. The placement of the Snap therapy system did not impinge on the patient's manual dexterity and did not impede operational ability with respect to the preferred method of transportation (Figure F). The wound was evaluated at Day 10 following the initial application of the Snap therapy system and demonstrated an even distribution of granulation tissue within the wound bed and minimal slough (Figure G). At Day 14 following the initial application of the Snap therapy system, the wound was reevaluated, and it was noted that the wound edges had reattached (Figure H). The Snap therapy system was discontinued and the patient transitioned to an antimicrobial foam dressing.

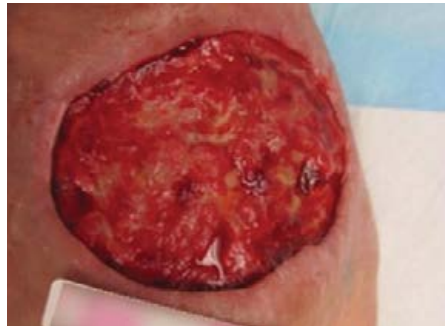Discharge and Follow-up:

After 3 weeks of wound management the wound was completely healed (Figure I). For this patient, the Snap therapy system was ideal due to the ease of use. Additionally, the portability of the Snap therapy system and the ability to cut the tubing allowed for greater mobility so as not to interfere with the patient's ability to operate his motorcycle.

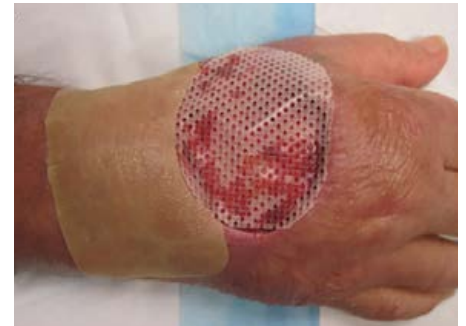Use of the 3M™ Snap™ Therapy System to manage a trauma wound to the lower extremity. (cont.)



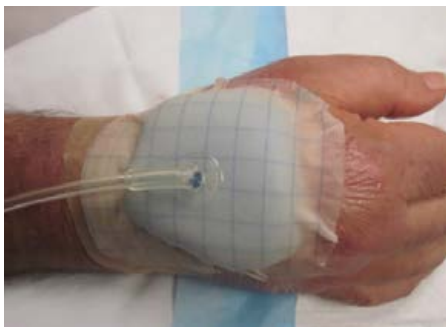A. Surgical defect to the dorsal aspect of the right hand. Wound at presentation.



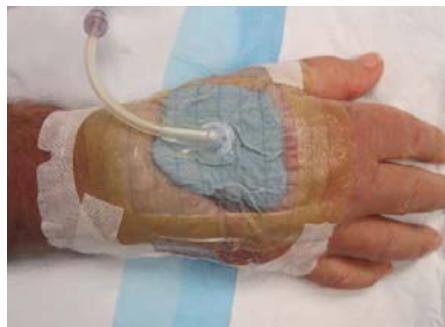B. Wound after ultrasound debridement.



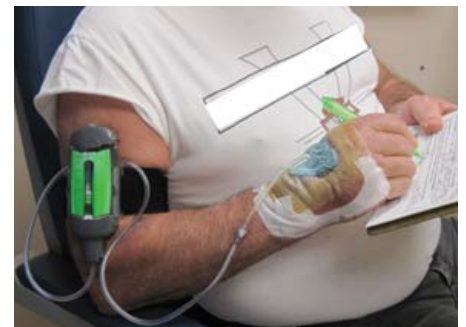C. The application of the Snap therapy system.



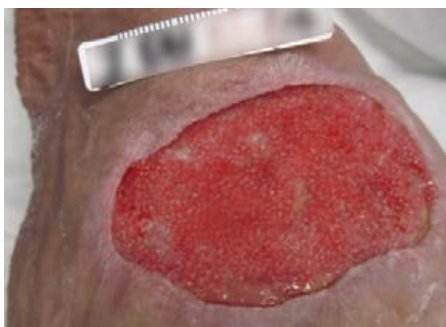
D. The application of the Snap therapy system as a bolster over the graft.



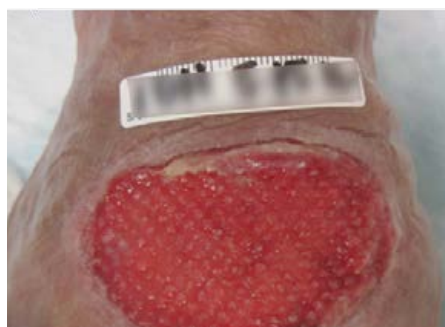E. The application of Snap therapy system as a bolster over graft.



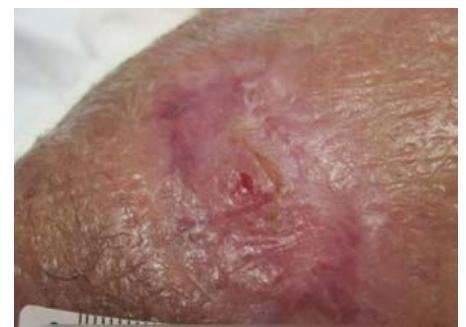F. The placement of the Snap therapy system did not interfere with the patient's ability to operate his vehicle.



G. Wound progression following use of the Snap therapy system. Wound at Day 10.



H. Wound at Day 14.



I. Wound at 3 weeks.

Case Study 16

Use of the 3M™ Snap™ Therapy System to manage a dehisced wound post tenosuspension of the pollex.

Patient:

A 67-year-old female was referred to the clinic by an external orthopedic surgeon for consultation. The patient presented with a postsurgical wound to the right hand. The patient recently underwent a tendon translocation (tenosuspension) procedure to resolve opposability of the pollex. The surgical wound became infected and was subject to two, separate operative debridements. The patient had no known comorbidities. The patient underwent an initial evaluation to determine the course of treatment (Figure A).

Diagnosis:

The patient had a dehisced wound status post tenosuspension procedure involving the right pollex. To address the postsurgical wound, the defect was managed with disposable negative pressure wound therapy to facilitate wound healing.

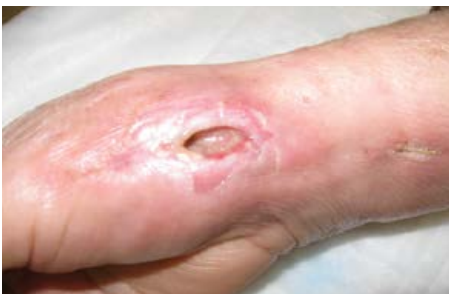Course of Treatment/Application of the Snap Therapy System:

The dehisced wound was managed using the Snap therapy system. The 3M™ Snap™ SecurRing™ Hydrocolloid Skin Barrier was applied around the periwound. The Snap therapy system foam interface dressing was applied over the wound. The 3M™ Snap™ Advanced Dressing was applied to establish a seal (Figure B). The 3M™ Snap™ Therapy Cartridge administered -125mmHg of subatmospheric pressure to the dressed wound. The Snap therapy system was applied twice weekly.

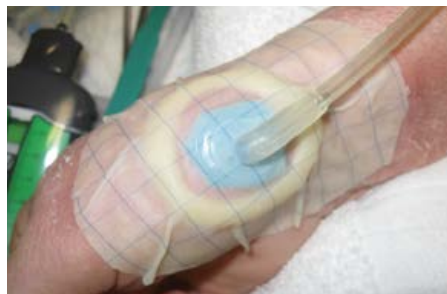After 5 dressing changes, use of the Snap therapy system was discontinued.

Discharge and Follow-up:

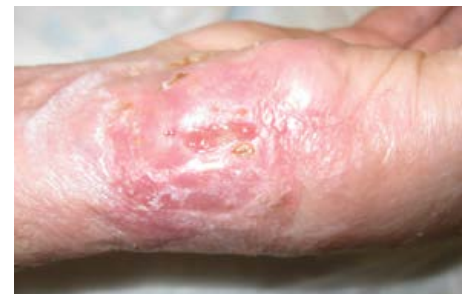Once the Snap therapy system was discontinued, the wound was evaluated. After 5 dressing changes (2 weeks of use of the Snap therapy system), the wound demonstrated complete epithelialization and wound closure was attained (Figure C).



A. Dehisced wound at initial presentation.



B. 3M™ Snap™ SecurRing™ Hydrocolloid Skin Barrier placed around the wound periphery. Snap Advanced Dressing applied over reticulated open cell foam wound interface and connected to Snap therapy cartridge.



C. Closed epithelialized wound after 2 weeks use of the Snap therapy system.

Case Study 17

Use of the 3M™ Snap™ Therapy System to manage a surgical defect open to the deep fascia of the upper extremity.

Patient:

A 78-year-old female with a history of methicillin-resistant *Staphylococcus aureus* (MRSA) presented with an abscess in the upper extremity.

Diagnosis:

The patient had a surgical defect following the incision and drainage of a MRSA abscess in the antecubital fossa (Figure A), which necessitated excisional debridement of the surgical defect.

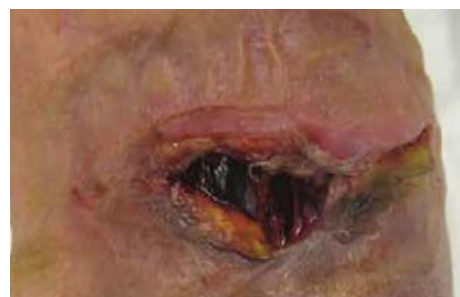Course of Treatment/Application of the Snap Therapy System:

Sharp debridement was performed prior to initial application of the Snap therapy system and again 2 weeks later (Figure B). No adjunctive advanced wound care modalities were utilized.

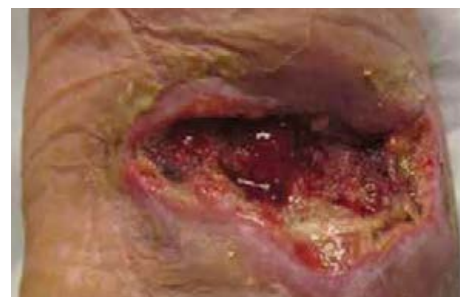Five applications of the Snap therapy system resulted in reduction in wound volume.

Discharge and Follow-up:

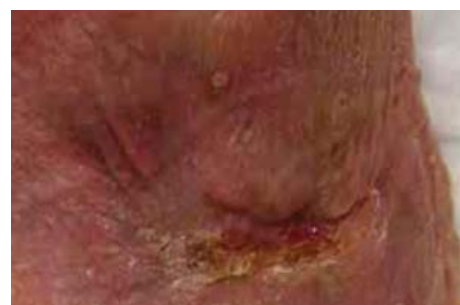Use of the Snap therapy system aided in wound volume reduction, including complete resolution of the integumentary integrity following incision and drainage of a MRSA abscess. Wound resolution of the antecubital fossa was achieved in 4 weeks (Figure C).



A. Wound at presentation.



B. Wound after second debridement.



C. Wound fully healed at 4 weeks.

Case Study 18

Use of the 3M™ Snap™ Therapy System to manage a wound resulting from a postoperative surgical complication.

Patient:

A 40-year-old female was referred to the clinic with a surgical site complication (Figure A). The patient was previously treated with topical silver sulfadiazine (Silvadene®, Pfizer Inc., New York, NY) for the treatment of wound sepsis, and was seen by her original surgeon for 4 weeks prior to clinic referral. The patient, who was otherwise healthy, recently traveled to the Dominican Republic for cosmetic surgery. The patient underwent liposuction to the flanks; however, the surgical site subsequently developed necrotic areas.

Diagnosis:

The patient developed diminished tissue integrity with necrosis to the left flank and wound sepsis following cosmetic surgery. A disposable negative pressure wound therapy system was enlisted to prepare the wound bed; then other advanced modalities were used to further reduce the wound dimensions as well as facilitate reepithelialization and closure of the surgical defect.

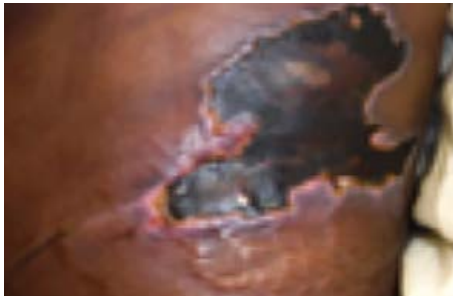Course of Treatment/Application of the Snap Therapy System:

During the first week of treatment, the patient underwent exogenous debridement with topical collagenase ointment (SANTYL®, Smith & Nephew plc, London, UK). For the second week of treatment, the wound was debrided and swabbed to detect any wound-resident pathogens following microbiological assays. Tests revealed that the wound was positive for the yeast, *Candida parapsilosis*, and the patient was administered an antifungal agent, fluconazole (Diflucan®, Pfizer Inc., New York, NY). At week 3, the wound was debrided further; then treatment transitioned to the application of a maltodextrin wound dressing (Multidex®, DeRoyal Industries, Inc., Powell, TN) to maintain a moist wound environment and a bacteriostatic polyvinyl alcohol foam dressing (Hydrofera Blue®, Hollister, Libertyville, IL). During the 4th week, the wound was debrided, and the Snap therapy system was applied to the wound. At follow-up during week 5, the wound exhibited granulation tissue (Figure B). The wound received further debridement, and the Snap therapy system was continued. During the 6-week follow-up, the wound bed had an even distribution of healthy granulation tissue (Figure C). The wound was debrided, and wound management continued with the Snap therapy system. At week 8, the Snap therapy system was discontinued, and the wound was debrided.

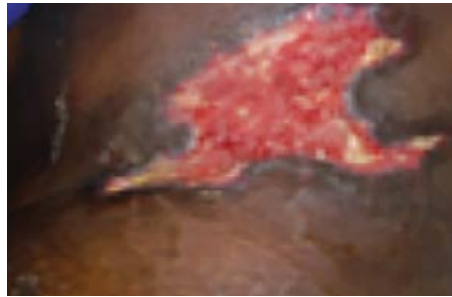Discharge and Follow-up:

The granulated wound bed was evaluated after the Snap therapy system was discontinued, and therapy transitioned to the application of an oxidized regenerated cellulose (ORC)/collagen/silver-ORC dressing (3M™ Promogran Prisma™ Matrix). After treatment with an ORC/collagen/silver-ORC dressing, the wound bed was reduced in size, and was prepared to receive epidermal grafting (Figure D). By week 9, an epidermal harvesting system (3M™ Cellutome™ Epidermal Harvesting System) was used to harvest epidermal grafts to cover the wound. At 12 weeks, the wound had completely reepithelialized (Figure E). In total, this particular wound underwent seven rounds of debridement within the clinic in conjunction with four weeks of the Snap therapy system.

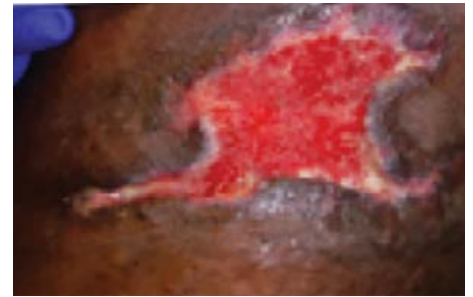Use of the 3M™ Snap™ Therapy System to manage a wound resulting from a postoperative surgical complication. (cont.)



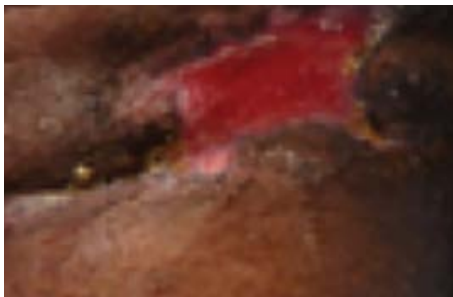A. Surgical wound at presentation with necrotic tissue compression.



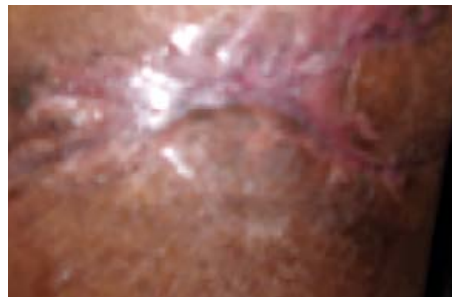B. Wound after initial treatment with the Snap therapy system (Week 5).



C. Wound after second treatment with the Snap therapy system (Week 6).



D. Wound at Week 9 after the application of 3M™ Promogran Prisma™ Matrix.



E. At 12 weeks wound was reepithelialized.

Case Study 19

Use of the 3M™ Snap™ Therapy System to manage an acute wound (pilonidal cyst).

Patient:

An otherwise healthy female patient presented to the clinic with a pilonidal cyst. A small pilonidal sinus with a depth of 3cm was located directly superior to the pilonidal cyst.

Diagnosis:

The patient had an acute wound/surgical defect resultant of the excision and drainage of the pilonidal cyst. A disposable negative pressure wound therapy modality was enlisted to facilitate wound healing and achieve closure.

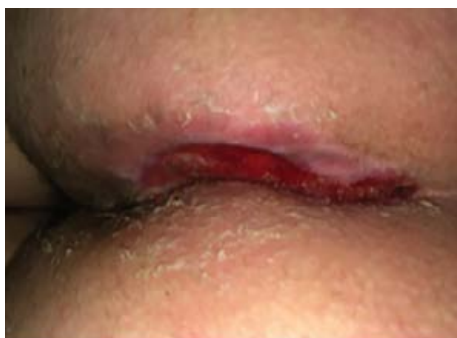Course of Treatment/Application of the Snap Therapy System:

Upon completion of the excision and drainage procedure, the patient was treated for 4 months with standard wound dressings. After 4 months of standard care, the wound measured 5.3cm x 1.2cm x 0.5cm, producing under 10ml of serous exudate per day. Granulation tissue was present in the wound bed, and the periwound skin was intact with viable wound edges. The wound showed no signs of infection. The Snap therapy system foam interface was applied over the wound, and the 3M™ Snap™ Advanced Dressing was applied over the foam interface to establish a seal. The Snap therapy system was initiated with -125mmHg of continuous negative pressure and paired with a barrier wipe drape to protect the surrounding skin. Dressings were changed twice per week. After 5 days of the Snap therapy system, the wound had reduced in size, measuring 5.2cm x 1cm x 0.4cm (Figure A). A continuous reduction in wound volume was noticeable at each dressing change (Figures B and C), with wound dimensions of 4cm x 0.5cm x 0.2cm after 29 days using the Snap therapy system (Figure D). At this timepoint, the depth of the superior pilonidal sinus had reduced to 0.2cm. After 36 days of the Snap therapy system, the wound depth had resolved, and the wound bed measured 2cm x 1cm x 0cm (Figure E). The Snap therapy system was discontinued.

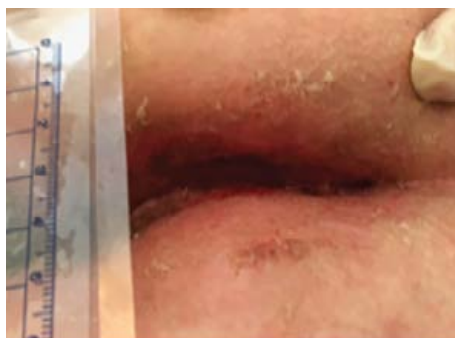Discharge and Follow-up:

Therapy was then stepped down to coverage with a povidone-iodine dressing, which was held in place with a self-adherent, absorbent secondary dressing. The wound continued to improve (Figure F), and healed completely within 2 weeks.

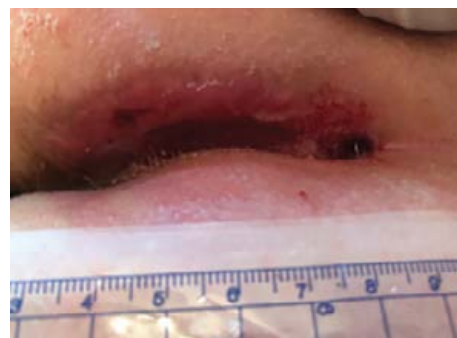
Use of the 3M™ Snap™ Therapy System to manage an acute wound (pilonidal cyst). (cont.)



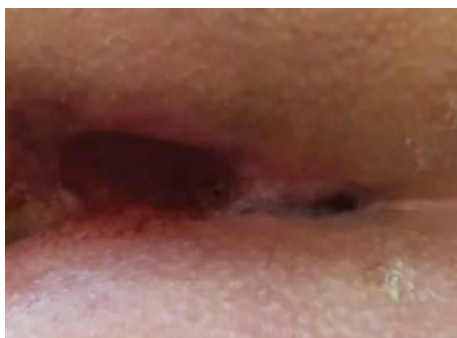A. Wound after 5 days of the Snap therapy system.



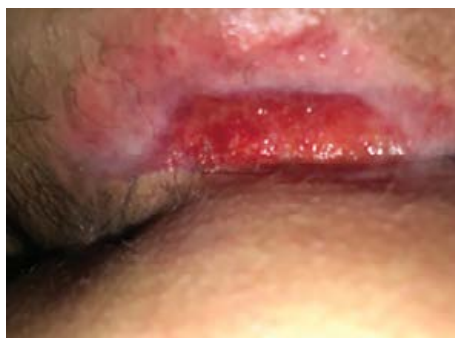B. Wound after 12 days of the Snap therapy system.



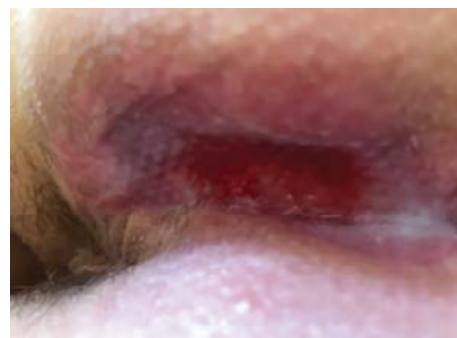C. Wound after 19 days of the Snap therapy system.



D. Wound after 29 days of the Snap therapy system.



E. Wound after 36 days of the Snap therapy system.



F. Wound 5 days after step down to treatment with sterile dressings.

3M™ Snap™ Therapy System Ordering Information*

3M™ Snap™ Therapy Cartridge



SKU: SNPA100
Pressure: -125mmHg
Capacity: 150ml



SKU: SNPA100
Pressure: -100mmHg
Capacity: 60ml



SKU: SNPA075
Pressure: -75mmHg
Capacity: 60ml

3M™ Snap™ Plus -125mmHg Therapy Cartridge



SKU: SNPA125
Pressure: -125mmHg
Capacity: 60ml

3M™ Snap™ Therapy Strap



SKU: STPAS
Size: Small 18"



SKU: STPAM
Size: Medium 21"



SKU: STPAL
Size: Large 24"

3M™ Snap™ Plus Therapy Strap



SKU: STPASP
Size: Small 18"



SKU: STPAMP
Size: Medium 21"



SKU: STPALP
Size: Large 24"

3M™ Snap™ Bridge Dressing Kit



SKU: BKTF14X11
Size: 14cm x 11cm
Interface: Foam



SKU: BKTF14X11S
Size: 14cm x 11cm
with Snap™ SecurRing™
Hydrocolloid Skin Barrier
Interface: Foam

3M™ Snap™ Advanced Dressing Kit



SKU: SKTF10X10
Size: 10cm x 10cm
Interface: Reticulated
Open Cell Foam (blue)



SKU: SKTF15X15
Size: 15cm x 15cm
Interface: Reticulated
Open Cell Foam (blue)

3M™ Snap™ SecurRing™ Hydrocolloid Skin Barrier



SKU: SRNG10
Size: 2" diameter

* All products may not be available in your region. Please contact your local representative for your regional SKU.

For additional information, please contact your local representative.

Reference:

1. Armstrong DG, Marston WA, Reyzelman AM, Kirsner RS. Comparative effectiveness of mechanically and electrically powered negative pressure wound therapy devices: a multicenter randomized controlled trial. *Wound Repair and Regen.* 2012;20(3):332-341.

NOTE: As with any case study, the results and outcomes should not be interpreted as a guarantee or warranty of similar results. Individual results may vary depending on the patient's circumstances and condition.

NOTE: Specific indications, contraindications, warnings, precautions, and safety information exist for these products and therapies. Please consult a clinician and product instructions for use prior to application. Rx only.

© 2021 3M. All rights reserved. 3M and the other marks shown are marks and/or registered marks. Unauthorized use prohibited. 70-2011-8210-5 PRA-PM-US-02162 (05/21)



3M Company
2510 Conway Ave
St. Paul, MN 55144 USA

Phone 1-800-275-4524 (NPWT products)
1-800-228-3957
Web 3M.com/medical