



Dermatac™
Drape

3M™ Dermatac™ Drape with 3M™ V.A.C.® Therapy case studies



Introduction

This booklet includes case studies across multiple wound types. As with any case study, the results and outcomes should not be interpreted as a guarantee or warranty of similar results. Individual results may vary depending on the patient's condition and circumstances.

Table of Contents

3M™ Dermatac™ Drape indications	4
3M™ Dermatac™ Drape overview	5
Case study 1: Traumatic left lower extremity wounds	6
Case study 2: Below knee amputation	8
Case study 3: Lower extremity arterial ulcer	9
Case study 4: Management of right foot dehiscence	10
Case study 5: Left foot dehiscence wounds	12
Case study 6: Wound dehiscence following lumbar fusion	14
Case study 7: Dehisced abdominal wound post reconstruction	16
Case study 8: Bolster over skin graft	17
Case study 9: Acute wound following incision	18

3M™ Dermatac™ Drape indications

The 3M™ Dermatac™ Drape is an accessory to the:

- 3M™ ActiV.A.C.™ Therapy System, 3M™ V.A.C.® Simplicity Therapy System, 3M™ V.A.C.® Via Therapy Unit and V.A.C. FREEDOM™ Therapy System, which are integrated wound management systems for use in acute, extended and home care settings
- 3M™ V.A.C.® Ulta Therapy System and 3M™ V.A.C.® RX4 Therapy System, which are integrated wound management systems for use in acute care settings and other professional healthcare environments where product use is conducted by or under the supervision of a qualified healthcare professional.

Integrated wound management systems for use in acute care settings and other professional healthcare environments where product use is conducted by or under the supervision of a qualified healthcare professional.

When used on open wounds, they are intended to create an environment that promotes wound healing by secondary or tertiary (delayed primary) intention by preparing the wound bed for closure, reducing edema, promoting granulation tissue formation and perfusion, and by removing exudate and infectious material. Open wound types include: chronic, acute, traumatic, subacute and dehisced wounds, partial-thickness burns, ulcers (such as diabetic, pressure or venous insufficiency), flaps and grafts.

When used on closed surgical incisions, they are intended to manage the environment of surgical incisions that continue to drain following sutured or stapled closure by maintaining a closed environment and removing exudates via the application of negative pressure wound therapy.

3M™ Dermatac™ Drape contraindications

- Do not place foam dressings of the 3M™ V.A.C.® Therapy System directly in contact with exposed blood vessels, anastomotic sites, organs or nerves.
- V.A.C.® Therapy is contraindicated for patients with
 - Malignancy in the wound
 - Necrotic tissue with eschar present

Note: Refer to Warnings section in Instructions for Use for Osteomyelitis information

- Non-enteric and unexplored fistulas
- Necrotic tissue with eschar present

Note: After debridement of necrotic tissue and complete removal of eschar, 3M™ V.A.C.® Therapy may be used.

Warning: **Do not use** Dermatac Drape over open abdomen or with 3M™ AbThera™ Open Abdomen Negative Pressure Therapy. Use over the open abdomen may result in an inability to maintain a negative pressure seal.

Product introduction

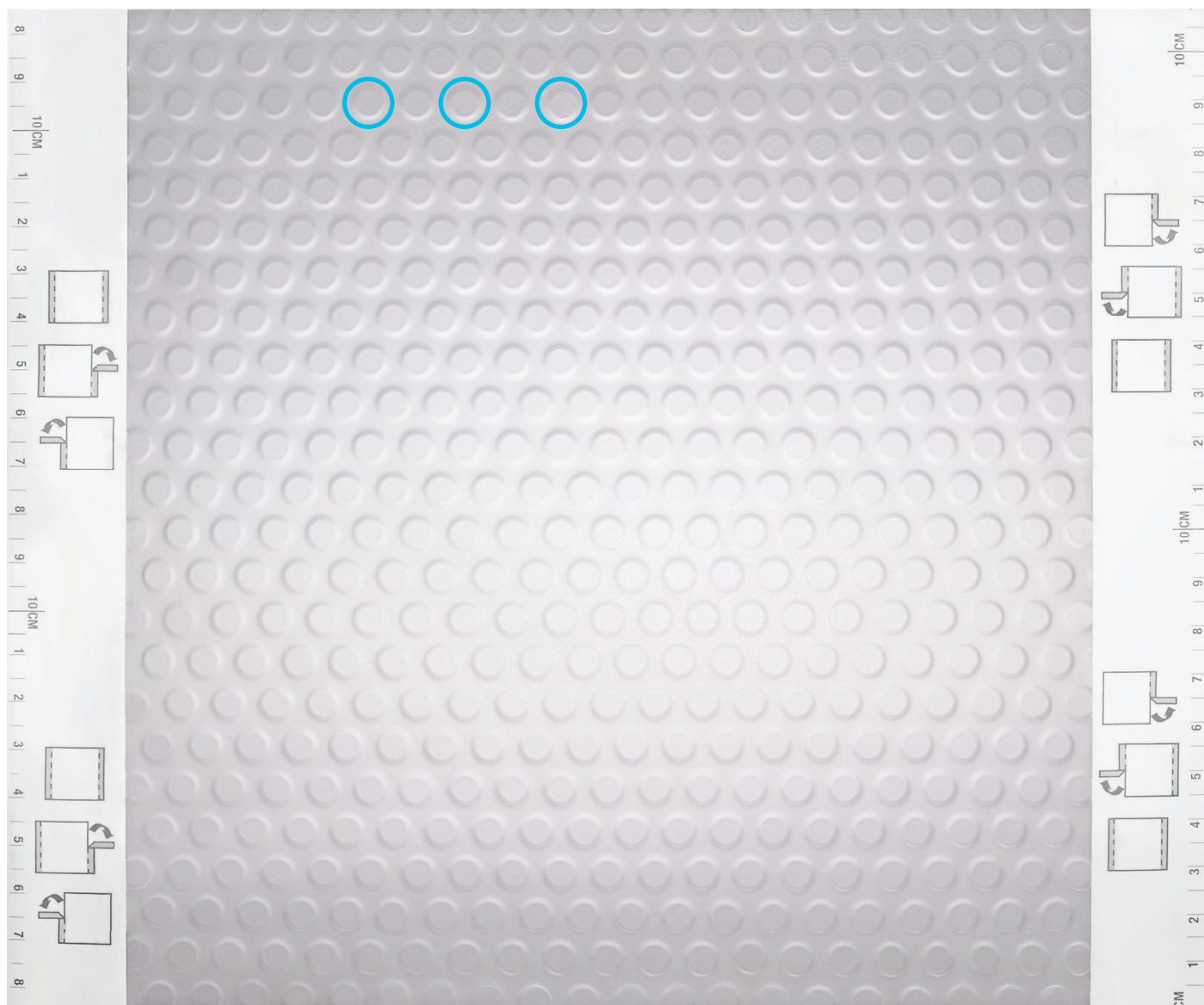
The 3M™ Dermatac™ Drape is a hybrid drape for 3M™ V.A.C.® Therapy. It is the first silicone-acrylic drape that provides the ideal balance for wound healing support.

Acrylic (inside the circles)

- Ensures tight seal to protect wounds on all anatomical locations.

Silicone (outside the circles)

- Allows for repositioning upon initial application and easy handling during dressing changes.



Case study 1

3M™ V.A.C.® Therapy and 3M™ Dermatac™ Drape use as a bolster over split-thickness skin graft applications to traumatic left lower extremity wounds

Allen Gabriel, MD, FACS; Maci Plaffenberger, PA-C; Elizabeth Eldenburg, MPAS;
Davi Mayer, cmA; Jessica Nelson, LPN; Rebecca Gold, BA, MSIII
Plastic Surgery, Vancouver, WA

Patient

A 44-year-old male presented with a self-inflicted gunshot wound to the left medial thigh with extensive soft tissue and muscular damage. Following extensive resuscitation and reestablishment of blood flow to the distal leg, compartment releases were performed. The patient was transfused with 24 units of blood and remained in critical condition. When patient was cleared to have additional surgeries, bony stabilization of the femur was achieved with a large bone loss and soft tissue loss around the mid-thigh. The distal compartment release wound measuring 20cm x 12cm x 0.1cm (**Figure 1**) and medial thigh wound measuring 6cm x 8cm x 10cm (**Figure 3**) were treated with 3M™ Veraflo™ Therapy during the medical optimization period. No previous medical history was reported.

Left lateral calf wound

Previous treatment included a calf fasciotomy due to a diagnosis of compartment syndrome and Veraflo Therapy for 5 days to promote granulation tissue development in the wound. Split thickness skin grafts (STSGs) were applied to the wound followed by application of V.A.C.® Therapy as a bolster using foam dressing and Dermatac Drape, an innovative film composed of silicone and acrylic. After 7 days, V.A.C.® Therapy was discontinued, and the graft showed 100% graft take (**Figure 2**).

Left medial thigh wound

Previous treatment included Veraflo Therapy for 14 days to cleanse the wound bed. The patient underwent reconstruction of the medial thigh wound and internal hardware coverage with antibiotic bone cement followed by three different muscle flaps. The patient was then treated with additional one week of Veraflo Therapy followed by discharge with V.A.C.® Therapy using foam dressing and Dermatac Drape. Dressing changes occurred every 48-72 hours. An increase in wound bed granulation tissue was observed during the 14 days of V.A.C.® Therapy use (**Figures 4-6**). An STSG procedure was performed, followed by application of V.A.C.® Therapy using foam dressing and 3M™ Dermatac™ Drape as a bolster (**Figure 7**). After 7 days, V.A.C.® Therapy was discontinued, and the graft showed 100% graft take. The patient then underwent bone grafting to the femur with removal of the bone cement. During care, minimal patient-reported pain was recorded during dressing changes and removal (1/10, using the Visual Analog Scale).

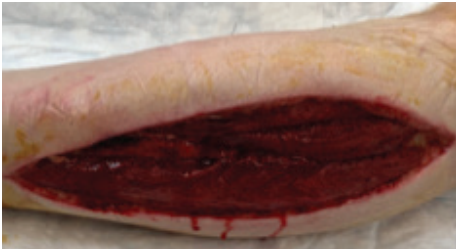


Figure 1. Left lateral calf at presentation (20cm x 12cm x 0.1cm).

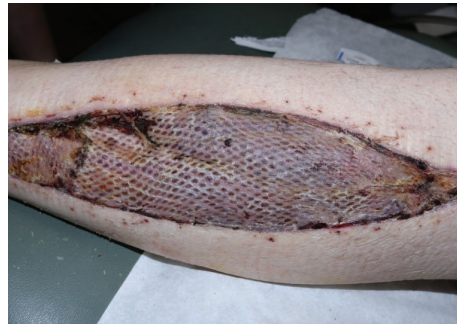

Figure 2. Left lateral calf wound after 7 days of 3M™ V.A.C.® Therapy using foam dressing and 3M™ Dermatac™ Drape over split-thickness skin grafts.

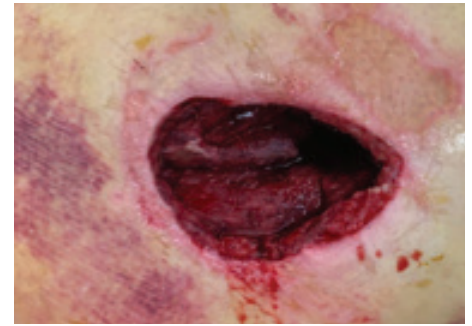


Figure 3. Left medial thigh wound at presentation (6cm x 8cm x 10cm).

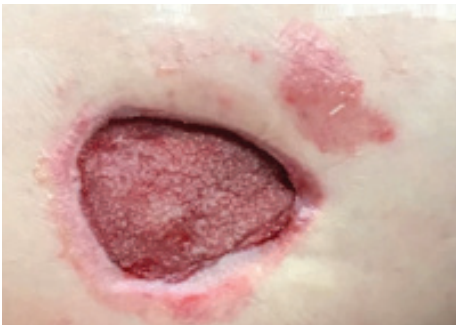


Figure 4. Left medial thigh wound after 10 days of 3M™ V.A.C.® Therapy using foam dressing and 3M™ Dermatac™ Drape.

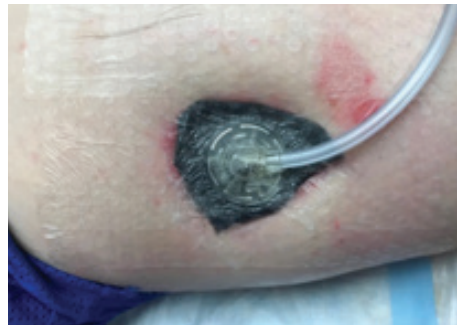


Figure 5. Application of 3M™ V.A.C.® Therapy using foam dressing and 3M™ Dermatac™ Drape to the left medial thigh wound.

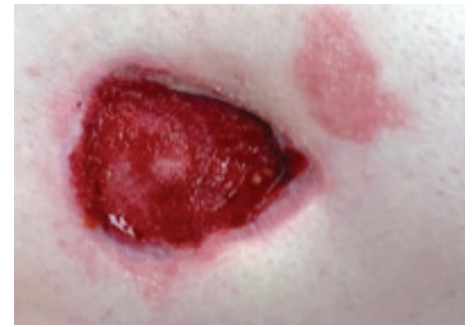


Figure 6. Left medial thigh wound after 14 days of 3M™ V.A.C.® Therapy using foam dressing and 3M™ Dermatac™ Drape.

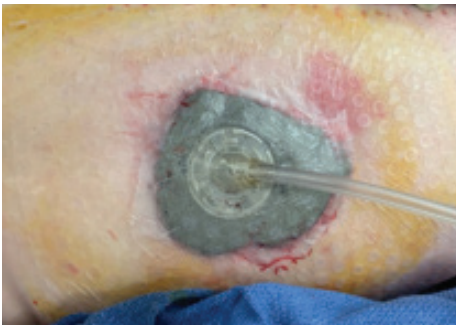

Figure 7. Application of 3M™ V.A.C.® Therapy using foam dressing and 3M™ Dermatac™ Drape following the skin grafting procedure.

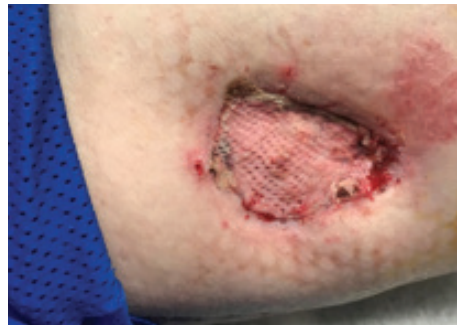


Figure 8. Left medial thigh wound after 7 days of 3M™ V.A.C.® Therapy using foam dressing and 3M™ Dermatac™ Drape.

Case study 2

3M™ V.A.C.® Therapy using 3M™ Dermatac™ Drape to manage surgical dehiscence of a below knee amputation

Marcus S. Speyrer, RN, CWS

The Wound Treatment Center, LLC, at Opelousas General Health System; Opelousas, LA, USA

Patient

A 66-year-old diabetic male presented to the wound care clinic for management of a surgical wound dehiscence that measured 5 × 15 × 1cm (**Figure 1**). He had a prior medical history of peripheral vascular disease and peripheral artery disease. The patient was recently hospitalized and referred to the operating room to undergo a left below knee amputation (BKA). Due to complications post-BKA, the surgical wound edges dehiscd medially and laterally. Prior to the patient arriving at the wound care clinic, the dehiscd wound was treated for 30 days. Treatment entailed 20 rounds of hyperbaric oxygen therapy and included surgical debridement.

At the wound care clinic, the wound was evaluated and V.A.C.® Therapy using Dermatac Drape, an innovative drape composed of silicone and acrylic was enlisted to manage the surgical dehiscence. V.A.C.® Therapy using the Dermatac Drape was applied over the wound (**Figure 2**). Dressing changes occurred every 3 days. The Global Pain Scale (GPS; score 0-10) was used to assess nociception after the removal of Dermatac Drape during dressing changes. GPS scores were recorded during each visit, and we reported a single instance in which the patient noted a GPS score of 2 after drape removal. No pain medication was administered. Seven days after the initiation of V.A.C.® Therapy, the wound measured 5 × 8.5 × 0.6cm laterally and 3 × 4.5 × 0.1cm medially (**Figure 3**). After 35 days, the wound measured 2.5 × 4.5 × 0.4cm laterally and 2 × 2.3cm medially and V.A.C.® Therapy was discontinued (**Figure 4A**). The wound bed demonstrated 100% healthy tissue granulation and medium exudate; no wound complications were noted. The patient transitioned to other wound care modalities. After 56 days, the medial dehiscence had resolved completely, and the lateral dehiscence measured 2 × 2cm (**Figure 4B**).

In this patient, application and repositioning of Dermatac Drape were easily accomplished and did not alter the ability to maintain a seal in all applications. Ease of application reduced clinician time applying V.A.C.® Therapy, and the ease of Dermatac Drape removal helped yield less discomfort in this patient. Zero complications or reports of skin irritation/sensitization were noted with use of Dermatac Drape.

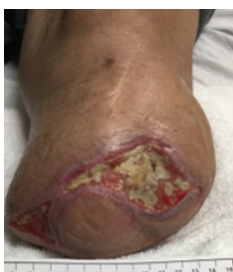

Figure 1. Patient at presentation with surgical wound dehiscence of left below knee amputation (BKA).

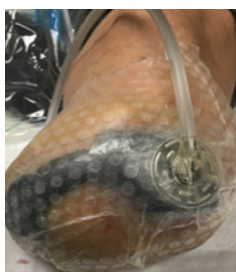

Figure 2. The initial application of 3M™ V.A.C.® Therapy with 3M™ Dermatac™ Drape.

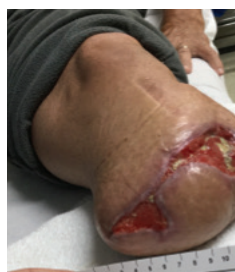

Figure 3. BKA wound after 7 days of 3M™ V.A.C.® Therapy.

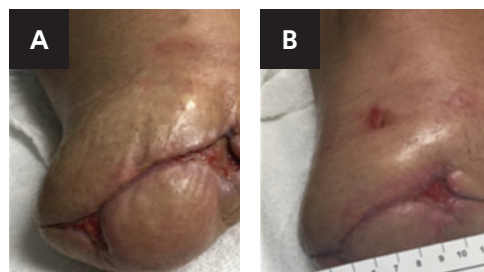


Figure 4. BKA wound after 3M™ V.A.C.® Therapy was discontinued.

A. BKA wound after 35 days of 3M™ V.A.C.® Therapy.

B. Medial dehiscence had resolved completely, and the lateral dehiscence measured 2 × 2 cm at day 56.

Case study 3

Management of a lower extremity arterial ulcer using 3M™ V.A.C.® Therapy with 3M™ Dermatac™ Drape

Marcus S. Speyrer, RN, CWS

The Wound Treatment Center, LLC, at Opelousas General Health System; Opelousas, LA, USA

Patient

A 71-year-old female presented with a 13-month-old arterial ulcer of the left lower extremity. The patient had several comorbidities, including a BMI of 36.2 kg/m², peripheral vascular disease, and diabetes mellitus. Previous treatments included surgical and non-surgical wound debridements, followed by the placement of various types of advanced wound dressings.

Diagnosis

At presentation to the wound care clinic, the wound measured 7.8 × 3.8 × 0.5cm (**Figure 1**).

Course of treatment/application of 3M™ V.A.C.® Therapy with 3M™ Dermatac™ Drape

After initial debridement, V.A.C.® Therapy was applied continuously at -125mmHg using 3M™ V.A.C.® Granufoam™ Dressing and Dermatac Drape (an innovative film composed of silicone and acrylic), and oral antibiotics were administered. The foam dressing and drape were changed every 2-3 days, and the wound was assessed for granulation tissue formation weekly. After ten days of V.A.C.® Therapy, the wound measured 8.8 × 5.6 × 0.3cm, and there was an improvement in granulation tissue formation within the wound bed. V.A.C.® Therapy using the dressing and Dermatac Drape was then re-applied and continued (**Figure 2**). There continued to be an improvement in wound bed granulation tissue at 28 days (**Figure 3**) and at 49 days, when the wound had 90% healthy tissue granulation, medium exudate levels, and no complications (**Figure 4**).

Discharge and follow-up

After 49 days, V.A.C.® Therapy was discontinued, and the patient was transitioned to wound treatment using 3M™ Promogran Prisma™ Matrix.

At each dressing change, the patient reported minimal pain related to the removal of the Dermatac Drape (0 using the Global Pain Scale of 0 to 10), and the patient required no pain medication within 1 hour of any drape change.

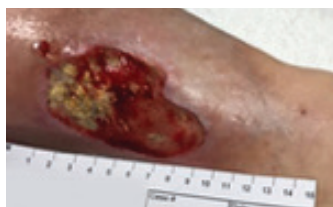

Figure 1. Left lower extremity arterial ulcer at presentation.

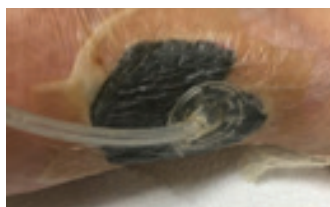

Figure 2. Wound on Day 10 after re-application of 3M™ V.A.C.® Therapy using 3M™ V.A.C.® Granufoam™ dressing and 3M™ Dermatac™ Drape.

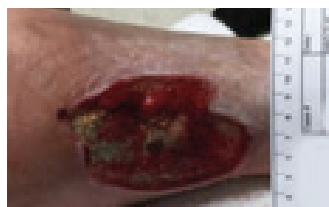

Figure 3. Wound on Day 28 dressing change.

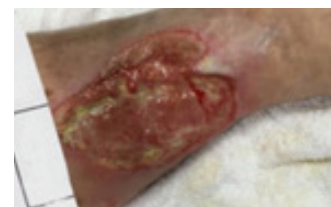

Figure 4. Wound after 49 days of 3M™ V.A.C.® Therapy using 3M™ V.A.C.® Granufoam™ dressing and 3M™ Dermatac™ Drape.

Case study 4

Management of right foot dehiscence using 3M™ V.A.C.® Therapy with 3M™ Dermatac™ Drape

Ralph Napolitano, Jr., DPM, CWSP, FACFAS; Orthoneuro; New Albany, OH

Patient

An otherwise healthy 61-year-old female with a foot deformity presented to the clinic for a complex right forefoot reconstruction. Orthopedic healing appeared to progress normally; however, the site developed a dermal dehiscence involving both the dorsal and medial incisions.

Diagnosis

The wounds were managed with serial debridements and 3M™ Silvercel™ Antimicrobial Alginate Dressing. The dorsal incision successfully healed, but the medial incision demarcated and increased in depth.

Course of treatment/application of 3M™ V.A.C.® Therapy with 3M™ Dermatac™ Drape

At the time V.A.C.® Therapy was initiated, the wound measured $2.0 \times 1.5 \times 0.5\text{cm}^3$ and was mostly fibrinous with a small area of exposed bone. V.A.C.® Therapy was applied at -125mmHg , using a foam dressing and Dermatac Drape, an innovative film composed of silicone and acrylic (**Figures 1-2**). Dressing changes were conducted per the manufacturer's instructions. After 4 days, the wound was smaller, measuring $2.0 \times 1.2 \times 0.3\text{cm}^3$, and appeared slightly less fibrinous and more granular, with a small area of exposed bone (**Figure 3**). After the first dressing change, the patient was asked to estimate pain using a 10-point Visual Analog Scale. She indicated that pain level was 2/10. V.A.C.® Therapy was resumed using the same settings as before.

Discharge and follow-up

After 5 days, the wound measured $2.0 \times 1.0 \times 0.2\text{cm}^3$ and was mostly granular with a small area of exposed bone (**Figure 4**). After the dressing change, the patient evaluated her pain as 1/10. At this time, V.A.C.® Therapy was discontinued due to the small size of the wound.

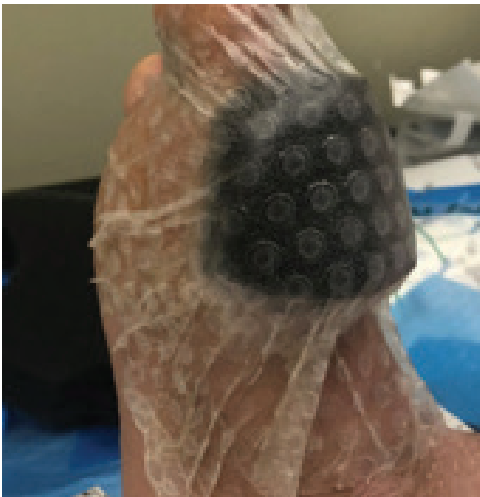

Figure 1. Application of 3M™ V.A.C.® Therapy with 3M™ Dermatac™ Drape.

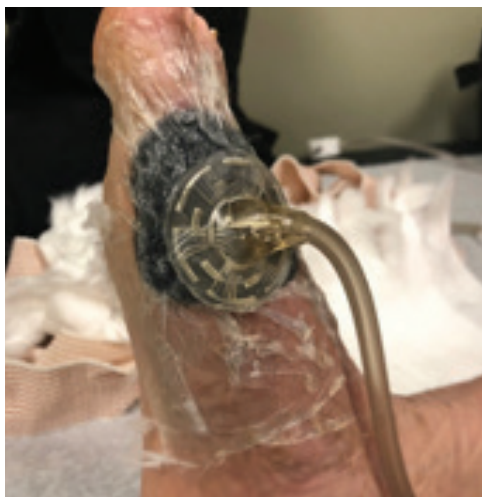

Figure 2. Initiation of 3M™ V.A.C.® Therapy.

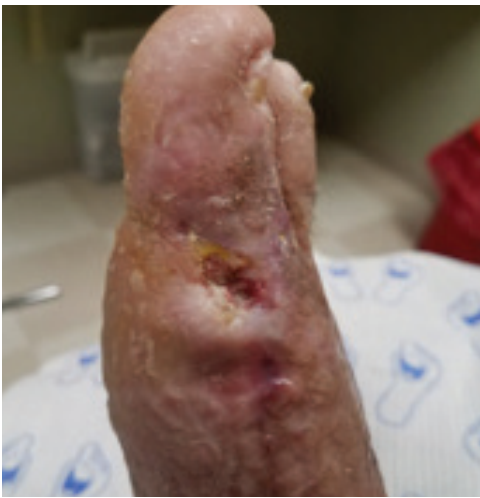

Figure 3. Wound appearance after 4 days of 3M™ V.A.C.® Therapy.

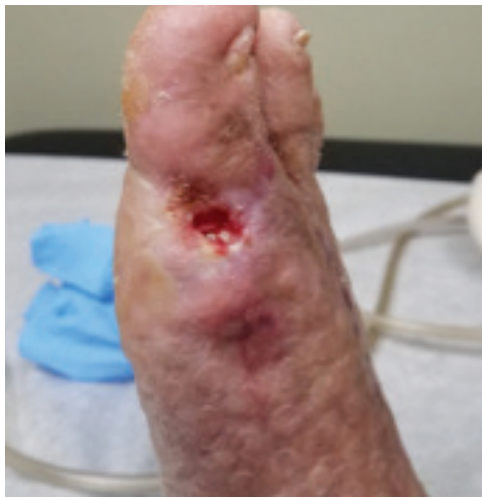

Figure 4. Granulated wound after 9 days of 3M™ V.A.C.® Therapy.

Case study 5

Management of left foot dehiscence wounds using 3M™ V.A.C.® Therapy with 3M™ Dermatac™ Drape

Ralph Napolitano, Jr., DPM, CWSP, FACFAS; Jeffrey Gittins, DO; Orthoneuro; New Albany, OH

Patient

A 74-year-old female with idiopathic neuropathy developed a Charcot foot deformity in the left foot in the absence of diabetes. She underwent major foot reconstruction for advanced neurotrophic osteoarthropathy.

Diagnosis

She developed significant swelling resulting in dehiscence of 4 incisional wounds. Wound measurements were $6.5 \times 3 \times 0.1 \text{ cm}^3$, $2 \times 1.5 \times 1 \text{ cm}^3$, $2 \times 2.5 \times 0.1 \text{ cm}^3$, and $3 \times 1 \times 2 \text{ cm}^3$, and were mostly covered with fibrinogen and exposed myofascial structures and hardware.

Course of treatment/application of 3M™ V.A.C.® Therapy with 3M™ Dermatac™ Drape

Initial treatment consisted of debridement and 3M™ Veraflo™ Therapy with normal saline using standard drape. Normal saline was instilled with a dwell time of 6 minutes and 3.5-hour cycles at -125mmHg. Dressing changes were performed per the manufacturer's instructions. After 1 week, wound management was transitioned to V.A.C.® Therapy using a foam dressing and Dermatac Drape, an innovative film composed of silicone and acrylic. Negative pressure was set at -125mmHg, and dressings were changed every 2-3 days. After a second week, there was an overall decrease in wound volume, less fibrinogen, and a definite decrease in wound depth (**Figure 1**). Subtle granulation was beginning to form over hardware (**Figure 2**), and there was no sign of periwound maceration. At this time, the wound dimensions had decreased to $6 \times 2.8 \times 0.1 \text{ cm}^3$, $2 \times 1.5 \times 0.6 \text{ cm}^3$, $2 \times 2 \times 0.1 \text{ cm}^3$, and $3 \times 0.5 \times 1.5 \text{ cm}^3$.

After an additional 2 weeks of V.A.C.® Therapy, there was further wound contracture and decrease in depth (**Figure 3**). The wound bed showed increased coverage with granulation and a decrease in fibrinogen. The periwound tissues remained healthy. Wound dimensions measured $5.5 \times 2.1 \times 0.1 \text{ cm}^3$, $1.8 \times 1 \times 0.5 \text{ cm}^3$, $1.8 \times 1.6 \times 0.1 \text{ cm}^3$, and $2 \times 0.5 \times 1 \text{ cm}^3$.

Discharge and follow-up

Upon follow-up 3 months later, the 3 smaller wounds had completely closed (**Figure 4**). For the dorsomedial wound, the patient returned to surgery to remove the hardware and undergo debridement. 3M™ Veraflo™ Therapy was applied for 3 days to cleanse the wound, instilling normal saline with a dwell time of 6 minutes and 3.5-hour cycles at -125mmHg. Therapy was changed to V.A.C.® Therapy with foam dressing and Dermatac Drape, and treatment is still ongoing.

According to patient feedback, use of the Dermatac Drape with V.A.C.® Therapy was markedly more comfortable compared to traditional drape, both while worn and during dressing changes. The patient was asked to score their pain levels using the 1-10 ranked Visual Analog Scale after dressing changes; pain scores never exceeded 1 out of 10. In this particular case, in which multiple wounds were involved and bridging was necessary, there was an observed decrease in overall staff time required to apply V.A.C.® Therapy with Dermatac Drape.

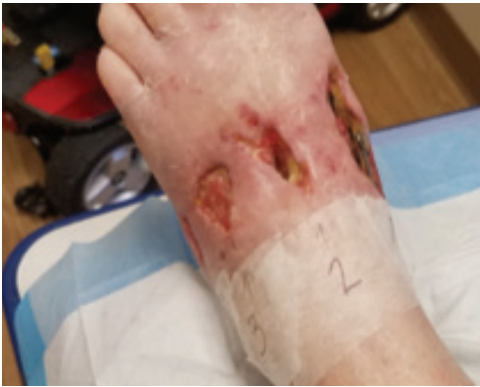

Figure 1. Dehiscent wounds after debridement, 1 week of 3M™ Veraflo™ Therapy with standard drape, and 1 week of 3M™ V.A.C.® Therapy with 3M™ Dermatac Drape.

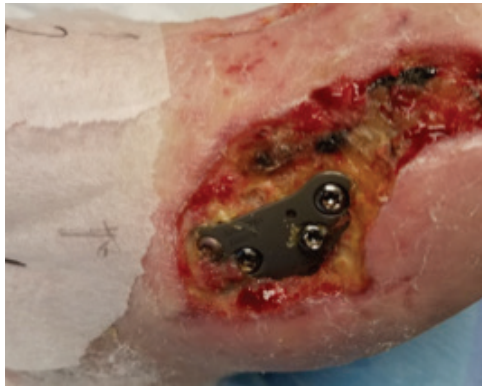


Figure 2. Appearance of the dorsomedial wound after debridement, 1 week of 3M™ Veraflo™ Therapy with standard drape, and 1 week of 3M™ V.A.C.® Therapy with 3M™ Dermatac Drape.

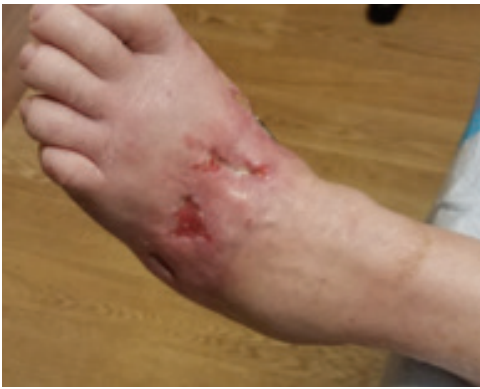

Figure 3. Dehiscent wounds after 3 weeks of 3M™ V.A.C.® Therapy with 3M™ Dermatac Drape.

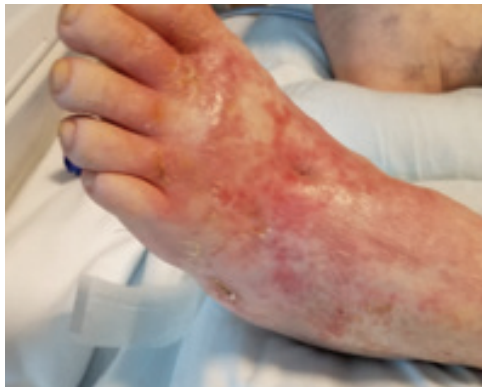

Figure 4. Closure of the 3 smaller dehiscent wounds at the 3-month follow-up.

Case study 6

3M™ V.A.C.® Therapy using 3M™ Dermatac™ Drape to manage wound dehiscence following lumbar fusion

Marcus S. Speyrer, RN, CWS

The Wound Treatment Center, LLC, at Opelousas General Health System; Opelousas, LA, USA

Patient

A 46-year-old diabetic female presented to the wound care clinic for management of a surgical wound dehiscence (**Figure 1A**). She had a prior medical history of obesity, hypertension and smoking tobacco use.

Diagnosis

Previous treatment included a calf fasciotomy due to a diagnosis of compartment syndrome and 3M™ Veraflo™ Therapy for 5 days to promote granulation tissue development in the wound. Split thickness grafts (STSGs) were applied to the wound followed by application of V.A.C.® Therapy as a bolster using foam dressing and Dermatac Drape, an innovative film composed of silicone and acrylic. After 7 days, V.A.C.® Therapy was discontinued, and the graft showed 100% graft take (**Figure 2**).

Course of treatment/application of 3M™ V.A.C.® Therapy with 3M™ Dermatac™ Drape

At the wound care clinic, the dehiscenced wound was evaluated and measured 3.5 × 0.9 × 4.5cm. To manage the dehiscenced wound, V.A.C.® Therapy was initiated using a foam dressing and Dermatac Drape (**Figure 1B**), an innovative film composed of silicone and acrylic. Dressing changes occurred every 3 days. Following the removal of Dermatac Drape during dressing changes, the Global Pain Scale (GPS; score 0-10) was used to assess patient pain. Three days after the initiation of V.A.C.® Therapy, the wound was evaluated (**Figure 2A**). V.A.C.® Therapy using the Dermatac Drape was reapplied over the wound (**Figure 2B**).

Six days after the initiation of V.A.C.® Therapy, the dehiscenced wound measured 3.0 × 0.9 × 2.5cm (**Figure 3**). After 13 days of V.A.C.® Therapy, the wound measured 2.8 × 0.9 × 2.5cm (**Figure 4A**). At Day 17 of V.A.C.® Therapy, the wound measured 2.5 × 0.8 × 1.5cm (**Figure 4B**). After 28 days of V.A.C.® Therapy, the wound measured 2.5 × 1.0 × 1.4cm (**Figure 5**). GPS scores were recorded during each visit, and the patient noted a GPS score of 0 after each drape removal. No pain medication was necessary. V.A.C.® Therapy using the Dermatac Drape was discontinued after 32 days, and the patient was transitioned to an advanced wound dressing using 3M™ Promogran Prisma™ Matrix, and dressing changes occurred 3 times a week. After 14 days of Promogran Prisma Matrix use, the wound measured 1.0 × 0.5 × 1.0cm (**Figure 6A**). After 28 days (Day 59 of treatment) of Promogran Prisma Matrix use, the wound measured 0.5 × 0.1 × 1.0cm (**Figure 6B**).

Discharge and follow-up

By Day 66 of treatment and after 35 days of Promogran Prisma Matrix use, the patient was discharged from the clinic (**Figure 6C**). In this patient, application of Dermatac Drape was easy to handle, and a seal was maintained in each application. In our experience, the appearance of the periwound area was better with Dermatac Drape relative to conventional V.A.C.® Therapy drape. No complications were reported with use of Dermatac Drape.

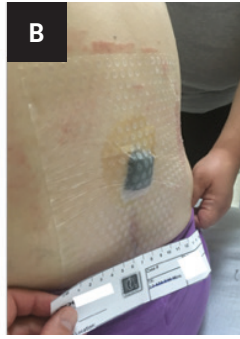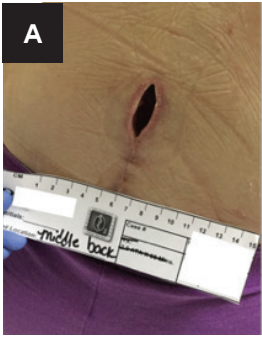


Figure 1. Patient at presentation with surgical wound dehiscence following lumbar fusion.
A. Initial evaluation of wound dehiscence.
B. Application of 3M™ Dermatac™ Drape.

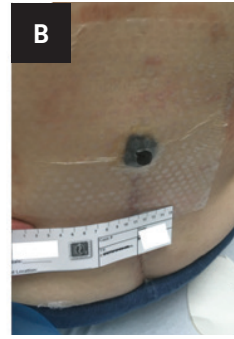
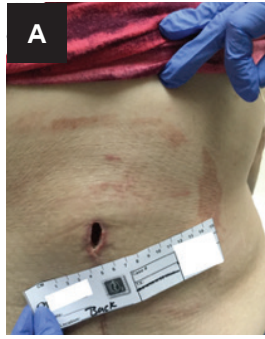

Figure 2. Patient 3 days post-initiation of 3M™ V.A.C.® Therapy.
A. Evaluation of wound dehiscence after 3 days of 3M™ V.A.C.® Therapy.
B. Application of 3M™ Dermatac™ Drape.

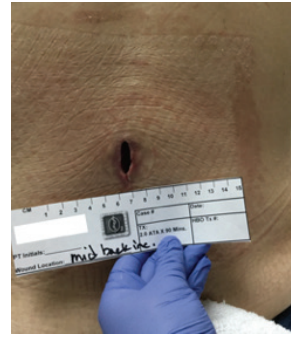

Figure 3. Dehiscenced wound after 6 days of 3M™ V.A.C.® Therapy.

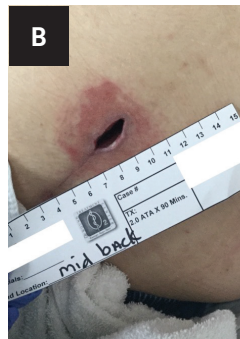
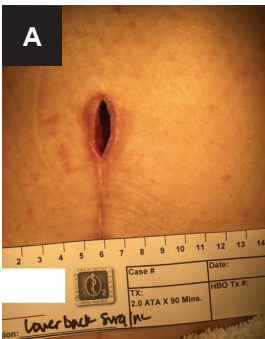
Figure 4. Progression of surgical wound dehiscence.
A. Dehiscenced wound after 13 days of 3M™ V.A.C.® Therapy.
B. Dehiscenced wound after 17 days of 3M™ V.A.C.® Therapy.

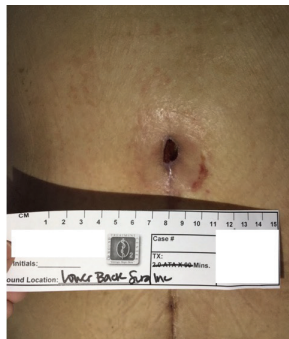

Figure 5. Dehiscenced wound after 28 days of 3M™ V.A.C.® Therapy.

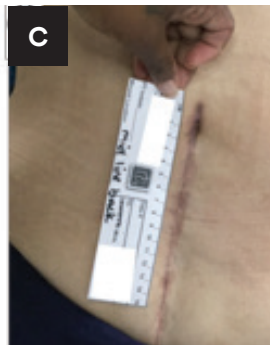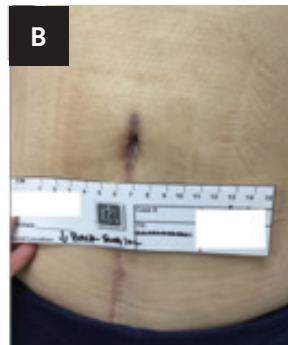
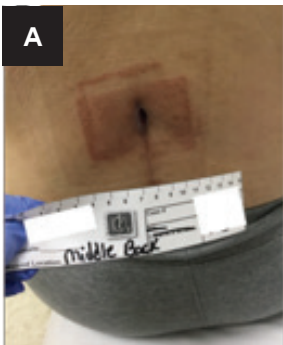


Figure 6. Progression of surgical wound dehiscence after transition to 3M™ Promogran Prisma™ Matrix.
A. Dehiscenced wound after 14 days of 3M™ Promogran Prisma™ Matrix.
B. Dehiscenced wound after 28 days of 3M™ Promogran Prisma™ Matrix.
C. Patient discharged from clinic on Day 66 after 35 days of 3M™ Promogran Prisma™ Matrix use.

Case study 7

Management of a dehisced abdominal wound post reconstruction using 3M™ V.A.C.® Therapy with 3M™ Dermatac™ Drape

Michael M. Desvigne, MD, FACS, CWS, FACCWS
Valley Wound Care Specialists, Glendale, AZ

Patient

The patient is a 77-year-old male with a medical history of obesity, diabetes mellitus, chronic obstructive pulmonary disease, hypertension, and a large recurrent ventral hernia with complete loss of abdominal domain. Patient underwent hernia repair with complex abdominal wall reconstruction with a porcine dermal matrix and staged closure with use of regenerative tissue matrices.

Diagnosis

The patient developed a non-healing surgical wound following repair of his large recurrent ventral hernia (**Figure 1**).

Course of treatment/application of 3M™ V.A.C.® Therapy with 3M™ Dermatac™ Drape

V.A.C.® Therapy was initiated at -125mmHg using a foam dressing and Dermatac Drape, an innovative film composed of silicone and acrylic (**Figure 2**). Dressing changes occurred every three days. After 10 days of therapy (**Figure 3**), there was an increase in granulation tissue formation, and the appearance of the periwound was notably improved without evidence of irritation, maceration, or compromise. After 6 weeks of V.A.C.® Therapy (**Figure 4**), there was 100% granulation tissue formation of the wound bed with continued improvement of the periwound as noted by decreased periwound edema, normalization of skin color, and resolution of the purple discoloration, which is indicative of soft tissue injury. A split-thickness skin graft (STSG) was then applied over the wound (**Figure 5**) and was bolstered using V.A.C.® Therapy with the Dermatac Drape (**Figure 6**).

Discharge and follow-up

At 1-week post-STSG (**Figure 7**), V.A.C.® Therapy was discontinued and the Dermatac Drape was removed without difficulty or patient discomfort. The STSG was adherent. The small areas along the periphery with epidermalysis were managed further with collagen/oxidized regenerated cellulose to help reduce the chronic inflammation.

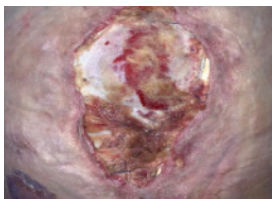


Figure 1. Presentation of dehisced abdominal wound.

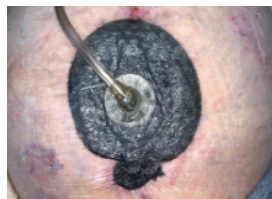

Figure 2. Application of 3M™ V.A.C.® Therapy with Dermatac Drape.

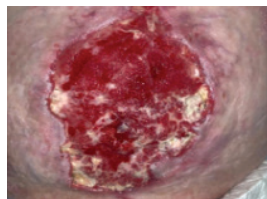


Figure 3. Wound after 10 days of 3M™ V.A.C.® Therapy.

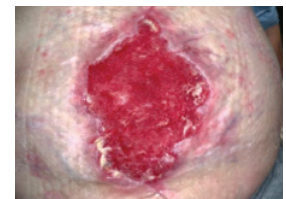

Figure 4. Wound after 6 weeks of 3M™ V.A.C.® Therapy.

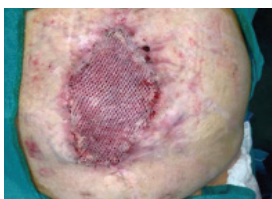


Figure 5. Application of STSG.

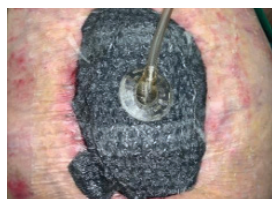

Figure 6. 3M™ V.A.C.® Therapy was used as a bolster over the STSG.

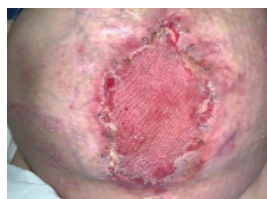


Figure 7. At 1-week post-STSG.

Case study 8

3M™ V.A.C.® Therapy and 3M™ Dermatac™ Drape used as a bolster over skin graft application to hand wound

Allen Gabriel, MD, FACS, Maci Plaffenberger, PA-C; Elizabeth Eldenburg, MPAS; Davi Mayer, CMA;
Jessica Nelson, LPN,
Rebecca Gold, BA, MSIII
Plastic Surgery, Vancouver, WA

Patient

A 71-year-old male presented with a hand wound measuring 5cm x 6cm x 0.1cm. Previous medical history included tobacco use, diabetes, coronary heart disease, peripheral vascular disease, and obesity. A Regenerative Template was applied over the wound followed by application of V.A.C.® Therapy as a bolster. After 7 days, V.A.C.® Therapy was discontinued.

Four weeks later, the patient returned for further care. The hand wound measured 5cm x 5cm x 0.1cm (**Figure 1**). A split-thickness skin graft procedure was performed (**Figure 2**). V.A.C.® Therapy with Dermatac Drape was used as a bolster. After 7 days, the wound was fully healed with 100% graft take and V.A.C.® Therapy was discontinued (**Figure 3**). During care, patient reported pain was recorded during dressing changes. The patient reported no pain during dressing change after the split-thickness skin graft dressing change (0/10, Visual Analog Scale).

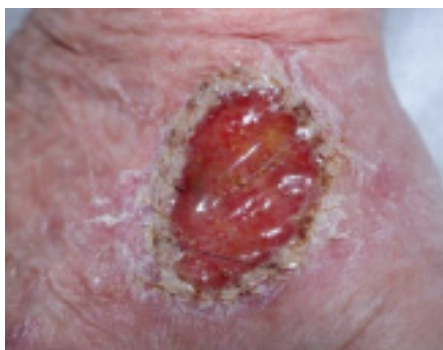

Figure 1. Hand wound four weeks after initial treatment.

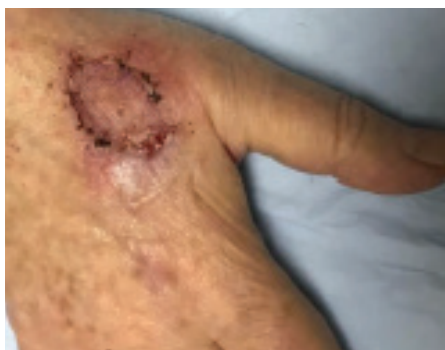

Figure 2. Application of split-thickness skin graft.

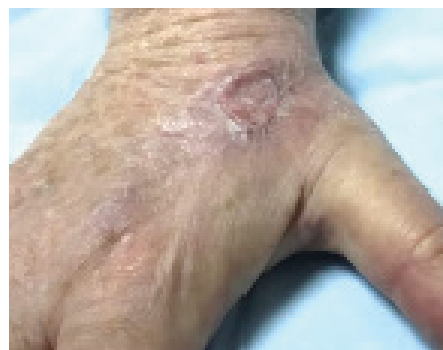

Figure 3. Wound fully healed 7 days after split-thickness skin graft.

Case study 9

3M™ V.A.C.® Therapy using 3M™ Dermatac Drape to manage an acute wound following incision and drainage of a back abscess

Marcus S. Speyrer, RN, CWS

The Wound Treatment Center, LLC, at Opelousas General Health System; Opelousas, LA, USA

Patient

A 24 year old male with a medical history of diabetes and obesity presented to wound care clinic for management of an acute wound (**Figure 1**).

Diagnosis

Two days prior, the patient underwent incision and drainage (I&D) of an abscess situated on the left upper back. A swab was taken from the skin defect and microbial assays were performed on the sample to detect any wound resident pathogens. The resultant clinical tests determined that the wound was positive for methicillin-resistant *Staphylococcus aureus* (MRSA). To address the infection, the patient was prescribed an oral regimen of clindamycin.

Course of treatment/application of 3M™ V.A.C.® Therapy with 3M™ Dermatac™ Drape

Four days post I&D, the wound was evaluated at the wound care clinic and measured $1.8 \times 6.2 \times 5.0\text{cm}^3$. Eight days post-I&D (**Figure 2**), V.A.C.® Therapy using a foam dressing and Dermatac Drape, an innovative film composed of silicone and acrylic, was initiated to manage the surgical wound. To protect the periwound area, hydrocolloid strips were placed in a window pane fashion. Dressing changes occurred every 3 days. Three days after the initiation of V.A.C.® Therapy using the Dermatac Drape, the wound measured $1.0 \times 6.0 \times 3.0\text{cm}$ (**Figure 3A**). V.A.C.® Therapy was continued (**Figure 3B**). After 11 days of V.A.C.® Therapy using the Dermatac Drape, the wound measured $0.8 \times 4.8 \times 1.1\text{cm}$ and V.A.C.® Therapy was discontinued (**Figure 4**). The Global Pain Scale (GPS; score 0-10) was used to assess patient pain following the removal of Dermatac Drape during dressing changes. GPS scores were recorded during each visit, and the patient noted a GPS score of 0 after each drape removal. No pain medication was necessary.

The wound contracted with wound edges being brought closer together; no wound complications were noted. The patient transitioned to other wound care modalities. Five days post V.A.C.® Therapy, the wound measured $0.6 \times 4 \times 0.8\text{cm}$ (**Figure 5A**).

Discharge and follow-up

Ten days post V.A.C.® Therapy, the patient was discharged from the clinic with a final wound measurement of $0.3 \times 3.0 \times 0.2\text{cm}$ (**Figure 5B**). In this patient, application of Dermatac Drape was effortless and it maintained a seal in all applications. In our experience, the faster application of Dermatac Drape allowed for reduced clinical time to initiate V.A.C.® Therapy relative to conventional drape. No complications were reported with use of Dermatac Drape.

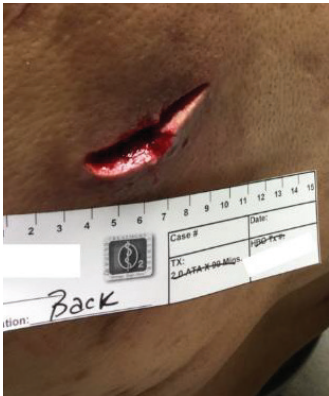

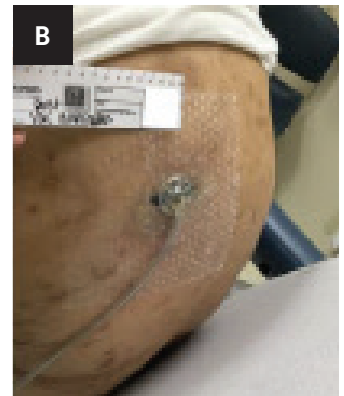
Figure 1. Patient with surgical wound two days following incision and drainage of a back abscess.

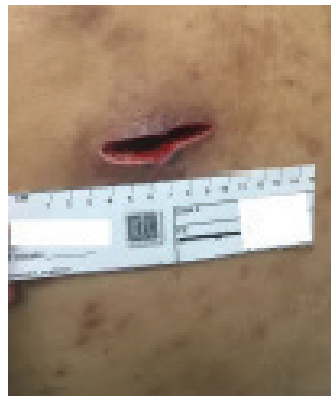

Figure 2. Surgical wound on the day 3M™ V.A.C.™ Therapy was initiated.

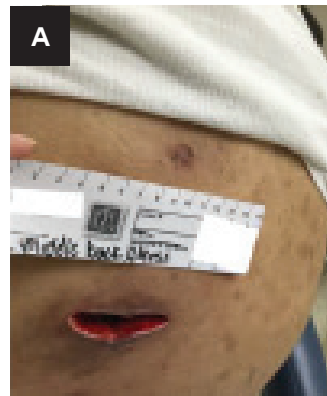

Figure 3. Surgical wound after 3 days of 3M™ V.A.C.™ Therapy with 3M™ Dermatac™ Drape.



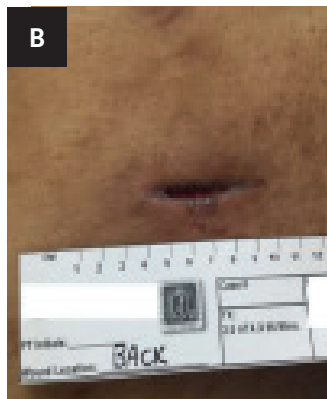
A. Wound measured $1.0 \times 6.0 \times 3.2$ cm after 3 days of therapy.
B. To protect the periwound area, hydrocolloid strips were placed in a window pane fashion, followed by application of 3M™ V.A.C.™ Therapy with 3M™ Dermatac™ Drape.

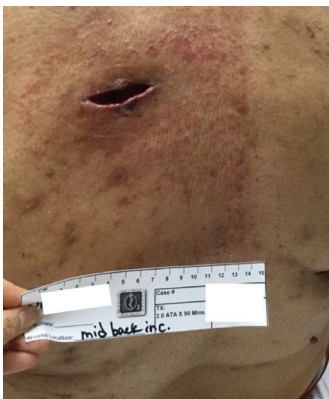

Figure 4. Surgical wound measuring $0.8 \times 4.8 \times 1.1$ cm after 3M™ V.A.C.™ Therapy with 3M™ Dermatac™ Drape was discontinued.

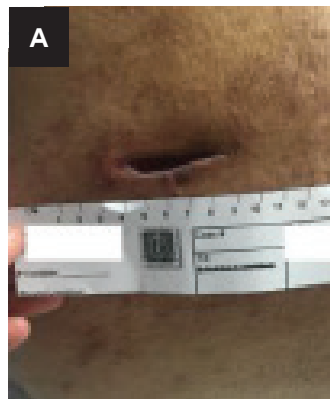





Figure 5. Wound healing progression after the termination of 3M™ V.A.C.™ Therapy.



A. Wound measured $0.6 \times 4 \times 0.8$ cm five days post therapy.
B. Patient discharged with a final wound measurement of $0.3 \times 3.0 \times 0.2$ cm

Ordering information

Product	SKU	Ordering information
 <p>3M™ Dermatac™ Drape</p>	DTAC10LDP	Case of 10
 <p>3M™ Dermatac™ Drape and V.A.C.® Granufoam™ Dressing Kit - Small - includes 1 drape</p>	DTGF10PKS DTGF05PKS	Case of 10 Case of 5
 <p>3M™ Dermatac™ Drape and V.A.C.® Granufoam™ Dressing Kit - Medium - includes 1 drape</p>	DTGF10PKM DTGF05PKM	Case of 10 Case of 5
 <p>3M™ Dermatac™ Drape and V.A.C.® Granufoam™ Dressing Kit - Large - includes 2 drapes</p>	DTGF10PKL DTGF05PKL	Case of 10 Case of 5

For more information contact your local representative.

Note: As with any case study, the results and outcomes should not be interpreted as a guarantee or warranty of similar results. Individual results may vary depending on the patient's circumstances and condition.

Note: Specific indications, contraindications, warnings, precautions and safety information exist for these products and therapies. Please consult a clinician and product instructions for use prior to application. Rx only.



3M Company
2510 Conway Ave
St. Paul, MN 55144 USA

Phone 1-800-275-4524 (NPWT products)
1-800-228-3957
Web 3M.com/medical

© 2021 3M. All rights reserved. 3M and the other marks shown are marks and/or registered marks.
Unauthorized use prohibited.
70-2013-1083-9 PRA-PM-US-02325 (08/21)