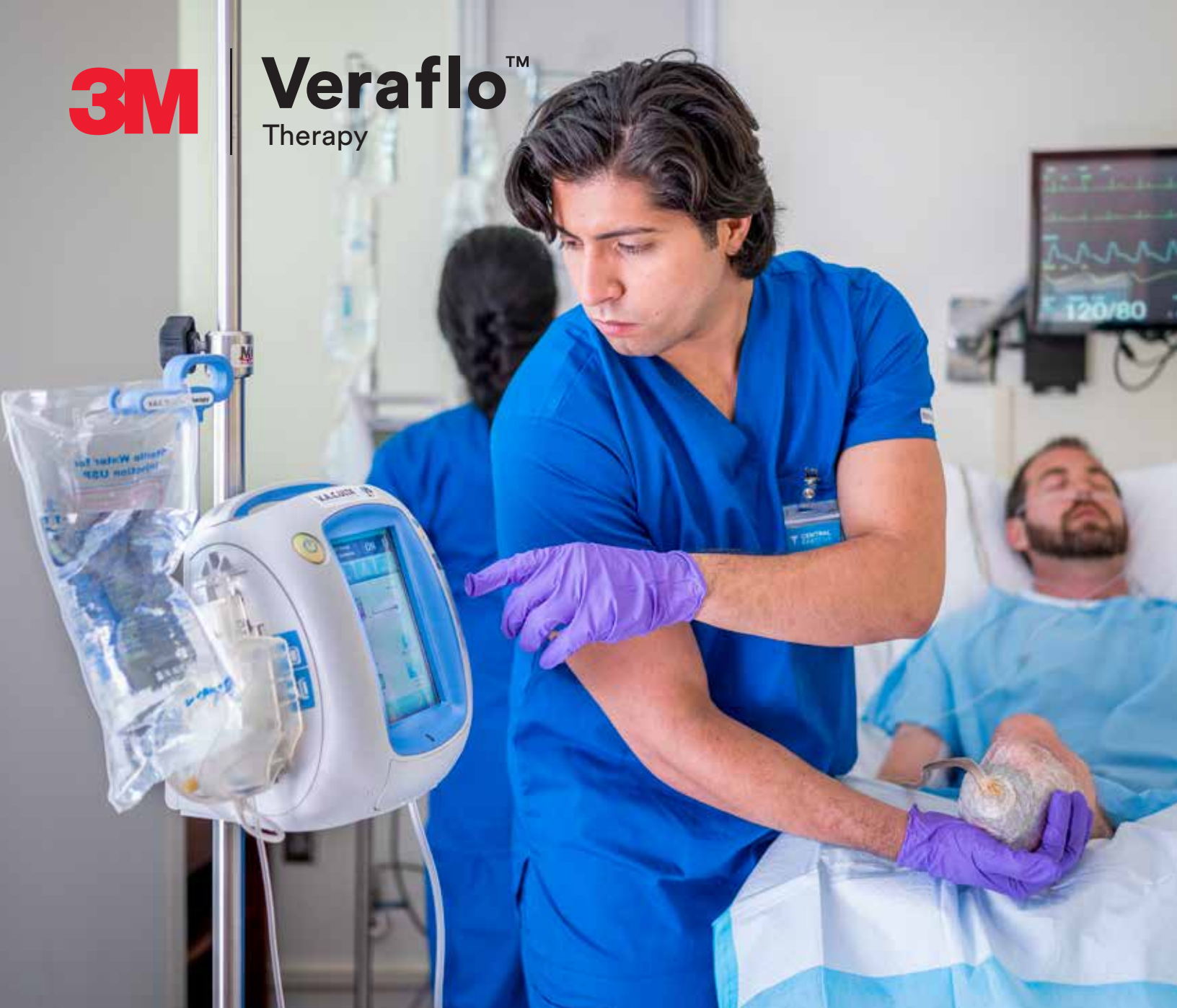



Veraflo™
Therapy



3M™ Veraflo™ Therapy

Collection of case studies

Introduction

The following case studies are the results of physicians' clinical experience. As with any case study, the results and outcomes should not be interpreted as a guarantee or warranty of similar results. Individual results may vary depending on the patient's circumstances and condition. All of the health care professionals featured were consultants of 3M.

Table of contents

Foot wounds

Case study 1: Diabetic foot abscess	4
Case study 2: Heel pressure injury	6
Case study 3: Chronic foot wound	7

Leg wounds

Case study 4: Venous leg ulcer	8-9
Case study 5: Management of left knee wound	10-11
Case study 6: Chronic leg ulcer	11
Case study 7: Left elbow wound	13

Sacral wounds

Case study 8: Pressure ulcer	14
------------------------------------	----

Torso wounds

Case study 9: Surgical dehiscence	15
Case study 10: Surgical abscess on upper back	16

Trauma wounds

Case study 11: Traumatic wound	17
Case study 12: Traumatic wound	18-19

Case study 1

Diabetic foot abscess



David Hardman, MBBS, FRACS, Canberra Hospital, Deakin, ACT

Patient

A 48-year-old male patient presented to the hospital with a left diabetic foot abscess (**Figure 1**). The patient was a former smoker with Type II diabetes mellitus, peripheral vascular disease, bilateral neuropathy, and hypertension. His medical history included osteomyelitis of the right calcaneus and left big toe and an osteotomy of the first metatarsal bone in the left foot. Treatment with intravenous cephazolin commenced upon initial evaluation.

The abscess was drained with pus discharge and dressed with non-adherent povidone-iodine and polyurethane foam dressings. On the following day, a sharp debridement and a washout were performed in the operating room (OR), followed by application of 3M™ V.A.C.® Therapy using 3M™ V.A.C.® Granufoam™ Dressing at -125 mmHg continuous negative pressure. After two days of treatment, the wound measured 10 cm x 3 cm x 1 cm (**Figure 2**).

Therapy was switched to 3M™ Veraflo™ Therapy using 3M™ V.A.C. Veraflo Cleanse Choice™ Dressing (**Figure 3 and 4**).

A nonadherent dressing was placed over the exposed bone at the base of the 4th metatarsal. The wound was instilled with 6 mL of a polyhexanide solution with 15-minute dwell time, followed by 3.5 hours of negative pressure at -125 mmHg. After 3 days of treatment, the swelling and redness had decreased, though slough was still present (**Figure 5**).

On Day 5 (**Figure 6**), treatment settings were changed to instill 8 mL of a polyhexanide solution with a 15-minute dwell time, followed by 2 hours of negative pressure at -125 mmHg. Continuous improvement was noted at each dressing change, which occurred every 2-3 days.

After a total of 10 days (**Figure 7**), the dressing was switched to V.A.C. Veraflo Dressing, resuming previous instillation settings, and dressings were changed every 2-3 days (**Figure 8**).

After 7 days (**Figure 9**), treatment switched to V.A.C.® Therapy with V.A.C.® Granufoam™ Dressing and the patient was discharged to a community health clinic.

At this time, the wound measured 9 cm x 2.5 cm x 0.5 cm. Both the patient and clinician were pleased that this treatment plan reduced the number of returns to the OR. Seventeen days after discharge, granulation tissue had significantly increased and the medial crease closed (**Figure 10**). V.A.C.® Therapy was discontinued to avoid hypergranulation, and treatment was changed to a daily 15-minute dressing soak with a polyhexanide solution, followed by application of medicinal honey and advanced wound dressings.

This regimen was continued for 17 days. The patient reported total wound closure 12 weeks later, with follow-up showing complete healing (**Figure 11**). The total treatment period using the negative pressure devices was 34 days. The supervising clinician noted that if he had not used V.A.C.® Therapy or Veraflo Therapy, he would have used povidone iodine-soaked gauze (every 8 hours), followed by wet-to-dry gauze dressings, which would have taken at least 6 months and potentially increased the risk of limb loss.

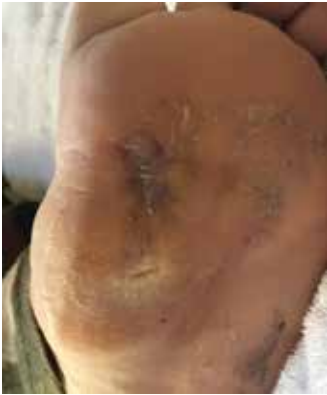

Figure 1. Diabetic foot abscess upon admission.

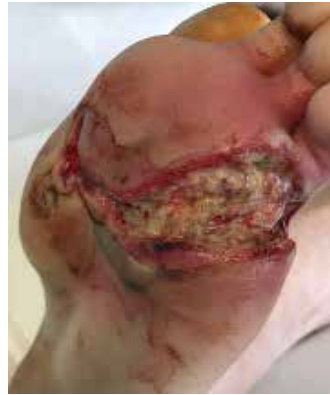

Figure 2. Wound after drainage, washout, sharp debridement and 2 days of 3M™ V.A.C.® Therapy.

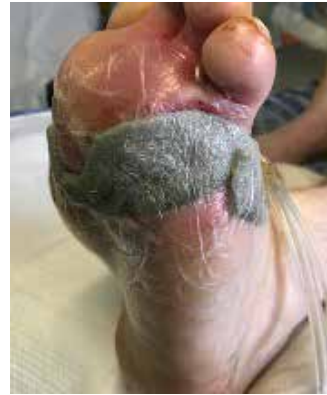

Figure 3. Application of 3M™ Veraflo™ Therapy with 3M™ V.A.C. Veraflo Cleanse Choice™ Dressing. Planter view.

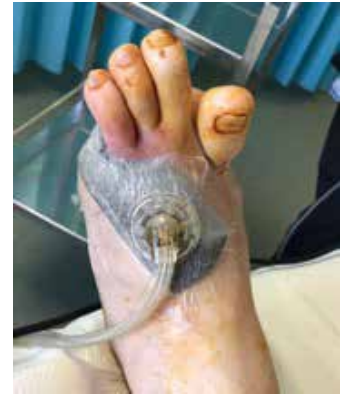

Figure 4. Application of 3M™ Veraflo™ Therapy with 3M™ V.A.C. Veraflo Cleanse Choice™ Dressing. Dorsal view.

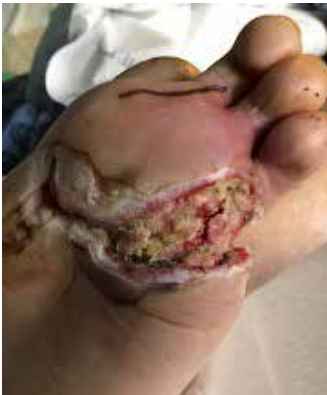

Figure 5. Wound after 3 days of treatment with 3M™ Veraflo™ Therapy using 3M™ V.A.C. Veraflo Cleanse Choice™ Dressing.

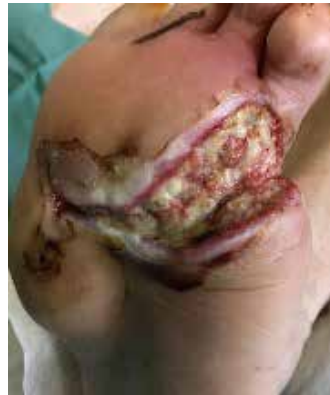

Figure 6. Wound after 5 days of treatment with 3M™ Veraflo™ Therapy using 3M™ V.A.C. Veraflo Cleanse Choice™ Dressing.

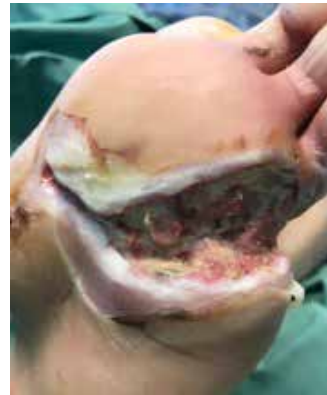

Figure 7. Wound after 10 days of treatment with 3M™ Veraflo™ Therapy using 3M™ V.A.C. Veraflo Cleanse Choice™ Dressing.

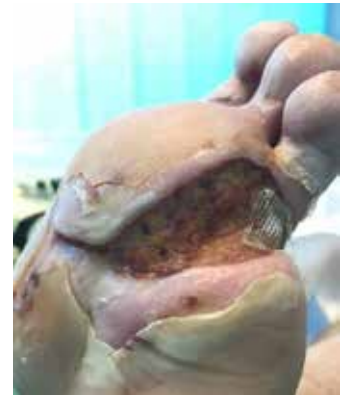

Figure 8. Wound 4 days (2 dressing changes) after switching treatment to 3M™ Veraflo™ Therapy using 3M™ V.A.C. Veraflo™ Dressing.

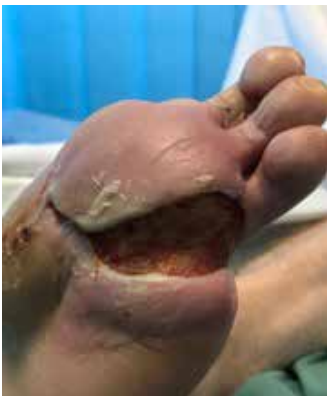

Figure 9. Wound 7 days after switching treatment to 3M™ Veraflo™ Therapy using 3M™ V.A.C. Veraflo™ Dressing.

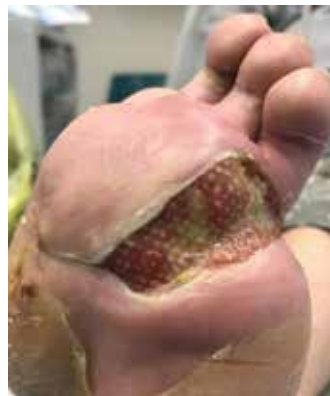

Figure 10. Wound 17 days after switching treatment to 3M™ V.A.C.® Therapy with 3M™ V.A.C.® Granufoam™ Dressing over an interface dressing to prevent hypergranulation.

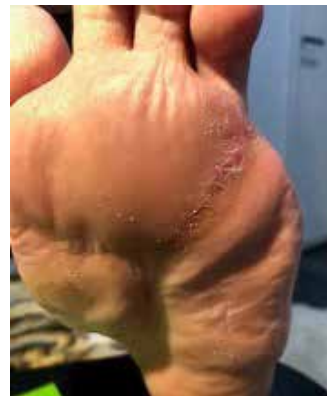

Figure 11. Closed wound 14 weeks after discontinuation of 3M™ V.A.C.® Therapy.

Case study 2

Heel pressure injury

Dressings	Drape
	

Mark Keating, Wound CNC, Camden & Campbelltown Hospital, Campbelltown, NSW

Patient

A 55-year-old male was transferred to a rehabilitation ward following a long hospital stay after fracturing his right distal tibia and fibula, requiring an open reduction and internal fixation. The patient's medical history included chronic schizophrenia, type II diabetes, hypertension, dyslipidemia, peripheral vascular disease, and chronic bilateral pitting oedema. Upon removal of the controlled ankle movement boot, an unstageable pressure injury was noticed on the right heel. A wound swab returned positive for methicillin-resistant *Staphylococcus aureus*, *Streptococcus agalactiae*, and *Pseudomonas*. Treatment consisted of antibiotics, medicinal honey, silver-embedded dressing, and application of enzymatic and sharp debridement. Following the removal of devitalized tissue, the injury was assessed as a stage IV pressure injury. Further examination revealed no osteomyelitis, and an ultrasound doppler confirmed adequate peripheral perfusion. However, the wound remained unresponsive to treatment, and the vascular team determined that surgical intervention would not be appropriate. The heel was off-loaded with a heel suspension boot, but this left the patient unable to resume rehabilitation. Due to multiple comorbidities, the patient was unsuited for surgical debridement. The decision was made to transition treatment to 3M™ Veraflo™ Therapy.

The wound measured 4.5 cm x 3.5 cm x 0.7 cm, with a slight malodour and 90% of the wound covered by devitalized tissue and slough (**Figure 1**). The goal of therapy was to remove slough and infectious materials. A 3M™ V.A.C. Veraflo Cleanse Choice™ Dressing was placed over the wound bed (**Figure 2**), and Veraflo Therapy was initiated by instilling 20 mL of a 0.1% polyhexanide/0.1% betaine solution with a 15-minute dwell time, followed by 4 hours of -125 mmHg negative pressure (**Figure 3**). Dressing changes occurred every 2 days. At the first dressing change, the slough had reduced in density and healthy granulation tissue was noted. Wound measurements were 4 cm x 3.3 cm x 0.6 cm (**Figure 4**). After a total of 4 days, V.A.C. Veraflo Cleanse Choice Dressing was discontinued and 3M™ V.A.C. Veraflo™ Dressing was used with Veraflo Therapy. The solution volume was decreased to 12 mL. The dwell time and negative pressure settings remained the same. On day 6, there was no visible slough on the wound bed, which was 100% covered with healthy granulation tissue (**Figure 5**). There was also no malodour or signs of infection. Wound measurements were 4 cm x 3 cm x 0.3 cm. Treatment was transitioned to 3M™ V.A.C.® Therapy with a 3M™ V.A.C.® Granufoam™ Dressing. The wound continued to show improvement with no return of slough after 3 days (**Figure 6**). The healthcare practitioner concluded that use of Veraflo Therapy and V.A.C.® Therapy successfully promoted healing of the previously unresponsive to treatment 5-month old pressure injury without the need for surgical intervention.

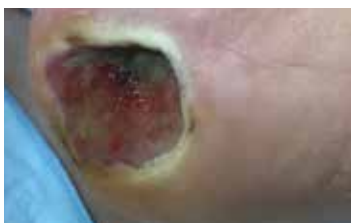

Figure 1. Wound at initial presentation.

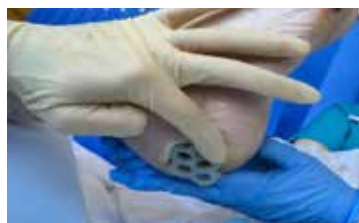

Figure 2. Placement of 3M™ V.A.C. Veraflo Cleanse Choice™ Dressing contact layer on the wound bed.

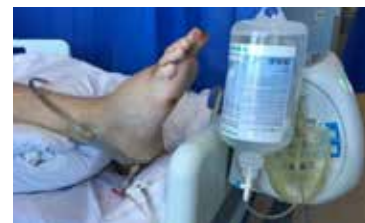

Figure 3. Initiation of 3M™ Veraflo™ Therapy.

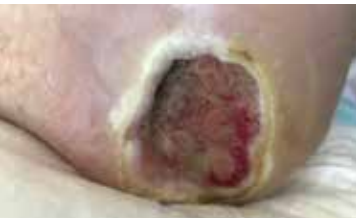

Figure 4. Wound after 2 days of 3M™ Veraflo™ Therapy with 3M™ V.A.C. Veraflo Cleanse Choice™ Dressing.

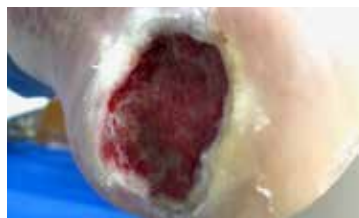

Figure 5. Wound after 2 days of 3M™ Veraflo™ Therapy with a 3M™ V.A.C. Veraflo™ Dressing.

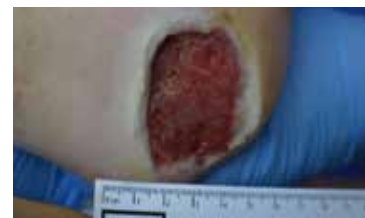

Figure 6. Wound after 3 days of 3M™ V.A.C.® Therapy with 3M™ V.A.C.® Granufoam™ Dressing.

Patient data and photos courtesy of Mark Keating, Wound CNC, Camden & Campbelltown Hospital, Campbelltown, NSW. Mark Keating was a consultant of 3M.

Case study 3

Chronic foot wound

John Stuchbury, Albury Base Hospital, Albury, NSW

Dressings	Drape
	

Patient

A male patient presented to the hospital with a chronic, non-healing foot wound resulting from a motor vehicle accident over 4 years prior. The wound measured 5 cm x 3.5 cm x 0.5 cm and was located on the top medial aspect of the foot with 95% slough covering the wound bed (**Figure 1**). The patient was a current smoker and had a medical history of Type 2 diabetes mellitus and hypercholesterolemia. He was also ineligible for surgical debridement due to his medication. Treatment was initiated using 3M™ Veraflo™ Therapy with 3M™ V.A.C. Veraflo Cleanse Choice™ Dressing. Normal saline (12 mL) was instilled with a dwell time of 10 minutes, followed by 3.5 hours of negative pressure at -125 mmHg. Dressings were changed every 3 days. At the first dressing change, the wound measured 4.5 cm x 3 cm x 0.5 cm (**Figure 2**), with a visible reduction in slough. At the third dressing change (**Figure 3**), treatment was switched to 3M™ V.A.C.® Therapy using 3M™ V.A.C.® Granufoam™ Dressing with continuous negative pressure at -125 mmHg for 30 days. At the 4-week follow-up, the patient had received a split-thickness skin graft at a different hospital and appeared to be healing without signs of complications (**Figure 4**).

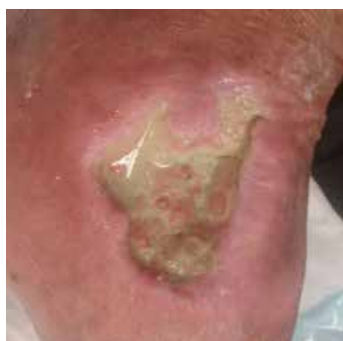

Figure 1. Wound at presentation.

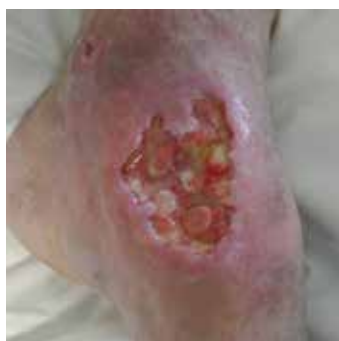

Figure 2. Wound at the first dressing change.

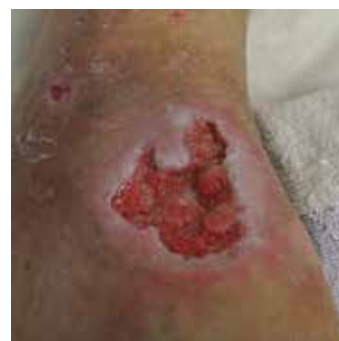

Figure 3. Wound at the third dressing change.

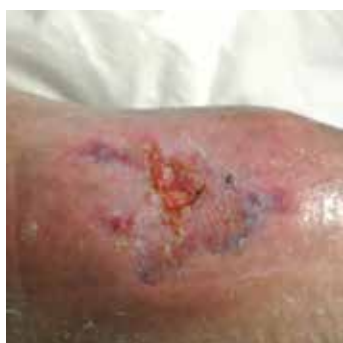

Figure 4. Wound at 4-week follow-up. Patient had received a split thickness skin graft at a different hospital.

Case study 4

Venous leg ulcer

Kersten Reider BSN, RN, CWOCN
Elizabeth McElroy, MSN, RN, CRNP, CWS, CWOCN-AP
Tower Health System, West Reading, PA



Patient

A 60-year-old female presented with a venous leg ulcer present for an unknown amount of time (10 cm x 16 cm x 1.5 cm) of the right distal lower extremity (**Figure 1**). Previous medical history included peripheral vascular disease, obesity, hypertension, thyroid disease, gastroesophageal reflux disease, respiratory failure, Influenza A infection, infected right leg wound with cellulitis, and septic shock. Systemic antibiotics were initiated upon presentation. Tubular compression was utilized to assist with edema management.

3M™ Veraflo™ Therapy using 3M™ V.A.C. Veraflo Cleanse Choice™ Dressing were used as wound required cleansing to help remove infectious materials. Ostomy barrier paste was utilized to assist with the creation of dressing seals. The wound was instilled with 34mL of quarter strength Dakin's solution with a 10-minute dwell time, followed by 1 hour of continuous negative pressure (-125mmHg). After 24 hours, the dressing was changed, and the instillation solution was switched to 28mL of normal saline (**Figure 2**). Dressing changes occurred every 2-3 days.

After 8 days of Veraflo Therapy with V.A.C. Veraflo Cleanse Choice Dressing, the wound had decreased in size (8.6cm x 13cm x 0.2cm) and exhibited healthy granulation tissue (**Figure 3**).

The patient was transitioned to Veraflo Therapy using 3M™ V.A.C. Veraflo Cleanse Choice™ Dressing. Therapy settings included instillation of 22mL of normal saline with a 10-minute dwell time, followed by 2 hours of continuous negative pressure at -125mmHg. After 2 days, healthy granulation tissue development was present (**Figure 4**).

Veraflo Therapy was discontinued and local wound care was initiated using 3M™ Promogran Prisma™ Wound Balancing Matrix, 3M™ Silvercel™ Non-Adherent Hydro-Alginate Antimicrobial Dressing with 3M™ Easylift™ Precision Film Technology, an absorptive cover dressing, and fourlayer compression dressings. Dressings were changed every 3 days. After 7 days, healthy granulation was observed in the wound bed (**Figure 5**).

Therapy was changed to Silvercel Non-Adherent Dressing, a second anti-shear absorbent cover dressing, and 4-layer compression dressings. After 4 days, the dressings were removed, and the wound was approved for application of an allograft (**Figure 6**). 3M™ Tielle™ Non Adhesive Hydropolymer Dressing was applied over the graft followed by 4-layer compression dressings.

After 2 days, the dressing was switched to 3M™ Adaptic™ Non-Adhering Dressing, Silvercel Non-Adherent Dressing, and 4-layer compression dressings. Dressing changes occurred twice a week. The patient was discharged to a skilled nursing facility for continued care. After 44 days of care, the wound demonstrated areas of reepithelialization (**Figure 7**).

The wound was fully closed 102 days post grafting and remained closed at a follow-up visit 56 days post closure (**Figure 8**).

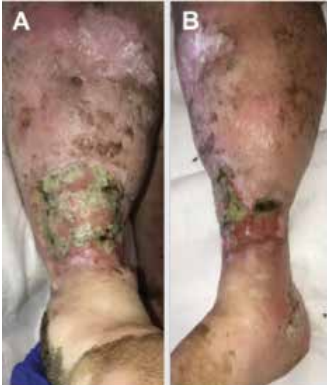

Figure 1. Venous leg ulcer at presentation. A. Anterior view; B. medial view.

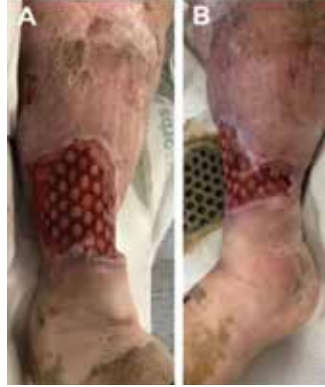

Figure 2. Wound after 24 hours of 3M[™] Veraflo[™] Therapy with Dakin's solution (quarter strength). A. Anterior view; B. medial view.

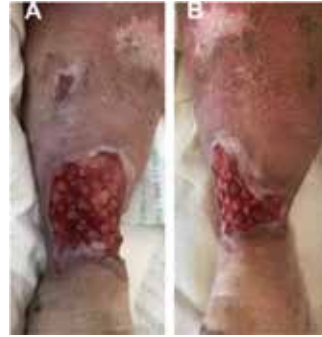

Figure 3. Wound after 8 days of 3M[™] Veraflo[™] Therapy with 3M[™] V.A.C. Veraflo Cleanse Choice[™] Dressing. A. Anterior view; B. medial view.

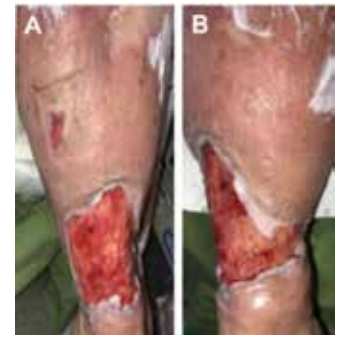

Figure 4. Wound after 2 days of with 3M[™] V.A.C. Veraflo[™] Dressing. A. Anterior view; B. medial view.

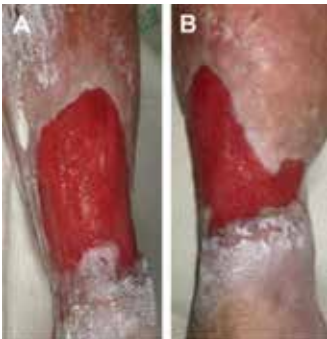

Figure 5. Wound after 7 days of advanced wound dressing and compression therapy. A. Anterior view; B. medial view.

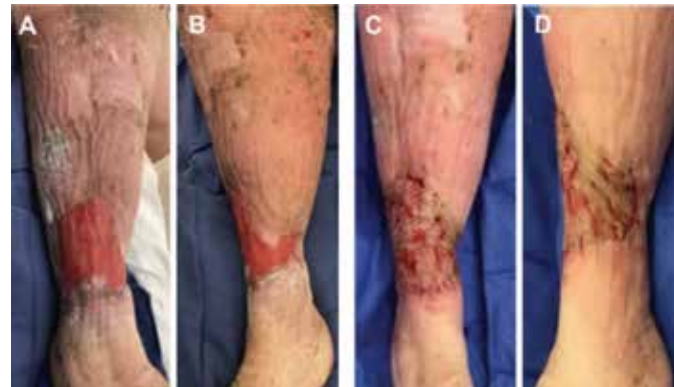

Figure 6. Allograft application. A. Wound prior to allograft procedure (anterior view); B. wound prior to allograft procedure (medial view); C. application of allograft (anterior view); D. application of allograft (medial view).

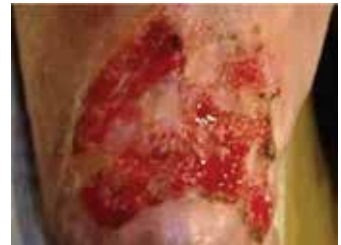

Figure 7. Reepithelialization observed in the wound 44 days after grafting.

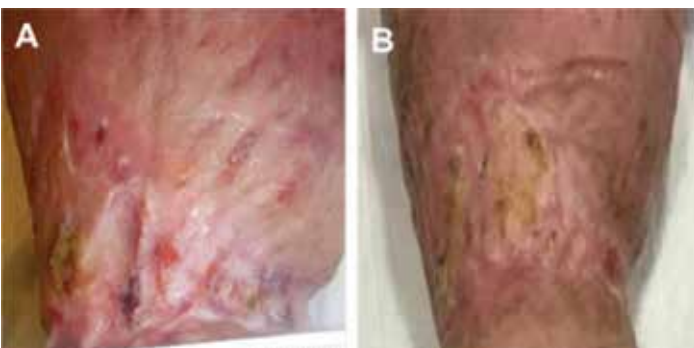


Figure 8. Wound fully closed. A. Wound fully closed after 102 days of advanced wound dressing care; B. wound remained closed at the follow-up visit (56 days post closure).

Case study 5

Management of left knee wound after total knee arthroplasty revision using 3M™ Veraflo™ Therapy with 3M™ Dermatac™ Drape

Dressings	Drape

Management of left knee wound after total knee arthroplasty revision using 3M™ Veraflo™ Therapy with 3M™ Dermatac™ Drape

Ralph J. Napolitano, Jr., DPM, CWSP, FACFAS; Mark E. Gittins, DO, FAOAO; Sarah Laub, PA-C OrthoNeuro, Columbus, OH

Patient

A 61-year-old female with a history of anxiety, depression, and early-stage multiple sclerosis presented with an open wound after undergoing left total knee arthroplasty for advanced osteoarthritis. Initially post-surgery, orthopedic healing progressed well with improved range of motion and no implant issues. However, at about 3 weeks post-surgery, increased fluid at the operative site was noted, and dermal healing regressed resulting in dehiscence at the distal edge of the incision, requiring revision.

Diagnosis

The knee joint cavity was closed, but a wound requiring advanced wound care remained (Figure 1). The wound was initially managed with 3M™ Silvercel™ Antimicrobial Alginate Dressing, but by day 7, nonviable tissue covered the wound surface (Figure 2).

Course of treatment/application of 3M™ Veraflo™ Therapy with 3M™ Dermatac™ Drape

Surgical debridement including pulsed lavage was performed, and Veraflo Therapy with Dermatac Drape was applied in the operating room (Figures 3, 4). Normal saline was instilled with an 8-minute dwell time, followed by 3.5 hours of -125 mmHg negative pressure. No fluid was instilled into the joint space. Dressings were changed every 2-3 days. After 3 days of Veraflo Therapy with 3M™ V.A.C. Veraflo™ Dressing, there was a visible reduction of nonviable tissue on the wound surface (Figure 5). Dressings were changed to 3M™ V.A.C. Veraflo Cleanse Choice™ Dressing and Veraflo Therapy continued for an additional 3 days.

Discharge and follow-up

By postoperative day 6, the wound depth had decreased, and the surface was covered with healthy granulation tissue (Figure 6). The patient was discharged home with 3M™ V.A.C.™ Therapy, which continued for an additional 2 weeks. This was followed by 2 weeks of applications of 3M™ Promogran Prisma™ Matrix. Upon follow-up at 5 weeks post-surgery, the wound was almost completely healed (Figure 7).

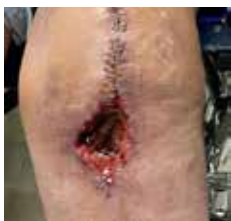

Figure 1. Initial appearance of the open wound, without communication with the joint space.

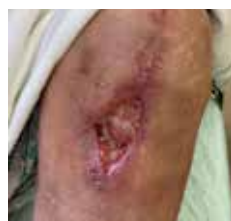

Figure 2. Presence of nonviable tissue after 7 days of Silvercel Dressing.

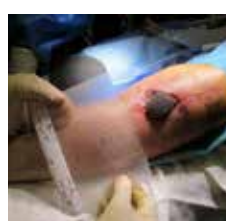

Figure 3. Placement of 3M™ V.A.C. Veraflo™ Dressing with 3M™ Dermatac™ Drape.

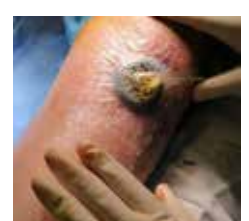

Figure 4. Creation of a seal and application of 3M™ Veraflo™ Therapy in the operating room.

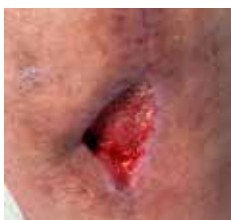

Figure 5. Wound appearance after 3 days of 3M™ Veraflo™ Therapy with the 3M™ V.A.C. Veraflo™ Dressing and 3M™ Dermatac™ Drape.

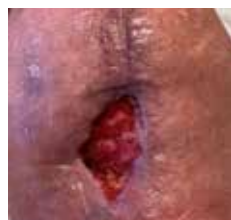

Figure 6. Wound appearance after 6 days of 3M™ Veraflo™ Therapy with 3M™ V.A.C. Veraflo Cleanse Choice™ Dressing and 3M™ Dermatac™ Drape.

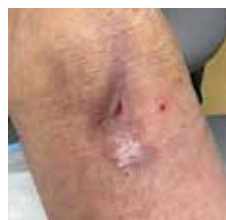

Figure 7. Wound appearance upon follow-up at week 5.

Photos and patient information courtesy of Ralph J. Napolitano, Jr., DPM, CWSP, FACFAS. Ralph Napolitano is a consultant of 3M.

Case study 6

Chronic leg ulcers

Cara Bowen, Wound CNC, Liverpool Hospital

Dressings	Drape
	

Patient

A 72-year-old female presented to the hospital with bilateral, chronic, non-healing leg ulcers with a duration of 6 years. The patient's medical history included controlled type II diabetes, vascular dementia, a chronic pilonidal sinus, and multiple pulmonary embolisms. The patient had previously undergone treatment for breast cancer, removal of basal cell carcinomas and squamous cell carcinomas of the face, neck, and lower limbs, and bilateral total knee replacements.

Both leg wounds were covered with 3M™ V.A.C.® Granufoam™ Dressing and treated with 3M™ V.A.C.® Therapy for 1 week, after which 3M™ Veraflo™ Therapy with 3M™ V.A.C. Veraflo Cleanse Choice™ Dressing was first initiated on the 2 wounds on the left leg. A polyhexanide biguanide solution was instilled into the wound with a dwell time of 10 minutes, followed by 3.5 hours of -125 mmHg continuous negative pressure. Dressing changes were performed every 2-3 days. At the first dressing change, decreased slough and improved granulation coverage were observed in the left leg (**Figure 1 and 2**), Treatment continued on the left leg wounds for 41 days (**Figures 3-8**) until split thickness skin grafts (STSG) were applied to close the wounds. No complications were observed at 1-week post STSG application (**Figures 9 and 10**).

Successful healing progression of the left leg prompted the decision to apply identical treatment to the right leg (**Figures 11 and 12**), using same Veraflo Therapy settings and with dressing changes every 2-3 days. A reduction of devitalized tissue and increased granulation were observed at each dressing change over 39 days (**Figures 13-17**). The wounds were closed using STSGs, with no signs of complications at 1-week post STSG application (**Figure 18**).

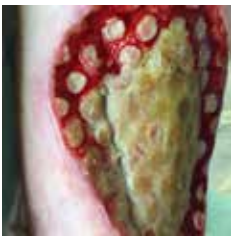

Figure 1. Anterior left leg wound after 2 days of 3M™ Veraflo™ Therapy with 3M™ V.A.C. Veraflo Cleanse Choice™ Dressing.

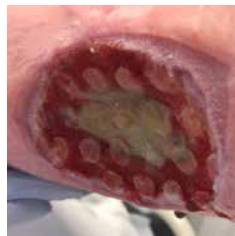

Figure 2. Posterior left leg wound after 2 days of 3M™ Veraflo™ Therapy with 3M™ V.A.C. Veraflo Cleanse Choice™ Dressing.

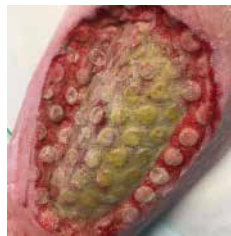

Figure 3. Anterior left leg wound after 6 days of 3M™ Veraflo™ Therapy with 3M™ V.A.C. Veraflo Cleanse Choice™ Dressing.

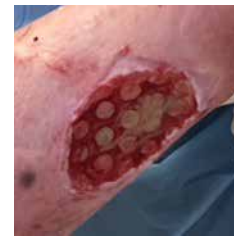

Figure 4. Posterior left leg wound after 6 days of 3M™ Veraflo™ Therapy with 3M™ V.A.C. Veraflo Cleanse Choice™ Dressing.

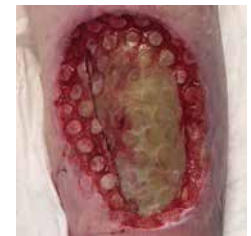

Figure 5. Anterior left leg wound after 9 days of 3M™ Veraflo™ Therapy with 3M™ V.A.C. Veraflo Cleanse Choice™ Dressing.

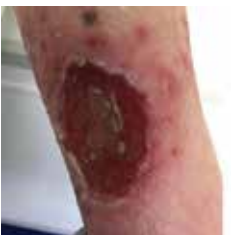

Figure 6. Posterior left leg wound after 9 days of 3M™ Veraflo™ Therapy with 3M™ V.A.C. Veraflo Cleanse Choice™ Dressing.

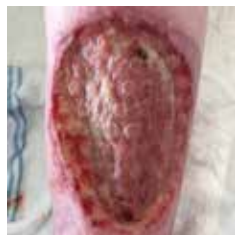

Figure 7. Anterior left leg wound after 16 days of 3M™ Veraflo™ Therapy with 3M™ V.A.C. Veraflo Cleanse Choice™ Dressing.

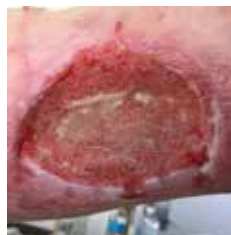

Figure 8. Posterior left leg wound after 16 days of 3M™ Veraflo™ Therapy with 3M™ V.A.C. Veraflo Cleanse Choice™ Dressing.

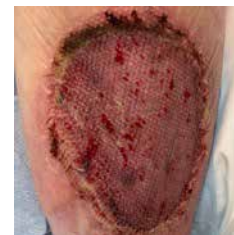

Figure 9. Anterior left leg wound 1 week after closure with STSG.

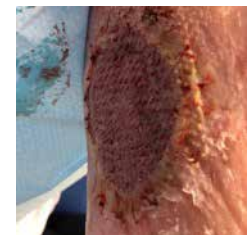

Figure 10. Posterior left leg wound 1 week after closure with STSG.

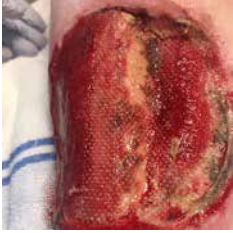

Figure 11. Anterior right leg wound after 1 week of 3M™ V.A.C.® Therapy with 3M™ V.A.C.® Granufoam™ Dressing.

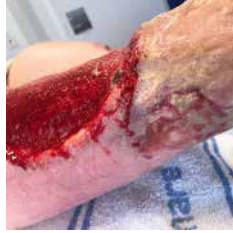

Figure 12. Lateral view of right leg after 1 week of 3M™ V.A.C.® Therapy with 3M™ V.A.C.® Granufoam™ Dressing.

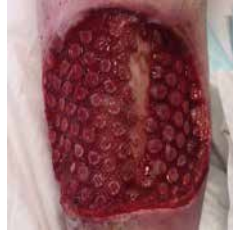

Figure 13. Anterior right leg wound after 4 days of 3M™ Veraflo™ Therapy with 3M™ V.A.C. Veraflo Cleanse Choice™ Dressing.

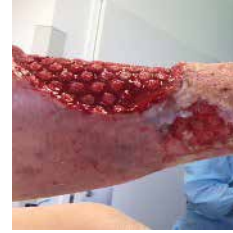

Figure 14. Lateral view of right leg wounds after 4 days of 3M™ Veraflo™ Therapy with 3M™ V.A.C. Veraflo Cleanse Choice™ Dressing.

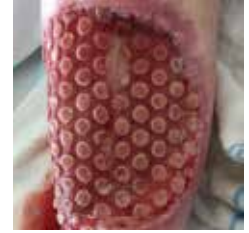

Figure 15. Anterior right leg wound after 7 days of 3M™ Veraflo™ Therapy with 3M™ V.A.C. Veraflo Cleanse Choice™ Dressing.

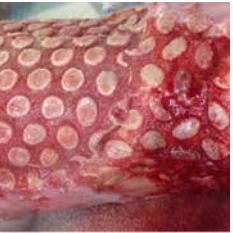

Figure 16. Lateral view of right leg wounds after 7 days of 3M™ Veraflo™ Therapy with 3M™ V.A.C. Veraflo Cleanse Choice™ Dressing.

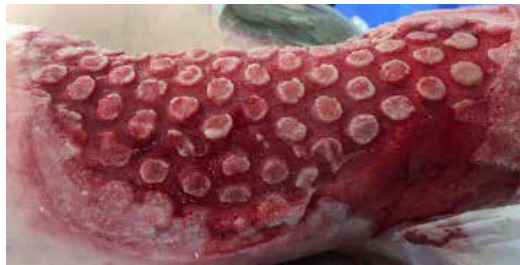

Figure 17. Lateral view of right leg wounds after 10 days of 3M™ Veraflo™ Therapy with 3M™ V.A.C. Veraflo Cleanse Choice™ Dressing.

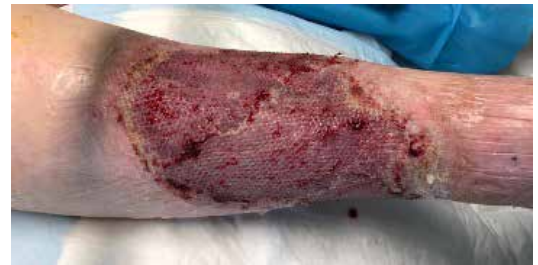

Figure 18. Anterior view of right leg wounds 1 week after closure with STSG.

Case study 7

Left elbow wound



Angela Hatfield, Orthopaedic Surgeon, Wagga Wagga Hospital

Patient

A 73-year-old female presented to the hospital with a chronic wound on the left elbow of 6 weeks duration. Previously, the patient received antibiotics after the wound showed signs of inflammation and oozing. An emergency surgery was performed to remove the infected bursa, and the patient reacted negatively to anesthetics. The wound was sutured, and the patient was discharged with advanced wound dressings and antibiotics. Upon returning 1 week later for suture removal, the wound exhibited symptoms of inflammation and dehiscence. The wound was surrounded by fragile skin and tested positive for *P. aeruginosa* infection. Surgical debridement was not possible for the patient due to a previous adverse reaction to anesthesia.

Upon presentation to the hospital, the wound measured 4 cm x 3 cm with 75% slough covering the wound bed (Figure 1). Treatment was initiated with 3M™ Veraflo™ Therapy using 3M™ V.A.C. Veraflo Cleanse Choice™ Dressing. A 0.9% saline solution was instilled with a 10-minute dwell time, followed by 3.5 hours of -125 mmHg negative pressure. At each dressing change, which was performed every 2-3 days, a decrease of slough and increase in granulation tissue were noted (Figure 2 and 3). After 8 days, the wound area had reduced to 3 cm x 1.5 cm, slough was eliminated, and the wound bed was 100% covered with healthy granulation tissue (Figure 4). The wound was closed, and the 3M™ Prevena™ Incision Management System was applied over the incision. The patient was then discharged home. After 7 days, the 3M™ Prevena™ Incision Dressing was removed, and advanced wound dressings were used to assist with final healing. The clinician was pleased with the outcome: the wound showed no sign of infection, and the patient was able to be discharged sooner than anticipated.

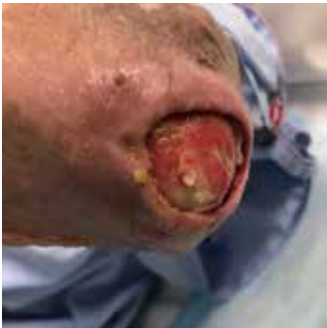

Figure 1. Wound at presentation.

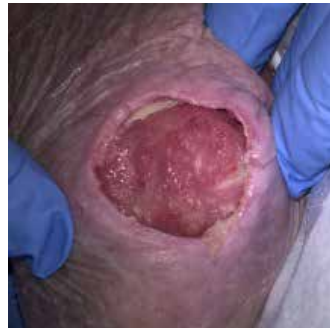

Figure 2. Wound after 2 days of treatment with 3M™ Veraflo™ Therapy with 3M™ V.A.C. Veraflo Cleanse Choice™ Dressing.

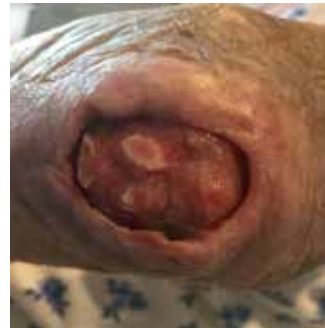

Figure 3. Wound after 5 days of treatment with 3M™ Veraflo™ Therapy with 3M™ V.A.C. Veraflo Cleanse Choice™ Dressing.

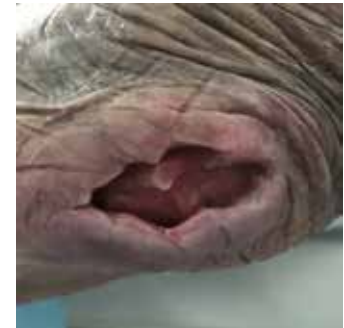



Figure 4. Wound after 8 days of treatment with 3M™ Veraflo™ Therapy with 3M™ V.A.C. Veraflo Cleanse Choice™ Dressing.

Case study 8

Pressure ulcer

Kimberly D. Hall, DNP, RN, GCNS-BC, CWCN-AP, COCN
Jessica Patterson, BSN, RN, CWOCN
Carilion Clinic, Roanoke, VA

Dressings	Drape
	

Patient

A 64-year-old male presented with a stage 4 pressure ulcer of the sacrum present for more than 4 years. Patient comorbidities included former tobacco use, poor nutritional status, hypertension, chronic paraplegia (present for more than 15 years), leukocytosis, multiple previous pressure ulcers, and osteomyelitis of the sacrum.

The wound had been previously treated with negative pressure wound therapy (NPWT), offloading, silver dressings, air mattress use, hydrofiber dressings, alginate dressings, and wound debridement. Bedside sharp debridement was performed but limited by inability to achieve adequate hemostasis (**Figure 1**). NPWT with instillation and dwell time (3M™ Veraflo™ Therapy) using a reticulated open cell foam (with large through holes (3M™ V.A.C. Veraflo Cleanse Choice™ Dressing) was initiated. Saline (22mL) was instilled into the wound followed by a 1 minute soak time and 30 minutes of negative pressure at -150mmHg.

Due to the difficult wound location, ostomy paste was used to help ensure a complete seal around the wound. At the first dressing change (3 days post therapy initiation), the wound showed improvement (**Figure 2**). After 7 days of Veraflo Therapy with V.A.C. Veraflo Cleanse Choice Dressing, the wound underwent conservative sharp debridement at the bedside to remove the tip of the coccyx and non-viable slough/adipose tissue (**Figure 3**). Two days post debridement, therapy was removed due to soiling and the patient underwent colostomy surgery. Three days post surgery, Veraflo Therapy using the V.A.C. Veraflo Cleanse Choice Dressing was re-started.

A silver alginate dressing was placed over the left buttock partial thickness area. After 5 days of

3M™ Veraflo™ Therapy (Figure 4), therapy was switched to NPWT 3M™ V.A.C.® Therapy using continuous negative pressure at -125mmHg for 9 days (**Figure 5**). After 9 days of NPWT, the patient was discharged to a skilled nursing facility.

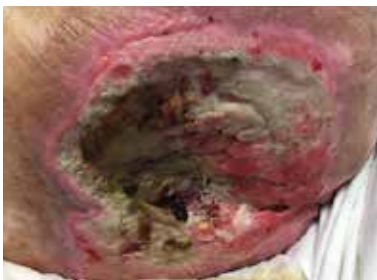

Figure 1. Wounds following bedside sharp debridement.

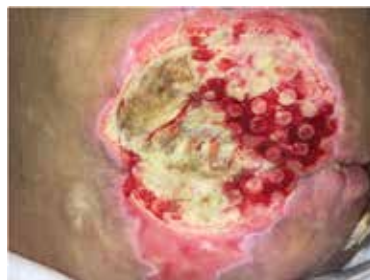

Figure 2. Wound after first 3M™ V.A.C. Veraflo Cleanse Choice™ Dressing change.

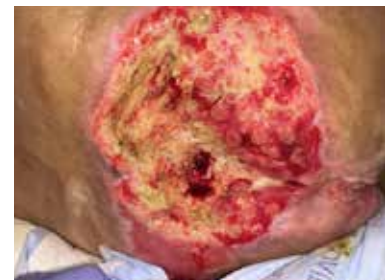

Figure 3. Wound after second surgical debridement.

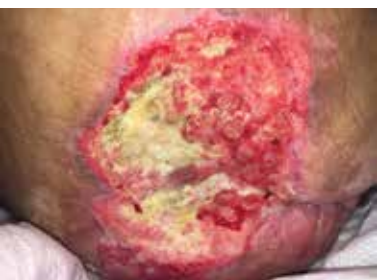

Figure 4. Wound after a total of 15 non-continuous days of NPWTi-d Veraflo Therapy.

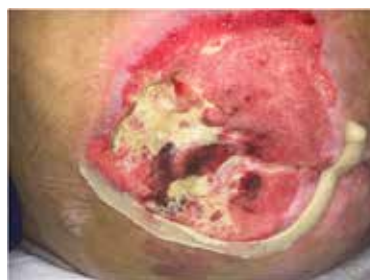



Figure 5. Wound following 9 days of NPWT.

Patient data and photos courtesy of Kimberly D. Hall, DNP, RN, GCNS-BC, CWCN-AP, COCN and Jessica Patterson, BSN, RN, CWOCN. Kimberly Hall and Jessica Patterson were consultants of 3M.

Case study 9

Surgical dehiscence

Kimberly D. Hall, DNP, RN, GCNS-BC, COCN
 Jessica Patterson, BSN, RN, CWOCN
 Carilion Clinic, Roanoke, VA

Dressings	Drape
	

Patient

A 68-year-old female presented with wound dehiscence present for 45 days and wound infection following cardiothoracic surgery (**Figure 1**). Patient comorbidities included tobacco use, diabetes mellitus, coronary heart disease, poor nutritional status, mitral valve replacement, recurrent mitral valve endocarditis, congestive heart failure, dyslipidemia, atrial fibrillation, valvular heart disease, hypothyroidism, and acute renal failure.

The wound had been previously treated with surgical debridement, saline wet-to-dry gauze, and Dakin's solution soaked gauzes. In addition, the patient received multiple antibiotics over the course of her prolonged hospitalization for multiple medical conditions that also provided coverage for the wound infection including cefazolin, gentamicin, anidulafungin, nafcillin, rifampin, ceftaroline fosamil, ertapenem, oxacillin, metronidazole, and vancomycin. Negative pressure wound therapy (NPWT) with instillation and dwell time (NPWTi-d, 3M™ Veraflo™ Therapy with 3M™ V.A.C. Veraflo™ Dressing) was initiated instilling 20mL saline with a soak time of 5 minutes followed by 1 hour of negative pressure at -125mmHg. Sharp debridement was performed at the bedside following the first dressing change (3 days post therapy initiation) (**Figure 2**). After the third dressing change, the wound underwent a second bedside sharp debridement (**Figure 3**).

Following debridement, the NPWTi-d dressing was switched to a reticulated open cell foam (ROCF) with large through holes (3M™ V.A.C. Veraflo Cleanse Choice™ Dressing) (**Figure 4**). Saline (50mL) was instilled into the wound with a 5 minute soak followed by 1 hour of continuous negative pressure at -125mmHg. Wound improvements were observed by the second ROCF-CC dressing change (**Figure 5**). After the third ROCF-CC dressing change, the wound was clean and showed good granulation tissue development (**Figure 6**). Therapy was switched from the ROCF-CC to a ROCF dressing without through holes (3M™ V.A.C. Veraflo™ Dressing). Saline (40mL) was instilled into the wound followed by a 5 minute soak time and continuous negative pressure at -125mmHg for 1 hour. After 7 days of NPWTi-d therapy with the ROCF-VF dressing (**Figure 7**), therapy was switched to NPWT (3M™ V.A.C.® Therapy) with continuous negative pressure at -125mmHg. Three days after starting NPWT, therapy was removed and the patient was discharged to a skilled nursing facility (**Figure 8**).

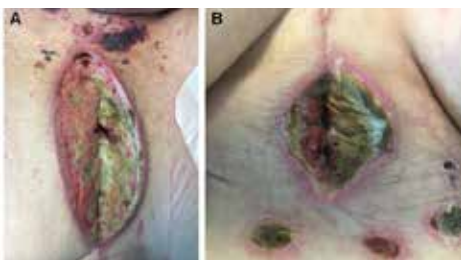

Figure 1. Wounds at presentation. Sternal (A) and midline (B) wounds are shown.

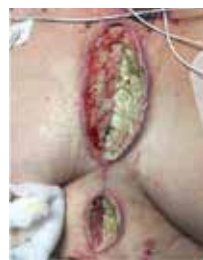

Figure 2. Wound after surgical debridement.

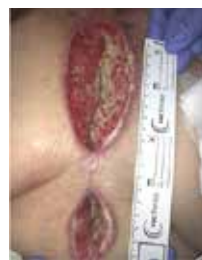

Figure 3. Wound at first dressing change and after second surgical

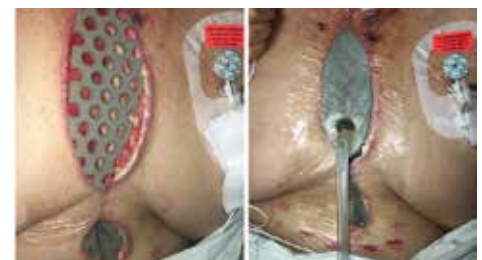

Figure 4. Application of dressing.

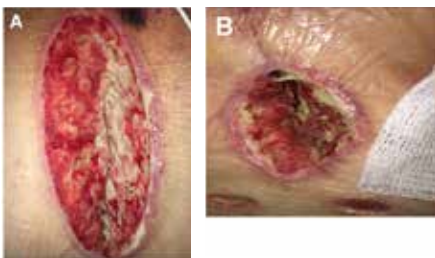


Figure 5. Wounds at presentation. Sternal (A) and midline (B) wounds are shown.

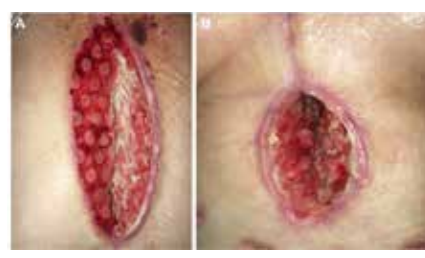


Figure 6. Wound following third ROCF-CC dressing

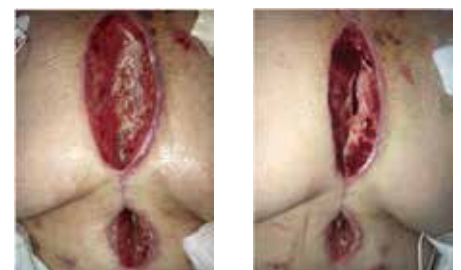

Figure 7. Wound following 7 days of NPWTi-d using the ROCF-VF dressing.

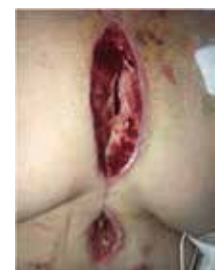

Figure 8. Wound following 3 days of NPWT.

Patient data and photos courtesy of Kimberly D. Hall, DNP, RN, GCNS-BC, CWCN-AP, COCN and Jessica Patterson, BSN, RN, CWOCN. Kimberly Hall and Jessica Patterson were consultants of 3M.

Case study 10

Surgical abscess on upper back

Dressings	Drape
	

Mr. Ibby Younis; Royal Free Hospital & University College Hospital, London, England, UK

Patient

A 92-year-old female with a herpes zoster infection presented for care with a multi-pathogen abscess on her upper back (**Figure 1**). Previous medical history included high blood pressure. Broad-spectrum oral and intravenous antibiotics were initiated.

3M™ Veraflo™ Therapy using 3M™ V.A.C. Veraflo Cleanse Choice™ Dressing was initiated following incision and drainage. Normal saline was instilled into the wound with a 10-minute dwell time followed by 2 hours of continuous negative pressure at -125mmHg. After 3 days of Veraflo Therapy, the wound showed an improved wound bed (**Figure 2**).

Thick wound exudate and infectious materials were still present in the wound bed and V.A.C. Veraflo Cleanse Choice Dressing was reapplied and Veraflo initiated. After 3 days of Veraflo Therapy with V.A.C. Veraflo Cleanse Choice Dressing the wound bed was improved and thick exudate reduced (**Figure 3**).

Veraflo Therapy with the V.A.C. Veraflo Cleanse Choice Dressing was used for another 3 days (**Figure 4**) to cleanse the wound further and help prepare it for surgical closure.

Surgical closure was performed and 3M™ Prevena™ Incision Management System with 3M™ Prevena™ Customizable Dressing was applied over the incision for 7 days (**Figure 5**). Hydrocolloid dressings were applied over the periwound skin for protection.

Prevena Incision Management System with Prevena Customizable Dressing was re-applied for an additional 7 days. The incision remained closed 14 days after surgery (**Figure 6**).

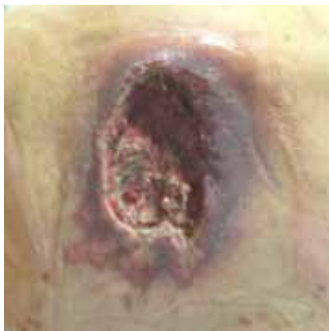

Figure 1. Wound at presentation following incision and drainage by a general surgeon.

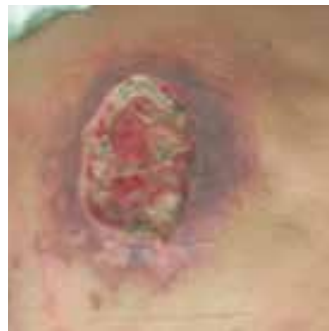

Figure 2. Wound after 3 days of 3M™ Veraflo™ Therapy with 3M™ V.A.C. Veraflo Cleanse Choice™ Dressing.

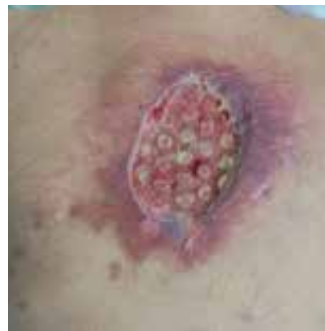

Figure 3. Wound after 6 days of treatment with 3M™ Veraflo™ Therapy with 3M™ V.A.C. Veraflo Cleanse Choice™ Dressing.

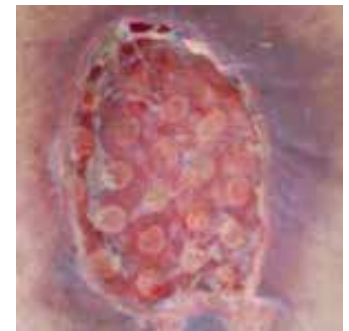


Figure 4. Wound after 9 days of 3M™ Veraflo™ Therapy.

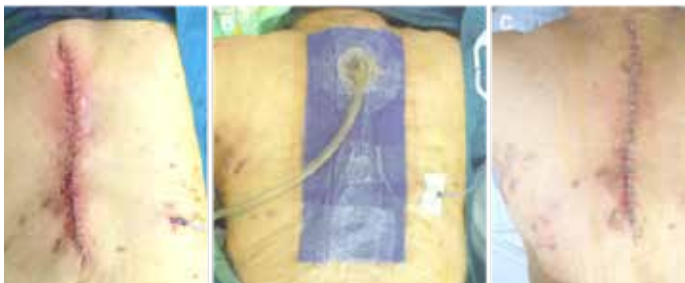

Figure 5. Surgical closure of the wound. A. Surgical closure of the wound; B. Application of 3M™ Prevena™ Incision Management System.

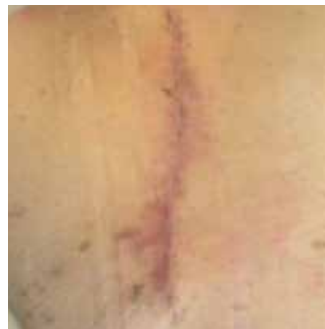

Figure 6. Incision 14 days after surgery.

Patient data and photos courtesy of Mr. Younis, Royal Free Hospital & University College Hospital, London, England, UK. Mr. Younis is a consultant of 3M.

Case study 11

Traumatic wound

Luis Fernandez, MD, FACS, FASAS, FCCP, FCCM, FICS,
University of Texas Health Science Center, Tyler, TX



Patient

A 33-year-old male presented to the hospital with an infection of his above-the-knee (AKA) stump following a fall (**Figure 1**). Previous medical history included tobacco use, anemia, and history of methicillin-resistant *Staphylococcus aureus* infection.

Conservative sharp debridement was performed at the bedside, and oral antibiotics were initiated. As the wound required further cleansing, 3M™ Veraflo™ Therapy using 3M™ V.A.C. Veraflo Cleanse Choice™ Dressing was started. Hypochlorous solution (80-100 mL) was instilled with a 10-minute dwell time, followed by 2 hours of negative pressure at -125 mmHg. Dressing changes occurred every 3 days. After the first dressing change, granulation tissue development was observed (**Figure 2**).

The wound showed further granulation tissue development and reduction in slough after 6 and 9 days of V.A.C. Veraflo Cleanse Choice Dressing use (**Figures 3 and 4**).

After 9 days, 3M™ Veraflo™ Therapy was discontinued, and 3M™ V.A.C.® Therapy initiated. The wound bed showed increased granulation tissue after 1 day of V.A.C.® Therapy usage (**Figure 5**). The patient was discharged to a long-term acute care facility 12 days after admission to the hospital.

Dressings	Drape
	

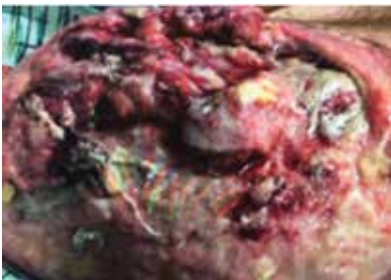


Figure 1. Wound at presentation.

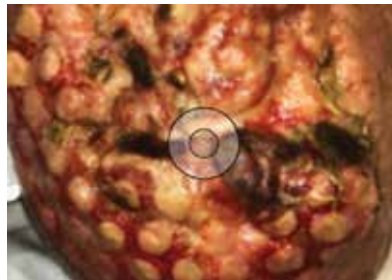

Figure 2. Wound after 3 days of 3M™ Veraflo™ Therapy with 3M™ V.A.C. Veraflo Cleanse Choice™ Dressing use.



Figure 3. Wound after 6 days of 3M™ Veraflo™ Therapy using 3M™ V.A.C. Veraflo Cleanse Choice™ Dressings.



Figure 4. Wound after 9 days of 3M™ Veraflo™ Therapy using 3M™ V.A.C. Veraflo Cleanse Choice™ Dressings.

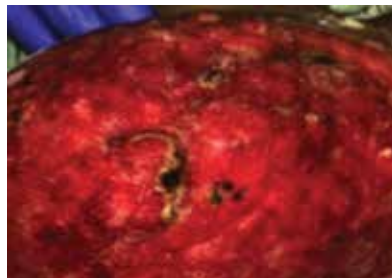

Figure 5. Wound after 1 day of 3M™ V.A.C.® Therapy.

Case study 12

Traumatic wound

Brandon Hill, RN, CWCN, FACCWS; Ochsner Louisiana State University Health Shreveport, Shreveport, LA



Patient

A 26-year-old female was airlifted to our facility after a boating injury in a brackish water lake that resulted in significant avulsion injuries and a Gustilo IIIB fracture (**Figure 1**). During transport, which was delayed due to inclement weather, the patient had a Combat Application Tourniquet applied and received 13 units of packed red blood cells and 8 units of fresh frozen plasma. The patient was a tobacco user with no other notable health issues. Upon arrival, the patient was taken to the operating room (OR) for a transfemoral amputation due to the extent of the injury. The amputation resulted in a soft tissue defect that measured approximately 90 × 45cm², tracking superiorly from above the anterior superior iliac spine to the end of the amputation stump. The wound was initially debrided of devitalized tissue and irrigated, and 3M™ V.A.C.® Therapy was applied at -125mmHg. Early serial wound debridement and irrigation were performed due to delayed onset necrosis and the presumption of wound contamination.

The patient's condition worsened and on Day 5, she was diagnosed with macrophage activation syndrome and started on therapeutic plasma exchange and continuous renal replacement therapy. On Days 6 (**Figure 2**) and 8, the patient was returned to the OR for further debridement and irrigation due to a now aggressive myonecrotic *Aeromonas hydrophila* cutaneous infection. During each trip to the OR, the residual femur had to be revised, resulting in a continuously shortening residual limb and causing concern about potential hip disarticulation and decreased options regarding mobility.

On Day 9, the patient returned for another round of debridement with a possibility of a hip disarticulation; however, upon induction of anesthesia, she coded twice and was returned to the ICU in critical condition. At the bedside, the wound measured 51 × 38 × 4cm³ with undermining (6cm) along the superior border (**Figure 3**), and since debridement was not an option at this time, the decision was made to initiate 3M™ Veraflo™ Therapy. Antibiotics were administered throughout the patient's treatment period, and Veraflo Therapy dressings were changed every 2-3 days. Veraflo Therapy was initially performed using a 3M™ V.A.C. Veraflo Cleanse Choice™ Dressing, instilling 100ml of 0.125% Dakin's Solution with a dwell time of 5 minutes, followed by -150mmHg pressure for 2 hours.

Wound healing progressed (**Figure 4**), and by Day 17, a substantial decrease in devitalized tissue, an increase in vascularity, and significant granulation were noted (**Figure 5**). No further devitalized tissue was evident in the wound and Veraflo Therapy was transitioned to using 3M™ V.A.C. Veraflo™ Dressing, instilling 80ml normal saline with a dwell time of 5 minutes, followed by -125mmHg pressure for 2 hours.

By Day 25, the wound measured approximately 25 × 30cm², and there was significant granulation tissue present and a considerable amount of coverage over the femur fragment (**Figure 6**).

On Day 43, the patient underwent a tangential excision and split-thickness skin graft to the right thigh (**Figure 7**), and the graft was covered with a non-adherent layer and bolstered using 3M™ V.A.C.® Therapy applied at -125mmHg.

By Day 51, a complete take of the graft was noted with no evidence of residual tissue loss. The patient has since gone on to recover fully and took her first steps with the aid of prosthesis on Day 167 (**Figure 8**).

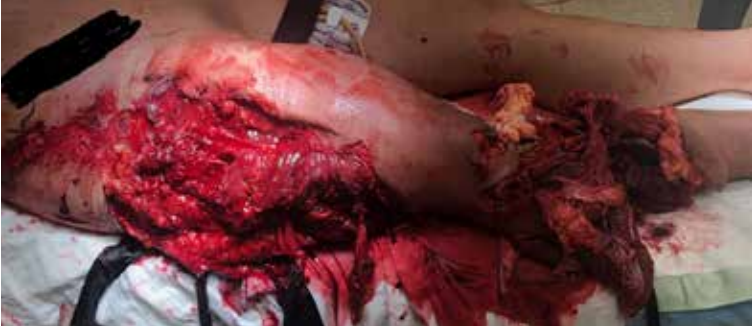

Figure 1. Extensively injured right leg at initial presentation.

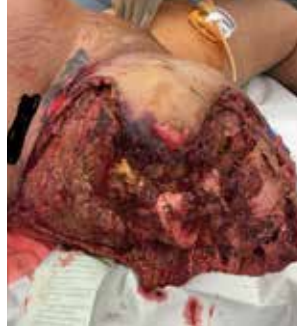

Figure 2. Wound on Day 6.

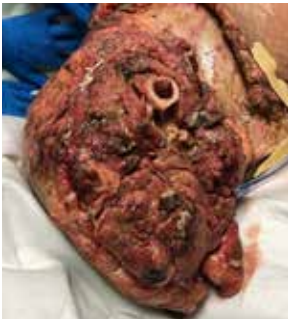

Figure 3. Wound on Day 9 before initiating 3M[™] Veraflo[™] Therapy.

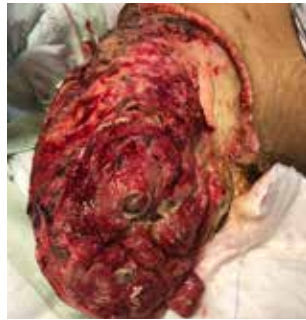

Figure 4. Wound 4 days after initiating 3M[™] Veraflo[™] Therapy.

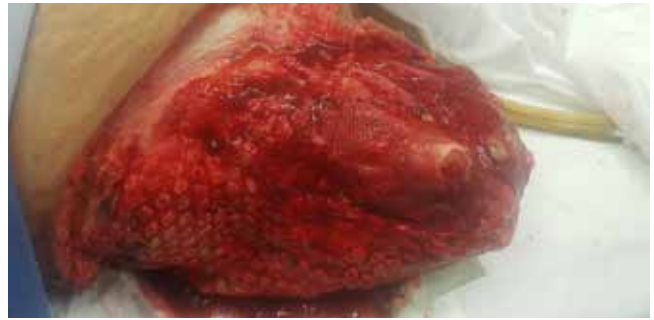

Figure 5. Wound on Day 17, after 8 days of 3M[™] Veraflo[™] Therapy.

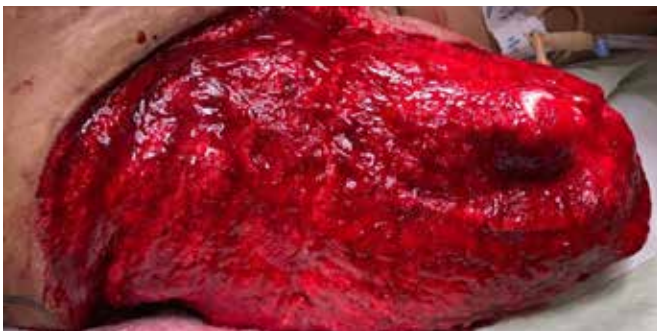

Figure 6. Wound on Day 25.

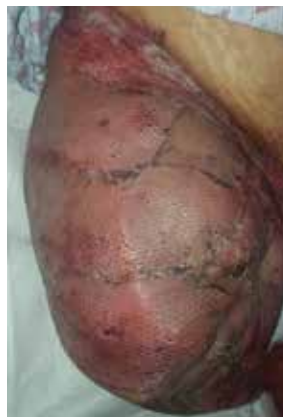

Figure 7. Right thigh on Day 45 – 2 days after split-thickness skin graft.

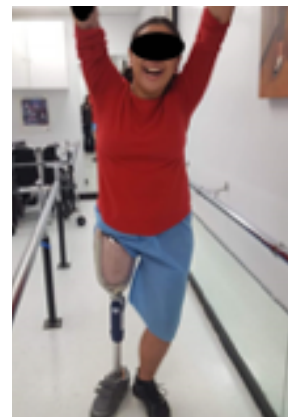

Figure 8. Patient 167 days after initial injury, taking first steps on a new prosthesis.

For more information about 3M™ Veraflo™ Therapy visit [3M.com/Veraflo](https://www.3m.com/Veraflo) or contact your 3M Representative.

These case studies are the results of physicians' clinical experience. As with any case study, the results and outcomes should not be interpreted as a guarantee or warranty of similar results. Individual results may vary depending on the patient's circumstances and condition.

Note: Specific indications, contraindications, warnings, precautions and safety information exist for these products and therapies. Please consult a clinician and product instructions for use prior to application. Rx only.



3M Company
2510 Conway Ave
St. Paul, MN 55144 USA

Phone 1-800-275-4524
(NPWT products)
1-800-228-3957
Web [3M.com/medical](https://www.3m.com/medical)

© 2022 3M. All rights reserved. 3M and the other marks shown are marks and/or registered marks. Unauthorized use prohibited.
US_70-2013-1372-6